

## Integrated Diagnostic Approach for Adult Oligodendroglioma and Oligoastrocytoma

Jens Schittenhelm\*

Institute of Pathology and Neuropathology, University Tuebingen, Tuebingen, Germany

### Abstract

Diffuse gliomas with clear cell morphology are represented in the 2007 WHO classification of brain tumors as oligoastrocytomas and oligodendrogliomas of grades II and III. Although preoperative neuroimaging of these brain tumors are often successful, histopathologic evaluation of neurosurgically removed tumor specimens is still required for a definite diagnosis and subsequent molecular analysis. Such CNS tumors show an extensive variety of histological and cytological appearance making diagnosis in clear cell gliomas somewhat difficult, especially as oligoastrocytomas are often less clearly defined. There is an ongoing debate whether these tumors indeed constitute an entity or whether they represent a mixed bag containing both astrocytomas and oligodendroglioma. Recent advances with molecular data on these tumors have a major impact on neuropathological typing, prognosis and therapy of the patients. This neuro-oncologic review focuses on neuropathological and molecular features of the different types of diffusely infiltrating gliomas. Core features and distinct patterns and variants are also introduced and illustrated. Recent advances in immunohistochemistry and molecular biology have contributed to an improved classification and are discussed. Different methodologies for molecular analysis of 1p/19q codeletion, ATRX loss, MGMT promoter methylation and isocitrate dehydrogenase mutations are presented in detail and their prognostic and predictive implications for therapy are discussed.

### Introduction

Bailey was the first to recognize oligodendroglial tumor as a distinct brain tumor entity in 1926 [1]. Later it became evident that these tumors were not biologically aggressive as astrocytic gliomas of identical histologic grade [2]. Based on data from the Central Brain Tumor Registry of the United States registry (<http://www.cbtrus.org>), oligodendroglial tumors account for approximately 6% of all glial neoplasms and are the third most common glioma of the brain. A male gender predilection is noted in oligodendroglial neoplasms but there is no sufficient explanation for this fact [3]. While almost all tumors occur sporadically, in individuals with Lynch syndrome, a constitutional mismatch repair defect, results in increase of brain tumors among families [4]. The tumor peaks during the 5th and 6th decade and accounts for less than 1% of pediatric central nervous system neoplasms. Publications with higher numbers usually have applied a less stringent diagnostic approach. This probably results from recognition of the significant differences in prognosis between oligodendroglial and astrocytic tumors. It is believed that an increased awareness of favorable histopathologic features by neuropathologists have contributed to these tumors being diagnosed more eagerly. The current World Health Organization recognizes two tumor grades: Oligodendroglioma grade II (ICD-O: 9450/3) and Anaplastic Oligodendroglioma grade III (ICD-O: 9541/3). In addition, some closely related tumors show morphological features of both astrocytoma and oligodendroglioma. These mixed tumors are designed as Oligoastrocytomas (ICD-O: 9382/3) [5,6]. While many of the pathological criteria outlined below, are well defined, the diagnosis of oligodendroglioma remains challenging in atypical cases, especially in mixed gliomas and in tumors that are graded by mitotic activity alone. Furthermore, the initial determination of the tumor as pure oligodendroglioma or oligoastrocytoma may subsequently influence the decision whether the tumor is graded as grade II or grade III neoplasm. Not surprisingly, interobserver variability in such series is great, ranging from 9-80% as seen in a study on 155 tumors that were initially classified as oligoastrocytomas [7].

### Diagnosis

#### Macroscopy

Oligodendrogliomas primarily affect the deep white matter of the cerebral hemisphere and are most common in the frontal lobes [8,9]. Spinal cord oligodendrogliomas are rare, but in children tumors with extensive leptomeningeal spread have been reported [10]. As seen in most diffuse growing glial tumors, oligodendrogliomas have no clear-cut borders. Rather the tumor cells intermingle with normal brain tissue and thus only main tumor components show macroscopically visible changes. The tumors are usually soft and have a grey to pink color and may show focally a mucoid, gelatinous matrix [5]. They may appear hemorrhagic and / or calcified but this is not a specific feature for oligodendrogliomas. Superficial growth can expand the cortical grey matter and elicit eliptogenic potential [9]. The anaplastic forms usually lack a central necrosis typically for glioblastoma but may show focally multiple smaller necroses. Rare disseminating cases may grow as superficial gelatinous masses [11]. There are no macroscopically distinct differences between oligodendrogliomas and oligoastrocytomas. Many patients report a long history of seizures. Generalized seizures are associated with frontomesial locations, while tumors with partial seizures are more often located in orbitofrontal regions [9].

#### Histology

Oligodendroglial tumors are dominated by histologic monotony of

\*Corresponding author: Jens Schittenhelm, Institute of Pathology and Neuropathology, University Tuebingen, Calwerstr. 3, D-72076 Tuebingen, Germany, Tel: +49-7071-2982283; E-mail: [jens.schittenhelm@med.uni-tuebingen.de](mailto:jens.schittenhelm@med.uni-tuebingen.de)

Received August 24, 2015; Accepted September 18, 2015; Published September 26, 2015

Citation: Schittenhelm J (2015) Integrated Diagnostic Approach for Adult Oligodendroglioma and Oligoastrocytoma. Brain Disord Ther 4:187. doi:10.4172/2168-975X.1000187

Copyright: © 2015 Schittenhelm J. This is an open-access article distributed under the terms of the Creative Commons Attribution License, which permits unrestricted use, distribution, and reproduction in any medium, provided the original author and source are credited.

the round to oval shaped tumor cells which are best seen in smears or at low magnification in paraffin-embedded specimens. Nuclei have bland chromatin and prominent nucleoli. Astrocytic tumors usually exhibit more nuclear pleomorphism at this stage [12]. The very characteristic perinuclear halo ("fried egg") – a fixation artifact resulting from autolytic water absorption – is absent in frozen sections or specimens that have been quickly processed resulting from a short fixation time. Delicate branching of capillaries and tumor calcifications that also may affect tumor vessels are more frequent in oligodendrogliomas than in other CNS tumors [13]. Some tumors may exhibit nodules of higher cellularity and slightly increased mitotic activity. Such tumors are usually borderline cases between grade II and grade III. Prominent microcysts may be apparent in otherwise compact tumor architecture. Divergent growth pattern include columnar arrangement of tumor cells, the so-called spongioblastoma pattern [12], marked desmoplasia [14] signet-ring cell morphology [15] or perineuronal satellitosis of the tumor cells invading grey matter. These patterns have no impact on the clinical course or tumor grading. So called "secondary structures" of Schrerer, where tumor cells may concentrate along subpial structures are occasionally present. Rare cases of oligodendrogliomas may show focally neuropil islands, that have to be distinguished from neurocytomas. Another important differential diagnosis is the dysembryoplastic neuroepithelial tumor that are characterized by the presence of floating neurons. Oligodendrogliomas usually lack the multinodular appearance and the so called "glioneuronal element" of these tumors and are more deep-seated compared to the usually cortical located DNT. However, as some authors propose a non-specific form of DNT that is diagnosed in context of clinical and radiological presentation [16], molecular analysis might be required in some instances to discriminate these two entities safely. Cerebellar pilocytic astrocytomas may focally exhibit cluster of cells that resemble oligodendrocytes. Unless biopsies are very small, the other components of the tumor are usually visible and exclude oligodendroglioma. Single scattered reactive astrocytes among otherwise oligodendroglial tumor cells should not prompt the diagnosis of an oligoastrocytoma. Some tumors show focal areas with eccentric nuclei and a fibrillar, almost glassy cytoplasm with short to none cell processes, the so called minigemistocytes or gliofibrillary oligodendrocytes. Again, these tumors should not be classified as mixed gliomas. In the tumor edges several astrocytic cells might be present but unless clearly neoplastic in nature their presence does not warrant the diagnosis of mixed oligoastrocytoma. Mixed tumors may come in two flavors: The more readily to diagnose, but less often seen biphasic ("compact") oligoastrocytoma with two distinct neoplastic tumor components and the more intermingled ("diffuse") variant, in which sometimes the astrocytic cells are not always neoplastic in nature [17]. There is no agreement to upon which minimum of astrocytic appearing tumor cells are required to diagnose a mixed tumor [18]. Anaplastic oligodendrogliomas show increased nuclear pleomorphism and increased mitotic activity compared to grade II lesions while often retaining the monotonous architecture of more evenly distributed tumor cells. As the 2007 WHO classification only vaguely mentions "significant mitotic activity" as a delineator, many authors prefer a mitotic cutoff of 6 mitoses per 10 high power fields to discriminate between grade II and grade III lesions [19]. Vascular proliferations or extended vascular hyperplasia are typical for anaplastic oligodendroglioma grade III. In addition smaller areas of necrosis may be present but not typically in the pseudopalisading forms of glioblastoma. The 2007 WHO classification however explicitly allows presence of pseudopalisading necroses in anaplastic oligodendrogliomas and thus weakened a sufficient discrimination to the recently included glioblastomas with oligodendroglial component. Even more difficult is

the discrimination of anaplastic oligoastrocytoma from glioblastoma. Recent data confirmed that presence of necrosis is an unfavorable predictor in mixed gliomas - but not in pure oligodendrogliomas [20]. Based on this data, stratification of tumors as glioblastoma with oligodendroglial component is based mainly on presence of necrosis. As a rule of thumb, we expect in tumors that are not unequivocally classified as pure oligodendrogliomas, that the usually smaller necrosis should be limited to the oligodendroglial component before considering a mixed anaplastic oligoastrocytoma / small cell glioblastoma and strive to resolve the issue by additional immunohistochemistry and molecular analysis.

### Immunohistochemistry

A specific marker for oligodendroglial tumors is still lacking. Therefore it is advisable to use a panel of different antibodies for which expression patterns in these neoplasms has been extensively studied and to combine the information gained from these stains with morphology of the tumor cells. In our institution we stain routinely gliomas for GFAP, MAP2, WT1, ATRX and IDH1(R132H). Expression of the glial fibrillary acidic protein GFAP is usually absent or only weakly seen in tumor cytoplasm of oligodendroglia, however in our daily practice sometime there is ample overlapping of the GFAP-positive fibrillary neuropil background with individual tumor cells [9]. In addition minigemistocytes and interdispersed astrocytes are usually positive for GFAP. Olig-2 was initially considered specific for neural progenitors and developing oligodendrocytes and thus proposed as a oligodendroglioma-specific marker. While nuclear Olig2 immunoreactivity is slightly stronger in oligodendrogliomas, it is also constantly seen in other glial neoplasms such as astrocytomas and mixed glial-neuronal tumors [21]. The marker however remains helpful as it is absent in clear cell ependymomas and neurocytomas [22]. The microtubule-associated protein MAP2 is constantly expressed in oligodendrogliomas, but also found in up to 92% of astrocytomas and glioblastomas [23]. A perinuclear "capped" expression pattern is more typical for oligodendroglial cells, while in astrocytomas the elongated cell processes are also immunoreactive for MAP2 [9]. Entrapped neurons and primitive neuroepithelial tumor cells are however often strongly immunoreactive for MAP2 too. The Wilms-tumor protein WT1 is strongly expressed in the cytoplasm 83-92% of anaplastic astrocytomas and glioblastomas but in oligodendrogliomas, it is usually restricted to single WT1- positive tumour cells or completely absent [24]. Similarly to GFAP, WT1 also strongly stains minigemistocytes. Another recently introduced marker is the neurite outgrowth factor Nogo-A. In the prime publication, Nogo-A was found in 71% oligodendrogliomas and 24% glioblastomas but absent in astrocytomas [25]. However subsequent studies confirming these results are lacking so far. Alpha internexin is found in approximately half of oligodendrogliomas and was introduced as associated marker for the molecular relevant 1p/19q codeletion [26]. However because of higher specificity, it has been replaced recently by alpha thalassemia/mental retardation syndrome X-linked protein (ATRX) [27,28]. Nuclear ATRX immunoreactivity is retained in most oligodendroglioma cases and strongly associated with 1p/19q codeletion in oligoastrocytomas and oligodendrogliomas [29]. Unlike diffuse astrocytomas, most oligodendrogliomas show only limited p53 immunoreactivity [10]. Recently a mutation specific IDH1(R132H) antibody has been developed. Positive IDH1(R132H) immunoreactivity is so frequent in oligodendroglial tumors (up to 91% in grade II and 94% in grade III lesions) that this marker is very useful to discriminate oligodendrogliomas from other brain tumors with clear cell morphology [30]. The few remaining negative cases should be sequenced for rare IDH1/IDH2 mutations. IDH mutations

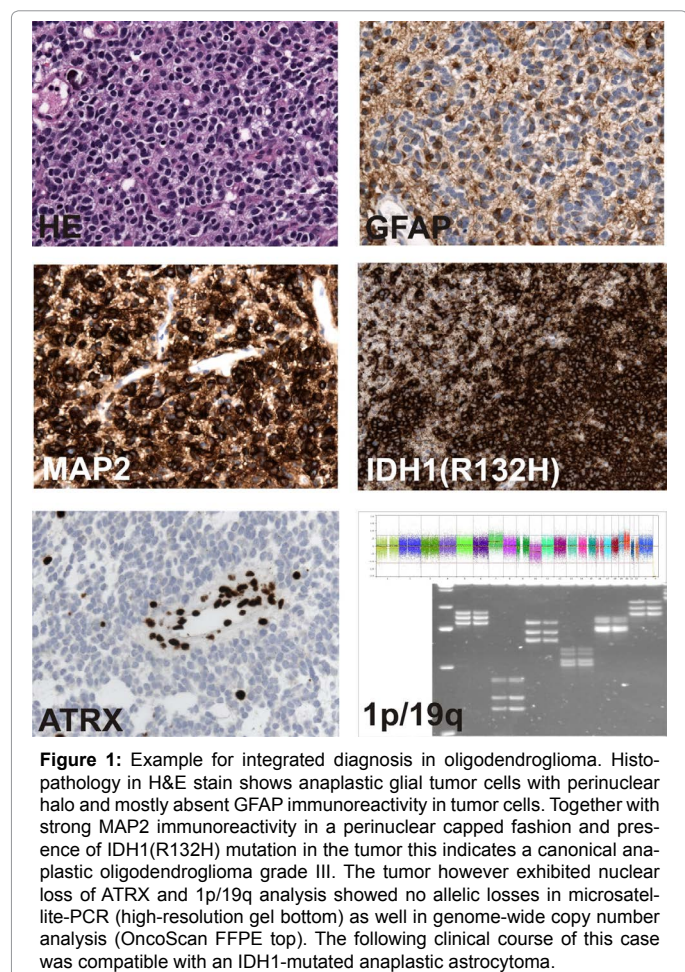
are less common in pediatric oligodendroglial tumors [31]. IDH1/2 mutation status however is not useful to separate oligodendrogliomas from mixed gliomas or pure astrocytomas. Synaptophysin and CD56 immunoreactivity may be observed in some oligodendrogliomas but in association with IDH1 immunoreactivity it is possible to exclude neurocytoma or neuroendocrine tumor metastatic to the brain [32]. Electron microscopy is not used in regular routine practice as combined data from histology, immunohistochemistry and molecular pathology is usually sufficient enough to diagnose an oligodendroglioma (Figure 1).

### Molecular data

Because of their prognostic and predictive potential, molecular data of brain tumors have become an integral part of modern neuro-oncology. Prognostic markers inform about likely disease outcome independent of the treatment received, while predictive markers provide information about expected outcomes with the application of specific interventions which is very important in oligodendrogliomas. Until twenty years ago diagnosis and grading of oligodendroglial tumor has been based on histopathological morphology. Since the discovery of recurrent codeletions of chromosome regions 1p36/19q13 in oligodendrogliomas in 1994 [33] it became evident that certain molecular aberrations carry important prognostic and predictive information on particular therapy response. Loss of heterozygosity in 1p and 19q is not restricted to oligodendroglial tumors but strongly associated with it and therefore useful as a diagnostic marker [6]. The codeletion is found in 70-80% of oligodendrogliomas grade II, 40-

50% of oligoastrocytomas, in 10-20% of diffuse astrocytomas grade II WHO and in 2-8% of glioblastomas [34,35]. The number of codeletions may be even higher, when strict diagnostic criteria for the diagnosis of oligodendrogliomas are applied as outlined above. The 1p/19q loss results from a non-balanced translocation  $t(1:19)(q10:p10)$  that is also observed in tumor recurrences [36]. This molecular signature is so robust that it is seen even in cases with increased intratumoral heterogeneity [37]. The clinical course of 1p/19q codeleted tumors is significantly better than for nondeleted tumors of similar grade [38,39]. This results from a so called "proneural" expression profile of the genomic landscape with less overall mutation rate [6]. In addition in oligodendrogliomas, nearly all codeleted tumors also show either additional isocitrate dehydrogenase (IDH1 or IDH2) mutations [40]. Not surprisingly journal reviewers often require 1p/19q deletions in oligodendrogliomas for sample homogeneity. There is an inverse correlation with ATRX loss / p53 mutation and codeletion of chromosomal arms 1p and 19q in oligodendrogliomas. This implicates that non-codeleted oligodendrogliomas and oligoastrocytomas have a clinical and genetic profile similar to astrocytoma and thus questions the existence of oligoastrocytoma as a distinct entity [41,42]. The 1p/19q codeletion is not only diagnostic and prognostic but also has therapeutic relevancy. Codeleted tumors are more responsive to a combined Procarbazine-CCNU-Vincristine (PCV) therapy regimen [43,44]. This benefit has been corroborated by independent long-term studies on IDH1/2 mutated and 1p/19q codeleted tumors [45,46]. IDH1/2 itself has a prognostic role, as oligodendroglial tumors with IDH1/2 mutation but without 1p/19q deletion still have a better clinical course than double-negative oligodendrogliomas without IDH1/2 and 1p/19q codeletion [47] (which are most likely glioblastomas with an oligodendroglial component). A loss of heterozygosity is usually assessed through use of microsatellite marker PCR on high-resolution gels. This method requires corresponding blood samples to determine allele status [11]. Therefore use of fluorescent in situ hybridisation is preferred by some laboratories but carries the risk of misdiagnosing cases with only partial loss. This risk can be covered by PCR that contains several loci along the chromosomal arms or by use of genome-wide based array methods for copy-number alterations [15,16]. With the introduction of a mutation-specific antibody the determination of the IDH1/IDH2 mutation status has become easier. The IDH1 (R132H) mutation is detected by immunohistochemistry in approximately 75%-90% of the cases [5]. The remaining R132H-negative cases are then usually sequenced for non-canonical IDH1 and IDH2 mutations [36].

Other far less frequently employed biomarkers include the epidermal growth factor receptor (EGFR). Its amplification is mutually exclusive with the 1p/19q codeletion and in cases with amplification the diagnosis of (small cell) glioblastoma instead of anaplastic oligodendroglioma should be considered [18]. The determination of telomerase reverse transcriptase (TERT) C228T and C250T mutation is useful in IDH1/2 wild-type tumors to detect potential high-grade lesions [6] but does not help in separating oligodendroglioma from glioblastoma as such mutations are present in both tumor entities [23]. Additional mutations found in 1p/19q codeleted tumors are alterations in the putative tumor suppressors far-upstream binding protein-1 (FUBP1, 15-30% of the tumors) and Drosophila capicua homolog (CIC, 50-70%) which are located on 19q and 1p respectively [3]. The presence of mutation results in a loss of FUBP1 expression and can be determined by immunohistochemistry [2]. CIC mutated, 1p/19q codeleted tumors seem to have a prognostic unfavorable course [14,48]. Genetic alterations are surprisingly similar between grade II and grade



**Figure 1:** Example for integrated diagnosis in oligodendroglioma. Histopathology in H&E stain shows anaplastic glial tumor cells with perinuclear halo and mostly absent GFAP immunoreactivity in tumor cells. Together with strong MAP2 immunoreactivity in a perinuclear capped fashion and presence of IDH1(R132H) mutation in the tumor this indicates a canonical anaplastic oligodendroglioma grade III. The tumor however exhibited nuclear loss of ATRX and 1p/19q analysis showed no allelic losses in microsatellite-PCR (high-resolution gel bottom) as well in genome-wide copy number analysis (OncoScan FFPE top). The following clinical course of this case was compatible with an IDH1-mutated anaplastic astrocytoma.

III oligodendrogliomas. One potential candidate driver for anaplastic progression is the oligodendrocyte-related transcription factor TCF12 [27].

Another marker employed routinely in gliomas is the determination of the O6-methylguanine-DNA-methyltransferase (MGMT) promoter status because of its prognostic and predictive role in glioblastoma [16]. A methylated phenotype is associated with a single nucleotide polymorphism within the MGMT gene and results in improved chemo-sensitivity of the tumors [33]. In oligodendroglial tumors there is a strong association between MGMT promoter methylation and 1p/19q codeletion. However while MGMT alone is useful as a prognostic marker in oligodendrogliomas, it is not useful to predict outcome of adjuvant treatment in oligodendrogliomas [45]. Almost all co-deleted oligodendrogliomas show a methylated MGMT promoter as part of a general hypermethylated genotype, the so called “G-CIMP” profile [31]. While oligodendrogliomas in children are morphologically similar to their adult counterparts, they lack the same genetic background [38]. One notable exception is the diffusely growing oligodendroglia-like neoplasms with markedly leptomeningeal spread. These tumors may carry the classical 1p/19q codeletion pattern seen in adult oligodendrogliomas in association to KIAA1549-BRAF fusion transcripts typically encountered in pilocytic astrocytoma [37,39].

## Conclusion and Clinical Perspective

Because of clinical relevance the molecular stratification of oligodendrogliomas is of utmost importance. The combination of IDH mutation and 1p/19q co-deletion is now considered the molecular signature of oligodendrogliomas [49,50] and assessment of the 1p/19q codeletion status guides the neuro-oncologist for chemotherapy responsiveness as seen in two large studies (RTOG 9402 and EORTC 26951) [51,52]. Not surprisingly the USA National Comprehensive Cancer Network treatment guidelines therefore recommends 1p/19q codeletion as the only molecular biomarker to be used for therapeutic stratification in anaplastic oligodendroglioma and oligoastrocytomas [53]. As there is no sufficient delineator between grade II and grade III tumors, the histopathological analysis remains the first crucial step and identification of a clear-cell (“oligodendroglial”) phenotype by the neuropathologist is essential for subsequent targeted and cost-efficient molecular analysis. Based on the obtained data, prototypical oligodendrogliomas (defined as IDH1/2 mutated, 1p/19q codeleted, MGMT methylated (no ATRX loss and TERT mutated)) should be included in future studies when speaking strictly of oligodendrogliomas. Morphologically similar tumors that do not meet these requirements may show a divergent, more unfavorable clinical outcome and thus may need to be treated accordingly. The proper designation of these tumors is currently debated and most likely included in the upcoming WHO classification of brain tumors. The integrated (layered) diagnostic by combining histopathology, immunohistochemistry and molecular data into a layered scheme will obviously become the future gold standard in neuropathology and neurooncology practice [47].

## Acknowledgement

The author acknowledges support by Deutsche Forschungsgemeinschaft and Open Access Publishing Fund of University of Tübingen.

## References

1. Bailey P, Cushing H (1926) A classification of the tumors of the glioma group on a histogenetic basis with a correlated study of prognosis. Pa: Lippincott, Philadelphia, USA.
2. Earnest F III, Kernohan JW, Craig WM (1950) Oligodendrogliomas: a review of 200 cases. Arch Neurol Psychiatry 63: 964–976.
3. Shaw EG, Scheithauer BW, O’Fallon JR, Tazelaar HD, Davis DH (1992) Oligodendrogliomas: the Mayo Clinic experience. J Neurosurg 76: 428-434.
4. Therkildsen C, Ladelund S, Rambech E, Persson A, Petersen A, et al. (2015) Glioblastomas, astrocytomas and oligodendrogliomas linked to Lynch syndrome. Eur J Neurol 22: 717-724.
5. Reifenberger G, Kros JM, Burger PC, Louis DN, Collins VP (2000) Anaplastic oligoastrocytoma. In: Kleihues P, Cavenee WK, eds. Pathology and genetics of tumours of the nervous system. IARC Press, Lyon, France, 68–69.
6. Riemenschneider MJ, Jeuken JW, Wesseling P, Reifenberger G (2010) Molecular diagnostics of gliomas: state of the art. Acta Neuropathol 120: 567-584.
7. Fuller CE, Schmidt RE, Roth KA, Burger PC, Scheithauer BW, et al. (2003) Clinical utility of fluorescence in situ hybridization (FISH) in morphologically ambiguous gliomas with hybrid oligodendroglial/astrocytic features. J Neuropathol Exp Neurol 62: 1118-1128.
8. Koeller KK, Rushing EJ (2005) From the archives of the AFIP: Oligodendroglioma and its variants: radiologic-pathologic correlation. Radiographics 25: 1669-1688.
9. Schittenhelm J (2011) Diagnostic Evaluation of Diffuse Gliomas, Advances in the Biology, Imaging and Therapies for Glioblastoma, Chen C (Ed), InTech, Rijeka, Croatia, EU.
10. Rodriguez FJ, Tihan T, Lin D, McDonald W, Nigro J, et al. (2014) Clinicopathologic features of pediatric oligodendrogliomas: a series of 50 patients. Am J Surg Pathol 38: 1058-1070.
11. Mittelbronn M, Wolff M, Bültmann E, Nägele T, Capper D, et al. (2005) Disseminating anaplastic brainstem oligodendroglioma associated with allelic loss in the tumor suppressor candidate region D19S246 of chromosome 19 mimicking an inflammatory central nervous system disease in a 9-year-old boy. Hum Pathol 36: 854-857.
12. Giannini C, Burger PC, Berkey BA, Cairncross JG, Jenkins RB, et al. (2008) Anaplastic oligodendroglial tumors: refining the correlation among histopathology, 1p 19q deletion and clinical outcome in Intergroup Radiation Therapy Oncology Group Trial 9402. Brain Pathol 18: 360-369.
13. Wesseling P, van den Bent M, Perry A (2015) Oligodendroglioma: pathology, molecular mechanisms and markers. Acta Neuropathol 129: 809-827.
14. Jentoft M, Giannini C, Rossi S, Mota R, Jenkins RB, et al. (2011) Oligodendroglial tumors with marked desmoplasia: clinicopathologic and molecular features of 7 cases. Am J Surg Pathol 35: 845-852.
15. Kros JM, van den Brink WA, van Loon-van Luyt JJ, Stefanko SZ (1997) Signet-ring cell oligodendroglioma—report of two cases and discussion of the differential diagnosis. Acta Neuropathol 93: 638-643.
16. Dumas-Duport C, Varlet P, Bacha S, Beuvon F, Cervera-Pierot P, et al. (1999) Dysembryoplastic neuroepithelial tumors: nonspecific histological forms – a study of 40 cases. J Neurooncol 41: 267-280.
17. Sahm F, Reuss D, Koelsche C, Capper D, Schittenhelm J, et al. (2014) Farewell to oligoastrocytoma: in situ molecular genetics favor classification as either oligodendroglioma or astrocytoma. Acta Neuropathol 128: 551-559.
18. Kros JM, Huizer K, Hernández-Lain A, Marucci G, Michotte A, et al. (2015). Evidence-Based Diagnostic Algorithm for Glioma: Analysis of the Results of Pathology Panel Review and Molecular Parameters of EORTC 26951 and 26882 Trials. J Clin Oncol 33: 1943-1950.
19. Giannini C, Scheithauer BW, Weaver AL, Burger PC, Kros JM, et al. (2001) Oligodendrogliomas: reproducibility and prognostic value of histologic diagnosis and grading. J Neuropathol Exp Neurol 60: 248-262.
20. Smith SF, Simpson JM, Brewer JA, Sekhon LH, Biggs MT, et al. (2006) The presence of necrosis and/or microvascular proliferation does not influence survival of patients with anaplastic oligodendroglial tumours: review of 98 patients. J Neuro Oncol 80: 75-82.
21. Ligon KL, Alberta JA, Kho AT, Weiss J, Kwaan MR, et al. (2004) The oligodendroglial lineage marker OLIG2 is universally expressed in diffuse gliomas. J Neuropathol Exp Neurol 63: 499-509.
22. Preusser M, Budka H, Rössler K, Hainfellner JA (2007) OLIG2 is a useful immunohistochemical marker in differential diagnosis of clear cell primary CNS neoplasms. Histopathology 50: 365-370.
23. Blümcke I, Müller S, Buslei R, Riederer BM, Wiestler OD (2004) Microtubule-associated protein-2 immunoreactivity: a useful tool in the differential diagnosis of low-grade neuroepithelial tumors. Acta Neuropathol 108: 89-96.

24. Schittenhelm J, Beschoner R, Simon P, Tabatabai G, Herrmann C, et al. (2009) Diagnostic value of WT1 in neuroepithelial tumours. *Neuropathol Appl Neurobiol* 35: 69-81.
25. Kuhlmann T, Gutenberger A, Schulten HJ, Paulus W, Rohde V, et al. (2008) Nogo-a expression in glial CNS tumors: a tool to differentiate between oligodendrogliomas and other gliomas? *Am J Surg Pathol* 32: 1444-1453.
26. Ducray F, Mokhtari K, Crinière E, Idhahbi A, Marie Y, et al. (2011) Diagnostic and prognostic value of alpha internexin expression in a series of 409 gliomas. *Eur J Cancer* 47: 802-808.
27. Reuss DE, Sahm F, Schrimpf D, Wiestler B, Capper D, et al. (2015) ATRX and IDH1-R132H immunohistochemistry with subsequent copy number analysis and IDH sequencing as a basis for an "integrated" diagnostic approach for adult astrocytoma, oligodendroglioma and glioblastoma. *Acta Neuropathol* 129: 133-146.
28. Wiestler B, Capper D, Holland-Letz T, Korshunov A, von Deimling A, et al. (2013) ATRX loss refines the classification of anaplastic gliomas and identifies a subgroup of IDH mutant astrocytic tumors with better prognosis. *Acta Neuropathol* 126: 443-451.
29. Hewer E, Vajtai I, Dettmer MS, Berezowska S, Vassella E (2015) Combined ATRX/IDH immunohistochemistry predicts genotype of oligoastrocytomas. *Histopathology* .
30. Capper D, Reuss D, Schittenhelm J, Hartmann C, Bremer J, et al. (2011) Mutation-specific IDH1 antibody differentiates oligodendrogliomas and oligoastrocytomas from other brain tumors with oligodendroglioma-like morphology. *Acta Neuropathol* 121: 241-252.
31. Gierke M, Sperveslage J, Schwab D, Beschoner R, Ebinger M, et al. (2015) Analysis of IDH1-R132 mutation, BRAF V600 mutation and KIAA1549-BRAF fusion transcript status in central nervous system tumors supports pediatric tumor classification. *J Cancer Res Clin Oncol* .
32. Hirose T, Nobusawa S, Nakazato Y, Sasaki A (2013) A case of oligodendroglioma with prominent neuronal differentiation. *Hum Pathol* 44: 2353-2359.
33. Reifenberger J, Reifenberger G, Liu L, James CD, Wechsler W, et al. (1994) Molecular genetic analysis of oligodendroglial tumors shows preferential allelic deletions on 19q and 1p. *Am J Pathol* 145: 1175-1190.
34. Cancer Genome Atlas Research Network (2015) Comprehensive, Integrative Genomic Analysis of Diffuse Lower-Grade Gliomas. *N Engl J Med* 372: 2481-2498.
35. Wiestler B, Capper D, Sill M, Jones DT, Hovestadt V, et al. (2014) Integrated DNA methylation and copy-number profiling identify three clinically and biologically relevant groups of anaplastic glioma. *Acta Neuropathol* 128: 561-571.
36. Griffin CA, Burger P, Morsberger L, Yonescu R, Swierczynski S, et al. (2006) Identification of der(1;19)(q10;p10) in five oligodendrogliomas suggests mechanism of concurrent 1p and 19q loss. *J Neuropathol Exp Neurol* 65: 988-994.
37. Lass U, Nümann A, von Eckardstein K, Kiwit J, Stockhammer F, et al. (2012). Clonal analysis in recurrent astrocytic, oligoastrocytic and oligodendroglial tumors implicates IDH1- mutation as common tumor initiating event. *PLoS One*. 7: e41298.
38. Jenkins RB, Blair H, Ballman KV, Giannini C, Arusell RM, et al. (2006) A t(1;19)(q10;p10) mediates the combined deletions of 1p and 19q and predicts a better prognosis of patients with oligodendroglioma. *Cancer Res* 66: 9852-9861.
39. McLendon RE, Herndon JE 2nd, West B, Reardon D, Wiltshire R, et al. (2005) Survival analysis of presumptive prognostic markers among oligodendrogliomas. *Cancer* 104: 1693-1699.
40. Kim YH, Nobusawa S, Mittelbronn M, Paulus W, Brokinkel B, et al. (2010) Molecular classification of low-grade diffuse gliomas. *Am J Pathol* 177: 2708-2714.
41. Cairncross JG, Ueki K, Zlatescu MC, Lisle DK, Finkelstein DM, et al. (1998) Specific genetic predictors of chemotherapeutic response and survival in patients with anaplastic oligodendrogliomas. *J Natl Cancer Inst* 90: 1473-1479.
42. Wick W, Hartmann C, Engel C, Stoffels M, Felsberg J, et al. (2009) NOA-04 randomized phase III trial of sequential radiochemotherapy of anaplastic glioma with procarbazine, lomustine, and vincristine or temozolomide. *J Clin Oncol* 27: 5874-5880.
43. Cairncross G, Wang M, Shaw E, Jenkins R, Brachman D, et al. (2013) Phase III trial of chemoradiotherapy for anaplastic oligodendroglioma: long-term results of RTOG 9402. *J Clin Oncol* 31: 337-343.
44. Cairncross JG, Wang M, Jenkins RB, Shaw EG, Giannini C, et al. (2014) Benefit from procarbazine, lomustine, and vincristine in oligodendroglial tumors is associated with mutation of IDH. *J Clin Oncol* 32: 783-790.
45. Weller M, Weber RG, Willscher E, Riehm V, Hentschel B, et al. (2015) Molecular classification of diffuse cerebral WHO grade II/III gliomas using genome- and transcriptome-wide profiling improves stratification of prognostically distinct patient groups. *Acta Neuropathol* 129: 679-693.
46. Horbinski C, Hobbs J, Ciepły K, Dacic S, Hamilton RL (2011) EGFR expression stratifies oligodendroglioma behavior. *Am J Pathol* 179: 1638-1644.
47. Koelsche C, Sahm F, Capper D, Reuss D, Sturm D, et al. (2013) Distribution of TERT promoter mutations in pediatric and adult tumors of the nervous system. *Acta Neuropathol* 126: 907-915.
48. Bettgowda C, Agrawal N, Jiao Y, Sausen M, Wood LD, et al. (2011) Mutations in CIC and FUBP1 contribute to human oligodendroglioma. *Science* 333: 1453-1455.
49. Baumgarten P, Harter PN, Tönjes M, Capper D, Blank AE, et al. (2014) Loss of FUBP1 expression in gliomas predicts FUBP1 mutation and is associated with oligodendroglial differentiation, IDH1 mutation and 1p/19q loss of heterozygosity. *Neuropathol Appl Neurobiol* 40: 205-216.
50. Gleize V, Alentorn A, Connen de Kéris L, Labussière M, et al. (2015) CIC inactivating mutations identify aggressive subset of 1p19q codeleted gliomas. *Ann Neurol* 78: 355-374.
51. Labreche K, Simeonova I, Kamoun A, Gleize V, Chubb D, et al. (2015) TCF12 is mutated in anaplastic oligodendroglioma. *Nat Commun* 6: 7207.
52. Hegi ME, Diserens AC, Gorlia T, Hamou MF, de Tribolet N, et al. (2005) MGMT gene silencing and benefit from temozolomide in glioblastoma. *N Engl J Med* 352: 997-1003.
53. Rapkins RW, Wang F, Nguyen HN, Cloughesy TF, Lai A, et al. (2015) The MGMT promoter SNP rs16906252 is a risk factor for MGMT methylation in glioblastoma and is predictive of response to temozolomide. *Neuro Oncol* .