

Infection after Penetrating Superficial Femoral Artery Trauma Caused by falling on Metal Fence

Alessandro de Troia*, Matteo Azzarone, Tiziano Tecchio and Pierfranco Salcuni

Unit of Vascular Surgery, Department of Surgical Sciences University Hospital of Parma, Via Gramsci, 14 – 43126 Parma, Italia, Italy

An 81-year-old man was admitted for penetrating trauma with injury to the superficial femoral vein and artery. He also presented an associated fracture of the medial condyle of the femur and the distal radio, caused by falling on a metal fence post (Figure 1). The patient had a history of hypertension and Parkinson's syndrome. Emergency surgery was necessary to remove the metal bar as soon as possible; subsequent reconstruction of the Superficial Femoral Artery (SFA) was accomplished by interposition of a saphenous vein graft (Figure 2), ligation of the superficial femoral vein and fasciotomies of the leg.

At the patient's 10th day's stay in hospital the onset of fever and leukocytosis required the performance of a CTA (Computed Tomographic Angiography) (Figure 3), which showed the presence of an abscess in the surgical site. After a surgical drainage of the abscess, advanced silver medication was used to treat thigh wound; in the meantime the infection was treated with systemic antibiotics according to antibiogram. Bacterial culture test was positive for *Pseudomonas aeruginosa* susceptible to Ceftazimide and Levofloxacin, so the elderly patient underwent intravenous antibiotics (6 g daily dose of Ceftazimide and 750 mg daily dose of Levofloxacin) for 19 days. During infection's monitoring procedure, however, culture specimen revealed that thigh wound was positive for *Escherichia Coli*, *Corynebacterium Jeikeium* and *Enterococcus faecium*, susceptible to tigecycline and teicoplanin; he was thus given further intravenous antibiotics (1 g daily dose of Tigecycline and 850 mg daily dose of Teicoplanin) for 17 days. On his 46th day's stay the patient was discharged (Figure 4) and prescribed antiplatelet therapy. After a 26 month follow up he was finally symptom free; duplex scan ultrasonography revealed venous graft patency.

Trauma has emerged as a major public health problem in developing as well as developed countries, and vascular trauma is an important component of this problem. Penetrating injury is considered the most frequent, 82-94% in peripheral arteries injuries [1-3]; studies show that 73% limbs are salvaged while 27% sustain either primary or secondary amputation [4]. Femoral vessel injuries are among the most common vascular injuries treated in urban trauma centers, and may amount to 70% of all peripheral vascular injuries in some cases [5]. In this highly selected trauma population an incidence of about 10% of devastating outcomes has been demonstrated, with a mortality rate of 2.8% and an amputation rate of 6.5% [6]. Primary repair by direct sutures is used

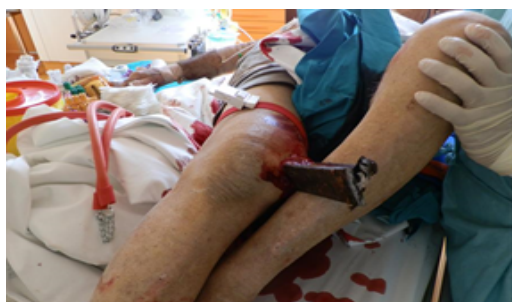

Figure 1: Penetrating trauma of thigh.

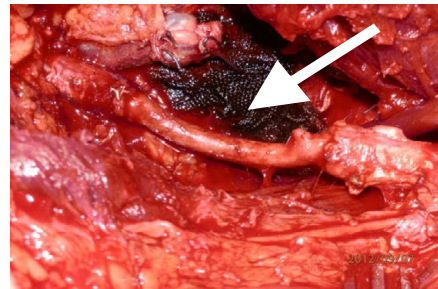


Figure 2: Saphenous Vein Graft (arrow).

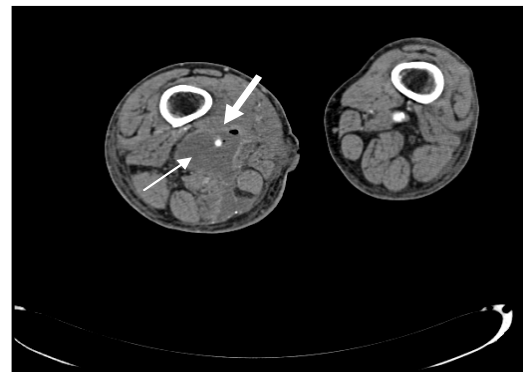


Figure 3: Computed Tomographic Angiography: abscess (thin arrow), venous graft (thick arrow).

for less destructive injuries [7]; reverse saphenous vein grafts have traditionally been preferred as conduits by reason of their long-term patency and alleged greater resistance to infection [7]; venous ligation is indicated whenever there is a destructive injury to the vein or as long as repairs may lead to a proximal thrombosis because of the vein narrow dimensions [5-7].

Infection is another considerable factor, increasing amputation rate even after a successful vascular surgery intervention [3]. Therefore, wound irrigation, vigorous tissue debridement as well as

*Corresponding author: Alessandro dott. de Troia, Unit of Vascular Surgery, Department of Surgical Sciences University Hospital of Parma, Via Gramsci, 14 – 43126 Parma – Italia, Italy, Tel: +393385894543; E-mail: Alessandro.detroia@unipr.it

Received May 31, 2015; Accepted July 02, 2015; Published July 07, 2015

Citation: de Troia A, Azzarone M, Tecchio T, Salcuni P (2015) Infection after Penetrating Superficial Femoral Artery Trauma Caused by falling on Metal Fence. J Vasc Med Surg S1: 008. doi:10.4172/2329-6925.S1-008

Copyright: © 2015 de Troia A, et al. This is an open-access article distributed under the terms of the Creative Commons Attribution License, which permits unrestricted use, distribution, and reproduction in any medium, provided the original author and source are credited.

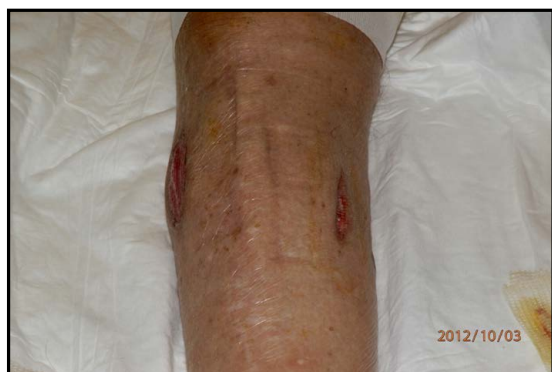

Figure 4: Fasciotomy outcome.

appropriate antibiotic therapy are very important before and after the revascularization procedure. Currently [8] guidelines recommend penicillin or cefazolin (or clindamycin for the β -lactam allergic patient) for prophylaxis for a period of up to 5 days (BII level of evidence). Based upon consensus opinion (BIII level of evidence), we recommend vancomycin, daptomycin or linezolid for empiric Gram-positive coverage. Ceftazidime, cefepime or meropenem are recommended for Gram-negative infections, especially in settings of prolonged hospitalizations, with a duration of treatment for 7–14 days (BIII)

Asensio, et al. [5] have pointed out that wound sepsis generally occurs in 13% of cases of lower extremity vascular trauma; they have demonstrated that the presence of coagulopathy or hypothermia in the operating room together with an associated bony fracture are highly significant factors for the development of wound infection. After extremity trauma, approximately 1% of patients require a fasciotomy [9]; the occurrence of fasciotomy rate is extremely changeable according to injury mechanism and type, reaching 42% in patients who have sustained a combined arterial and venous injury [5,7,9,10].

Penetrating injury can be considered a very frequent contributing

factor in limb salvage or loss.

The best treatment in cases of lower extremity arterial injuries includes a prompt diagnosis by physical examination, early restoration of blood flow, interposition grafts with autogenous saphenous vein, free use of fasciotomies and timely appropriate antibiotic therapy.

References

1. Muhammad Y, Khoso S, Gondal KM, Alam S (2014) Contributing factors in limb salvage after arterial reconstruction in peripheral arterial injuries. *Pak J Surg* 30: 74-77
2. Aduful HK, Hodasi WM (2007) Peripheral Vascular Injuries and Their Management in Accra. *Ghana Medical Journal* 41: 186-189.
3. Rana SH, Farani TM, Jamal Y, Afzal M (2008) Peripheral vascular injuries: epidemiology and management. *Professional Med J* 15: 54-60.
4. Kohli A, Singh G (2008) Management of Extremity Vascular Trauma: Jammu Experience. *Asian CardiovascThorac Ann* 16: 212-214.
5. Asensio JA, Kuncir EJ, García-Núñez LM, Petrone P (2006) Femoral Vessel Injuries: Analysis of Factors Predictive of Outcomes. *J Am CollSurg* 203: 512–520.
6. Kauvar DS, Sarfati MR, Kraiss LW (2011) National trauma databank analysis of mortality and limb loss in isolated lower extremity vascular trauma. *J Vasc Surg* 53: 1598-1603.
7. Franz RW, Shah KJ, Halaharvi D, Franz ET, Hartman JF, et al. (2011) 5-year review of management of lower extremity arterial injuries at an urban level I trauma center. *J VascSurg* 53: 1604-1610.
8. Petersen K, Waterman P (2011) Prophylaxis and treatment of infections associated with penetrating traumatic injury. *Expert Rev Anti-Infec Ther* 9: 81-96.
9. Branco BC, Inaba K, Barmparas G, Schnüriger B, Lustenberger T, Talving P, et al. (2011): Incidence and predictors for the need for fasciotomy after extremity trauma: A 10-year review in a mature level I trauma centre. *Injury* 42: 1157–1163.
10. Sharma D, Sisodia A, Devgarha S, Mathur RM (2014) Management of vascular trauma: A single center 10 years experience. *Journal-CVS* 2: 33-38.