

# Immediate Reconstruction Using Autogenous Bone Graft in Huge Compound Odontoma

Tamer Zerener<sup>1</sup>, Metin Sencimen<sup>1</sup>, Gurkan Rasit Bayar<sup>1</sup>, Bahadır Kan<sup>2</sup>, Hasan Ayberk<sup>1</sup>, Gamze Arici<sup>1</sup>

<sup>1</sup>Gulhane Military Medical Academy, Department of Oral and Maxillofacial Surgery Ankara/Turkey, <sup>2</sup>Faculty of Dentistry, Kocaeli University, Kocaeli/ Turkey

## Abstract

Odontoma is placed into the odontogenic tumor classifications. But it is known as a hamartomatous lesion or a developmental abnormality rather than a odontogenic tumour. It is subclassified into 2 types: (a) compound odontoma: consisting of many little teeth like structures (denticles) (b) complex odontoma: the feature is not like a tooth but it is made of dental tissues in irregular amounts. In this paper, we present two different compound odontoma cases treated by a similar technique using “Autogenous Bone Cover”. Very large odontomas were enucleated and surgical side was covered with autogenous bones. After that, autogenous bones were fixed by reconstruction plates and mini titan screws, in order to avoid a possible fracture. After one year of follow up period, healings of the patients were uneventful.

*Key Words: Compound odontoma, Autogenous Bone Cover Technique, Iliac Graft, Mandible*

## Introduction

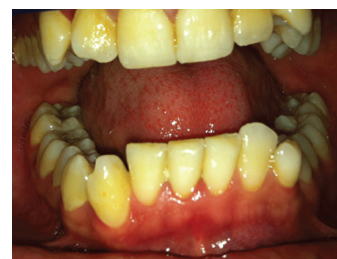Due to its histological features, odontoma is placed into the odontogenic tumor classifications. However, it is known as a hamartomatous lesion or a developmental abnormality rather than a odontogenic tumour which is a fully developed lesions consists of enamel, dentin, tooth pulp and cementum [1]. Odontoma constitutes 22 % of all odontogenic tumors [2]. According to the WHO classification (2005) they are sub classified into 2 types: (a) compound odontoma: consisting of many little tooth like structures (denticles) (b) complex odontoma: the feature is not like a tooth but it is made of dental tissues in irregular amounts [3]. Compound odontoma: mostly occurs at anterior maxilla, whereas the complex odontoma has a tendency to occur in the posterior mandible [4].

Odontomas are usually asymptomatic. Therefore, it can be diagnosed accidentally by a radiography. Enucleation is the first choice of treatment. On the other hand, if the lesion is large and/or very close to the anatomic landmarks, enucleation may result in potential fractures and/or damages to the anatomic landmarks [5]. In this case report, we are presenting our surgical approach for the treatment of two different patients with compound odontoma showing similar localization. Thereby, we introduce a reconstruction method which could be used as an alternative.

## Case Reports

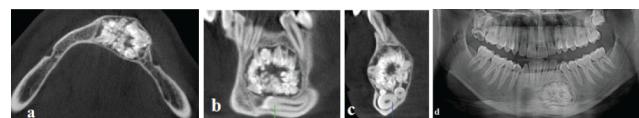
### Case 1

A 22-year-old male patient referred to our department with a complaints of the presence of a lesion at his anterior mandibular region, which was diagnosed at another dental center during a routine dental radiography. He didn't have any complaint about pain or any other relevant symptoms. The clinical examination didn't reveal any abnormality except a deciduous canine tooth on the mandible and simple crowding in the mandibular anterior teeth (*Figure 1*).



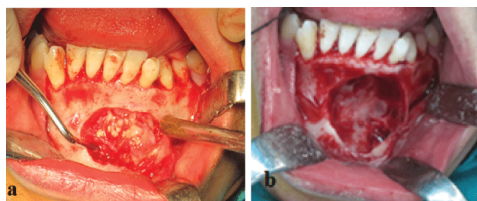
*Figure 1. Initial intraoral view of the patient.*

Orthopantomographic and computed dental tomographic views of the patient showed that a circular radiopaque lesions occupying the intraosseous region from the apex of the left first mandibular incisor to the left first mandibular premolar tooth (*Figure 2*). The impacted left mandibular canine and supernumerary teeth were lying below the lesion on the basis of the mandible.



*Figure 2. Preoperative CBCT; (a) axial view; (b) coronal view; (c) sagittal view; (d) orthopantomographical view.*

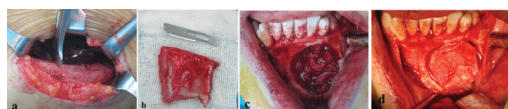
The lesion was involving many tooth-like structures with varying radiodensities resembling enamel, dentin and cementum. According to the results of the clinical and radiological evaluation our primary diagnosis was odontoma. We planned to enucleate the lesions under general anesthesia. Endodontic treatment was performed to 31th, 32th, 73th and 34th teeth. After providing general anesthesia, local anesthesia (articaine containing 1:100.000 epinephrine, Ultracaine DS, Aventis, Turkey) was applied to the mandible as well, for the purpose of vasoconstriction. A full-thickness mucoperiosteal flap and round shaped bone window was elevated in order to reach the lesion (*Figure 3*).



**Figure 3.** Intraoperative view of the patient; (a) Appearance of the intraosseous lesion after the bone cover was removed; (b) Appearance of the bone cavity after the enucleation of the lesion.

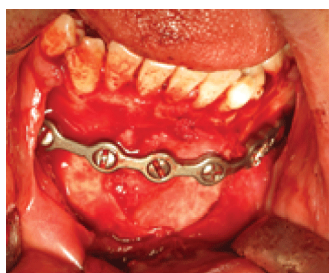
Surgical excision of the lesion was performed. The impacted canine and supernumerary teeth were also enucleated.

The crista iliac bone was used as autogenous graft. An iliac bone graft harvested from the left side of the patient was used to cover and fill up the cavity of the lesion enucleated. The graft was adjusted by cutting, in order to fill the cavity (Figure 4).



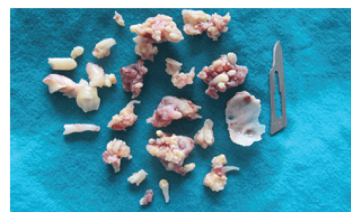
**Figure 4.** (a) Appearance of the donor site of iliac bone graft; (b) The autogenous bone graft harvested from the left iliac bone; (c) Appearance of the bone cavity after filling with autogenous bone graft; (d) iliac bone cover fitted to the bone cavity.

Then, the graft was fixed by a reconstruction plate and mini titan screws, in order to avoid a possible fracture (Figure 5).

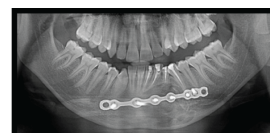

**Figure 5.** The intraoperative view of the reconstruction plate fixed onto the iliac bone graft and the mandible by mini titan screws.

Bleeding was controlled and the wound was closed primarily. Numerous denticles were enucleated with their fibrous capsules (Figure 6). The diagnosis of compound odontoma was also confirmed by pathology. The patient was discharged two weeks after surgery. At the end of one year follow up period, healing process of the patient was uneventful (Figure 7).



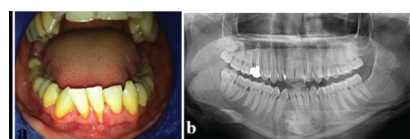
**Figure 6.** Numerous enucleated compound odontomas, canine and supernumerary teeth.



**Figure 7.** Postoperative orthopantomograph of the patient.

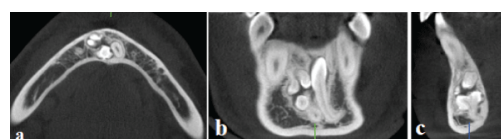
## Case 2

A 27 year-old male patient referred to our department with a complaint of swelling on his mandible. Following the clinical and radiological examination, our primary diagnosis was odontoma, and we planned to enucleate the lesion under general anesthesia (Figure 8).



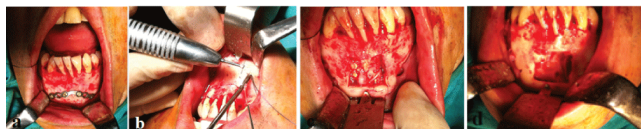
**Figure 8.** Initial; (a) Intraoral view; (b) Orthopantomographical view of the patient.

Then, a cone beam computerized tomography (CBCT) was taken to evaluate the lesion comprehensively (Figure 9).



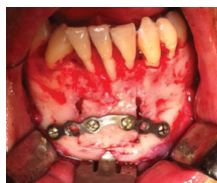**Figure 9.** Preoperative CBCT; a. axial view, b. coronal view, c. sagittal view.

Endodontic treatments were performed to his mandibular incisors (one of them was missing). After providing general anesthesia, for providing vasoconstriction, local anesthesia (articaine containing 1:100.000 epinephrine, Ultracaine DS, Aventis, Turkey) was applied to the mandible as well. A full-thickness mucoperiosteal flap was elevated. A reconstruction plate was adapted to the operation site. We made a square shaped (2x2cm in size) bone incision using burs. Then, we removed that compact bone layer carefully. Thus, while providing an access to the lesion, we obtained an autogenous bone graft to cover the cavity of the lesion enucleated. Surgical excision of the lesions were performed (Figure 10).

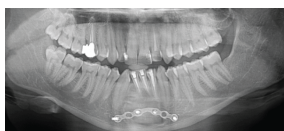


**Figure 10.** (a) Adaptation of the reconstruction plate onto the operation site; (b) The view of the square shaped bone incision; (c) The view of the lesion; (d) The view of the bone cavity after enucleation of the lesion.

We fixed the autogenous bone graft with a reconstruction plate and mini titan screws (*Figure 11*). Bleeding was controlled and the wound was closed primarily. The biopsy specimen was sent for histopathological examination. The diagnosis of compound odontoma was also confirmed by pathology. The patient was discharged one week after surgery. At the end of 9 months follow up period, healing process of the patient was uneventful (*Figure 12*).



**Figure 11.** Intraoperative view of the reconstruction plate fixed to the autogenous graft and the mandible by mini titan screws.



**Figure 12.** Postoperative orthopantomograph of the patient.

## Discussion

In general, odontoma is usually asymptomatic, and it is diagnosed incidentally during routine dental radiographical examinations [5]. But they can grow up to very large sizes in unusual directions. And also, they can displace or prevent eruption of teeth, and cause cystic transformation [6]. Therefore, the lesion is usually treated by total excision, and there is very little chance of occurrence. Enucleation of the small or average size lesions can provide complete healing without causing any sequelae. Whereas, it may result in potential fractures and/or damage to the anatomic structures, if the odontoma is very large in size. In the literature, there are publications reporting the treatment alternatives to avoid such problems. Erdoğan et al. [5] managed a case in which the compound odontoma involved the four quadrant of the jaws. Only the part of the odontomas penetrating the oral mucosa was removed, considering the general health status of the patient, and the lesion's size and localization. Arun kumar et al. [6] used a palatal island flap to eliminate the dehiscence occurred after enucleation of an odontoma occupying the maxillary sinus. Utumi et al. [7] used an iliac bone graft and

titanium mesh for reconstruction of the cavity occurred following the excision of a complex odontoma in the maxilla.

In this case report, we explained our surgical approach used for the treatment of two different cases with compound odontoma in their mandibular symphysis. In both cases, a large bone cavity occurred after enucleation. These empty spaces could pose a risk factor for potential fractures and non-aesthetic facial contours. Importance of the mentalis muscle attachment and continuity in the surgical procedures on symphyseal area, especially during symphysis graft procedures has been suggested [8-10]. Surgical treatment of the lesions around the symphyseal area could be a possible reason for ptosis of the mentalis muscle [8,9]. After enucleation, mentalis muscle should be repositioned by the surgeons as accurately as possible. The technique described in the current study could provide a sufficient repositioning of the mentalis muscle, after the enucleation of compound odontomas around the symphyseal area. In both cases we aimed to strengthen these empty cavities using reconstruction plates in order to prevent the fractures. In the first case, we harvested an autogenous graft from left iliac bone of the patient. We adapted this autogenous bone graft to the recipient region, and then we fixed it by a reconstruction plate and mini titan screws. In the second case, we obtained the autogenous bone graft by cutting and removing carefully the intact bone overlying the compound odontomas. After enucleation of the lesions, autogenous bone grafts and reconstruction plates were fixed together, following the adaptation of autogenous bone grafts to fit inside of the cavities.

Different types of materials have been used to replace missing bone during the last century, but due to superior properties such as osteogenic capacity compared to both allografts and xenografts, autogenous bone graft is the gold standard for maxillofacial reconstruction. Moreover, autogenous grafts have the advantages of biocompatibility and lower potential for infection, exposure, and foreign body reaction. On the other hand, a few complications have been described such as; nerve injury, infection and unaesthetic scars at the donor site in the literature. However, iliac graft harvest technique allows harvesting with low morbidity [11]. Thus, in both cases, we didn't need to use any other bone graft except autogenous one.

No complication occurred during the healing process. Follow-up periods of both patients were uneventful, and other disorders such as ptosis and paresthesia were not also seen. The results were quite satisfactory as aesthetically. Therefore, we think that "autogenous bone cover technique" could be used effectively during the surgical treatments of pathologies on symphyseal area.

## Conclusion

After the enucleation of odontomas in large sizes, we believe that the technique described here could be an effective method for preventing the possible postoperative complications, such as bone fractures, contour disorders, and also high treatment costs due to the requirement of using factory made bone grafts. Rigorous clinical studies are required about this subject in the future.

## Conflict of Interest

None

## Funding Source

None

## References

1. Neville BW, Damm DD, Allen CM, Bouquot JE. Odontoma. In: Neville BW, Damm DD, Allen CM, Bouquot JE editors. *Oral and maxillofacial pathology*. 2nd ed. Philadelphia: Saunders; 2005. 631-633.
2. Marx RE, Stern D. Oral and maxillofacial pathology. Quintessence Publishing Co, Florida 2002: 678-679.
3. Bhargavan Sarojini S, Khosla E, Varghese T, & Johnson Arakkal L. (2014). Eruption of Odontomas into the Oral Cavity: A Report of 2 Cases. *Case Reports in Dentistry*. 2014.
4. Philipsen HP, Reichart PA, Praetorius F. Mixed odontogenic tumours and odontomas. Considerations on interrelationship. Review of the literature and presentation of 134 new cases of odontomas. *Oral Oncology*. 1997; **33**: 86-99.
5. Erdogan Ö, Keceli O, Oztunc H, Evlice B, Altuğ HA, Günhan O (2014). Compound odontoma involving the four quadrant of the jaws: A case report and review of the literature. *Quintessence international*. 1985; **45**: 341-344.
6. Arunkumar KV, Vijaykumar Nitin Garg. Surgical management of an erupted complex odontoma occupying maxillary sinus. *Annals of maxillofacial surgery*. 2012; **2**: 86.
7. Utumi Estevam Rubens, et al. Maxillary reconstruction with particulate bone graft and titanium mesh: a treatment option for large complex odontoma of the maxilla. *Journal of Dentistry for Children*. 2011; **78**: 124-128.
8. Nola CF, Rodriquez-Chessa JG, Ortega-Lopes R, Cabral-Andrade V, Barbeiro RH, Mazzonetto R. Prospective study of soft tissue contour changes following chin bone graft harvesting. *International Journal of Oral and Maxillofacial Surgery*. 2012; **41**: 176-179.
9. Varol A, Sencimen M, Kocabiyik N, Gulses A, Ozan H. Clinical and anatomical aspects of possible mylohyoid nerve injury during genioplasties. *International Journal of Oral and Maxillofacial Surgery*. 2009; **38**: 1084-1087.
10. Sencimen M, Gulses A, Varol A, Okcu KM, Bayar GR. Two simple techniques for bone graft harvesting from mandibular symphysis. *The Journal of Dental Faculty of Atatürk University*. 2010; **147**: 12-16.
11. Acocella A, Nardi P, Tedesco A, Beninati F, Giannini D. Anterior iliac bone grafts: techniques and sequelae. Report on 107 cases and review of the literature. *Minerva Stomatologica*. 2003; **52**: 441-453.