

Iatrogenic Displacement of Impacted Mandibular Third Molar into the Pterygomandibular Space: A Case Report

Berkay Tolga Suer¹, Ismail Doruk Kocyigit², Kerim Ortakoglu³

¹Department of Oral and Maxillofacial Surgery, Gülhane Military Medical Academy (GMMA), Haydarpaşa Teaching Hospital, Uskudar, Istanbul, Turkey. ²Department of Oral and Maxillofacial Surgery, Kirikkale University, School of Dentistry, Kirikkale, Turkey. ³Department of Oral and Maxillofacial Surgery, Medicana Hospital, Bakirkoy, Turkey.

Abstract

Accidental displacement of an impacted lower third molar into the pterygomandibular space during extraction is a rare complication. The purpose of this article is to report the case of a lower third molar displaced into the pterygomandibular space during an unsuccessful surgical intervention. A 26-year-old male patient presented with infection and trismus was referred to our clinic. The patient's history revealed that he undergone an unsuccessful impacted third molar removal performed by dentist two years ago. The patient was not referred to oral surgeon after the incident, although, the doctor noticed the iatrogenic displacement. On radiological examination, panoramic radiograph and Computed Tomography (CT) scans showed that the displaced tooth was migrated in the pterygomandibular space over the two-year time. Infection and trismus were controlled by antibiotic therapy and physiotherapy before the surgery and the displaced tooth was recovered under local anesthesia. The post-operative period was uneventful and the patient recovered without any sequel.

Key Words: Tooth extraction, Surgery, Third molar, Mandible

Introduction

The displacement of a root fragment, the crown or the entire tooth into adjacent anatomical areas during the removal of an unerupted third molar is a rarely seen complication. The most common sites of displacement are the submandibular space and maxillary sinus [1-5]. On the other hand, less common sites of displacement are the sublingual [5], pterygopalatine [6], infratemporal [4,7] and lateral pharyngeal spaces [8,9], the inferior alveolar canal [10] and pterygomandibular [10]. The dehiscence or the thinness of the lingual cortex and close relation of the roots of the lower third molar seems to pose some risk factors for lower third molars to displace adjacent spaces. Some iatrogenic factors, such as using excessive and uncontrolled forces and poor clinical and/or radiologic judgment, also seem to increase this complication [5]. This case report describes the unusual clinical course of accidentally displaced mandibular third molar into the pterygomandibular space and its surgical management.

Case Report

A 26 year-old male was referred to our clinic with complaints of pain and extreme limitation in mouth opening. The patient's medical history revealed that he had undergone a surgical procedure two years ago. Further investigation showed that during this initial surgical procedure of the removal of the right lower third molar tooth, the practitioner was suddenly aware that the tooth was disappeared. The practitioner assumed that the tooth had displaced into the lingual space and informed the patient of his suspicion. Then, panoramic radiograph was taken (*Figure 1*) and the doctor noticed that the tooth displaced into the pterygomandibular space. Although the patient was informed about possible complications, patient was not referred to an oral surgeon for removal of the displaced tooth.

For two years, the patient had to take antibiotics many times after this initial procedure because of the repeated infections.

On clinical examination, an acute infection, lymphadenopathy and a slight swelling at the retromolar region at the affected side was noted. The patient's maximal interincisal opening was 16 mm. The tooth was barely palpable in the lingual region. There were no clinical symptoms of dysaesthesia of the lip or tongue. No other complaints were noted at the time of initial examinations. The patient's medical history was non-contributory.

Radiographic examinations consisted of Orthopantomograph (OPG), Computed Tomography (CT), and 3-dimensional reconstruction of the CT scan. An OPG showed that the tooth was displaced into the pterygomandibular region (*Figure 2*). Axial, coronal and 3D-CT scans (*Figure 3*) were taken to determine the exact position of the tooth. These confirmed the position of the tooth on the medial aspects of the mandibular ramus, close to mylohyoid ridge.

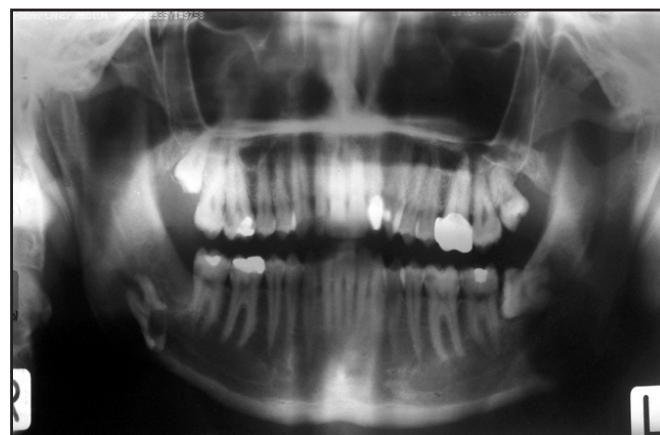

Figure 1. Panoramic radiograph obtained by dental practitioner at the time of initial surgical procedure shows the displaced tooth in the pterygomandibular region.

Corresponding author: Berkay Tolga Suer, Department of Oral and Maxillofacial Surgery, Gülhane Military Medical Academy (GMMA), Haydarpaşa Teaching Hospital, Uskudar, Istanbul, Turkey-34668; Tel: +90-532-4063648; Fax: +90-212-311-2327; e-mail: berkaysuer@hotmail.com

The patient was hospitalized and commenced on a course of Ornidazole and naproxen sodium, and jaw physiotherapy because of the acute infection and severe trismus. At the fifth day of the antibiotics and jaw physiotherapy, his mouth opening improved to 37 mm. We decided to continue Ornidazole treatment for a week and made some arrangements for the removal of the tooth from the pterygomandibular space under local anesthesia.

Articaine HCL was administered locally into surgical area (Ultracaine® DS Fort, Aventis Pharma, Turkey, 1:100,000 epi.). Incision for displaced tooth was made distal to the second molar and continued up to ascending ramus. An oblique release incision from the second molar's distal end into vestibular sulcus was also made. Buccal and lingual mucoperiosteal flaps were raised in the retromolar area. The pterygomandibular space was reached through lingual aspect and the tooth was visualized and removed (*Figure 4*). The surgical site copiously irrigated and granulation tissue removed. The surgical site was closed with 3/0 Vicryl (Ethicon®, Johnson & Johnson Int., Brussels, Belgium). At the post-operative examination 10 days later, healing was uneventful and there were no evidences of any infection or trismus.

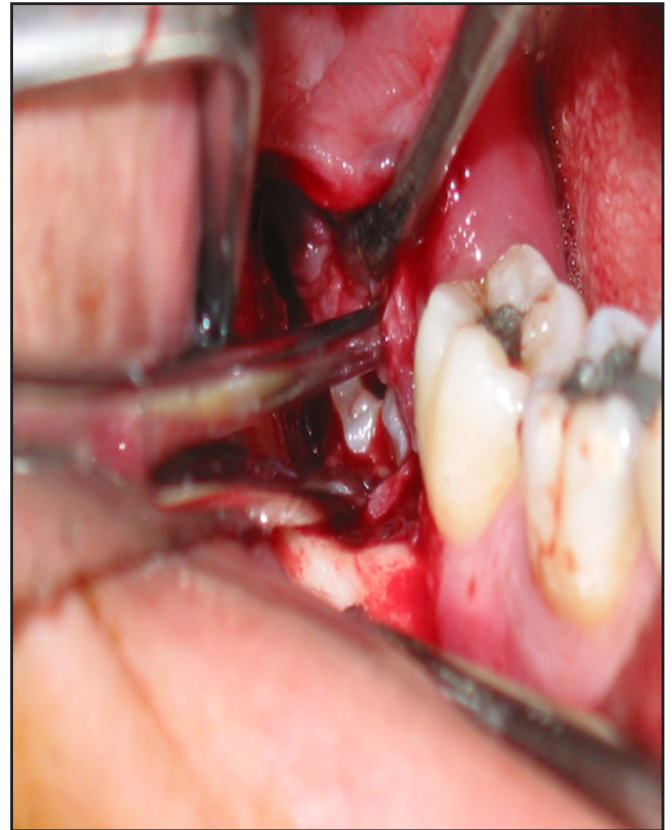

Figure 4. Intra-operative picture shows the retrieval of the displaced lower third molar from the lingual side of the mandible.

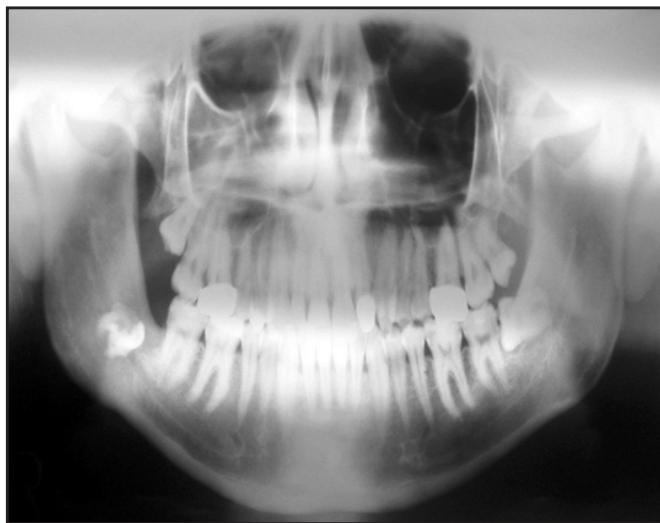


Figure 2: Panoramic radiograph shows the displaced tooth in the pterygomandibular region two years after the initial surgical operation. It shows the displaced tooth migrated to superiorly in the pterygomandibular space.

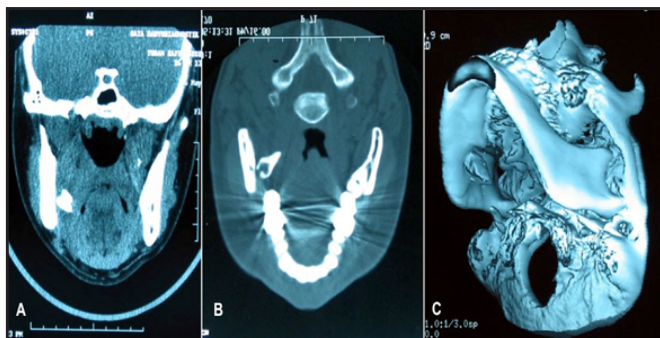


Figure 3: Coronal CT view (A), axial CT view (B) and the 3D-CT view (C) show the accidentally displaced mandibular impacted third molar in the pterygomandibular region and its relation to the adjacent anatomical structures.

Discussion

Iatrogenic displacement of a third molar root or entire tooth during extraction is a rare event [11]. The incident of complication during lower third molar extraction is assessed to be lower than 1% [12]. There is a debate in the literature about the time to retrieve the displaced fragment. Some authors prefer to remove the displaced tooth at the time of the initial surgical procedure or to postpone surgery for as short a time as possible [13,14]. However, others prefer to perform a second surgical intervention 3 or 4 weeks later, after foreign-body-induced fibrous reaction immobilizes the tooth [9,15,16]. On the other hand, delayed intervention may increase the risk of infection and result in a foreign-body reaction or migration of the tooth [2,10]. Several factors, such as size of the displaced fragment, location of the displacement and/or circumstances in which the incidence occurred, are important issues that has to be taken into consideration [5]. According to systematic review done by Hu [12], in most cases patients have no symptoms at all (5 patients in the present sample; 83%). However, if pain and swelling are present in the area, immediate removal of the root should be commenced [12]. According to Aznar-Arasa et al. [5], these symptoms are closely related to the size of displaced fragment, particularly when it exceeds 5 mm. In this presented case, the patient presented with displaced lower third molar, which it had a long neglected clinical course. Even though the first doctor was patient's father, the patient was not referred to oral surgeon or informed about possible complications that could occur when the displaced tooth left without further action. As a result, during this long (2-year) clinical course, the patient had experienced repeated episodes of infection and trismus and forced to use antibiotics and pain killers. As to the authors' knowledge, no such displaced lower

molar tooth has been reported in the literature that had such long neglected clinical course.

The most common cause of iatrogenic displacement of lower third molar is lingual perforation or fracture during extraction, which in addition to an improper or excessive force applied with elevators [5]. In the presented case, authors believed that the lack of surgical skills and/or using improper or excessive force with elevator resulted displacement of the entire lower third molar. Whether a contributory factors, such as; thinness or dehiscence of the lingual plate, were related to this incidence at the first place, could not be known by the authors of this study.

Various conventional radiographic views can be taken to visualize a displaced root or entire tooth from the socket [10]. A periapical radiograph can reveal the displaced fragments or the entire tooth. However, in many cases, exact anatomical location requires panoramic, occlusal, lateral radiographs and CT scan views [8,17]. An orthopantomograph will probably provide the useful information as shown in this case (*Figures 1 and 2*). However, conventional radiographic techniques may not be adequate to precisely locate the displaced tooth in the adjacent soft tissues. Advanced imaging techniques, such as; CT or Cone-beam CT scanning, are often required to locate a displaced tooth and its relation to the adjacent soft tissue [5]. In the authors' opinion, the exact localization of the displaced tooth will facilitate the access and the retrieval of the tooth without damage of the nerves and blood vessels during surgical operation. In this case, CT and 3D-CT views provided useful information about the exact location of the displaced tooth in the pterygomandibular region and allowed the authors prepare for what to expect during retrieval surgery.

Even though couple approaches have been suggested in the literature (intraoral and/or extraoral), surgical access to the antero-inferior aspects of the pterygomandibular space can be achieved without much difficulty via an intra-oral approach using lingual mucoperiosteal flap [18]. However, if

the displacement is deeper into the substance of the medial pterygoid muscle or inferiorly into the submandibular space, an extra-oral approach may provide better access [10]. In this case intra-oral approach was preferred due to the antero-inferior localization of the displaced tooth.

In this presented case, we had two orthopantomograph: the first OPG was obtained by the general practitioner at the time of the first surgery, and the second was obtained after two years by the authors. It is of great importance to note that the first radiograph, which was taken immediately after the initial surgical intervention, has provided us substantial information on the changes in the position of the displaced lower third molar. In this case, fibrous inflammatory tissue reaction was not able to immobilize the displaced tooth as suggested by some authors [15,16]. The displaced tooth migrated superiorly in the pterygomandibular space. The authors of this presented case think that the repeated infections and movement of masticator muscles in this region led to the migration of the displaced third molar.

To prevent this incident, a complete evaluation of all significant factors should be considered in advance. Extraction of third molars should always be performed with proper visual access to the extraction site. Using excessive forces toward lingual bony cortex with elevators should be avoided during extraction [5]. When it happened, the authors believe that a displaced tooth should be removed immediately after its displacement, if it is possible, since a delayed surgical intervention may cause potential complications such as infection, tooth migration and foreign-body reaction as seen in this case. Dental practitioners should be aware of the possible problems associated with the extraction of the lower third molar. If the tooth is displaced into the adjacent anatomical areas during the extraction, the dentist should refer the patient to an oral surgeon as soon as possible to prevent possible complications.

References

1. Pedersen GW. Sequelae and complications of the tooth removal. *Oral surgery*. Saunders: Philadelphia. p. xii; 1988. pp. 405.
2. Pedlar J. Crown of a tooth in the lateral pharyngeal space. *British Dental Journal*. 1986; **161**: 335-336.
3. Oberman M, Horowitz I, Ramon Y. Accidental displacement of impacted maxillary third molars. *International Journal of Oral and Maxillofacial Surgery*. 1986; **15**: 756-758.
4. Shahakbari R, Mortazavi H, Eshghpour M. First report of accidental displacement of mandibular third molar into infratemporal space. *International Journal of Oral and Maxillofacial Surgery*. 2011; **69**: 1301-1303.
5. Aznar-Arasa L, Figueiredo R, Gay-Escoda C. Iatrogenic displacement of lower third molar roots into the sublingual space: report of 6 cases. *International Journal of Oral and Maxillofacial Surgery*. 2012; **70**: e107-e115.
6. Ozer N, Ucem F, Saruhanoglu A, Yilmaz S, Tanyeri H. Removal of a Maxillary Third Molar Displaced into Pterygopalatine Fossa via Intraoral Approach. *Case Reports in Dentistry*. 2013; 392148.
7. Sverzut CE, Trivellato AE, Sverzut AT, de Matos FP, Kato RB. Removal of a maxillary third molar accidentally displaced into the infratemporal fossa via intraoral approach under local anesthesia: report of a case. *International Journal of Oral and Maxillofacial Surgery*. 2009; **67**: 1316-1320.
8. Esen E, Aydogan LB, Akcali MC. Accidental displacement of an impacted mandibular third molar into the lateral pharyngeal space. *International Journal of Oral and Maxillofacial Surgery*. 2000; **58**: 96-97.
9. Ertas U, Yarus MS, Tozoglu S. Accidental third molar displacement into the lateral pharyngeal space. *International Journal of Oral and Maxillofacial Surgery*. 2002; **60**: 1217.
10. Tumuluri V, Punnia-Moorthy A. Displacement of a mandibular third molar root fragment into the pterygomandibular space. *Australian Dental Journal*. 2002; **47**: 68-71.
11. Pasqualini D, Erniani F, Coscia D, Pomatto E, Mela F. Third molar extraction. Current trends. *Minerva Stomatologica*. 2002; **51**: 411-424.
12. Brauer HU. Unusual complications associated with third molar surgery: a systematic review. *Quintessence International*. 2009; **40**: 565-572.
13. Dormer BJ, Babett JA. Root section in the submaxillary space. *Oral Surgery, Oral Medicine, Oral Pathology and Oral Radiology*. 1973; **35**: 876.
14. Huang IY, Wu CW, Worthington P. The displaced lower third molar: a literature review and suggestions for management. *International Journal of Oral and Maxillofacial Surgery*. 2007; **65**: 1186-1190.
15. Pippi R, Perfetti G. Lingual displacement of an entire lower

third molar. Report of a case with suggestions for prevention and management. *Minerva Stomatologica*. 2002; **51**: 263-268.

16. Gay-Escoda C, Berini-Aytes L, Pinera-Penalva M. Accidental displacement of a lower third molar. Report of a case in the lateral cervical position. *Oral Surgery, Oral Medicine, Oral Pathology and Oral Radiology*. 1993; **76**: 159-160.

17. Olusanya AA, Akadiri OA, Akinmoladun VI. Accidental

displacement of mandibular third molar into soft tissue: a case report. *African Journal of Medicine and Medical Sciences*. 2008; **37**: 77-80.

18. De Biase A, Guerra F, Giordano G, Salucci S, Solidani M. Surgical removal of a left lower third molar root after iatrogenic displacement in soft tissue. Case report. *Minerva Stomatologica*. 2005; **54**: 389-393.