

## Histological studies of the toxicity of artesunate on the testes in Wistar rats

\*AM Izunya<sup>1</sup>, AO Nwaopara<sup>1</sup>, AE Aigbiremolen<sup>2</sup>, MAC Odike<sup>3</sup>, GA Oaikhena<sup>1</sup>, JK Bankole<sup>4</sup>

<sup>1</sup>Department of Anatomy; <sup>2</sup>Department of Pharmacology; <sup>3</sup>Department of Pathology;

<sup>4</sup>Department of Medical Laboratory Sciences; College of Medicine, Ambrose Alli University, Ekpoma, Edo State, Nigeria.

\*Corresponding Author: amizunya@gmail.com

### Abstract

The objective of this study was to investigate the effect of oral administration of artesunate on the histology of the testis in wistar rats. Adult male wistar rats used in the study were divided into 3 groups: Group A received 4mg/kg b.w of artesunate daily for 3 days followed by 2mg/kg b.w daily for next 4 days; group B received 8mg/kg b.w of artesunate daily for 3 days followed by 4mg/kg b.w daily for next 4 days and group C were given only distilled water and served as control. The rats were fed with grower's mash purchased from Edo feeds and Flour Mill Ltd, Ewu, Edo state and were given water *ad libitum*. On day eight of the experiment, the rats were weighed and sacrificed by cervical dislocation. The testes were carefully dissected out and quickly fixed in 10% formal saline for routine histological study after H&E method. The histological findings indicated that the treated sections of the testes showed mild sloughing of germ cells from the basement membrane and varying degrees of reduced population of germ cells. These findings suggest that artesunate at normal dose has a deleterious effect on the histology of the testis and could be a potential male antifertility agent. It is therefore recommended that further studies aimed at corroborating these observations be carried out.

**Keywords:** Antimalarial; artesunate; testicular histology; toxicity.

### Introduction

Malaria is a leading cause of mortality and morbidity in developing areas of the world, and remains a major public health problem in endemic regions (Bremner et al., 2004). Resistance to available drugs is increasing, creating a need for new drugs that are well tolerated and simple to use. In the face of this ominous situation, artemisinin and its derivatives (artesunate, artemether, arteether, and dihydroartemisinin) have given renewed hope for combating resistant malaria (Hein, 1994; Harinasuta and Karbwang, 1994). These drugs have gained considerable prominence in the chemotherapy of both uncomplicated and severe falciparum malaria by demonstrating high activity against multidrug-resistant falciparum strains with low toxicity profiles (Chanthap et al., 2005).

Artesunate is a drug used to treat malaria, especially chloroquine resistant malaria in Nigeria. It is a semi-synthetic derivative of artemisinin, the active compound of the Chinese herb *Artemisia annua* which consists of the sodium succinyl salt of dehydroartemisinin (Ittarat et al., 1999). It has been used against multidrug-resistant strains of plasmodium falciparum (Hien and White, 1993; Batty et al., 1996; Price, et al. 1998) with good tolerability and lack of significant adverse side effects (Looareesuwan, 1994).

Serious concern has however been raised about uncontrolled use of artemisinin derivatives because at the moment they are the last resort in the combat against multi-drug resistant *P. falciparum* malaria (White, 1994). The use of these drugs should be controlled and restricted to proven multi-drug resistance on severe malaria in order to preserve their efficacy (Mulenga, 1998) and avoid emergence of resistant strains. In malaria endemic areas such as Nigeria, self medication is quite common and purchase of antimalarials in the open market is rampant (Nwanjo and Oze, 2007). The possibility of administering overdose and misappropriation in the usage of antimalarials are very common. Drugs though useful in the treatment of disease conditions could also produce untoward effects in the individual. The untoward or toxic effect may be harmful to the patient (Udonan, 2000).

Several studies have shown that high doses of artesunate can produce neurotoxicity such as selective damage to brainstem centres, gait disturbances in mice and rats (Nontprasert et al., 1998; Genovese, 2000; Nontprasert et al., 2000) and loss of spinal cord and pain response mechanisms in animals (Genovese et al., 1995; Dayan, 1998). Others showed some varying degree of cell clustering, cellular hypertrophy, and intercellular vacuolations in the stroma of the

superior colliculus of artesunate treated animals (Eweka and Adjene, 2008a). Another showed some degenerative and necrotic changes, cellular hypertrophy, and increase intercellular vacuolations in the stroma of the stomach of rats (Eweka and Adjene, 2008b). However, toxicity studies on the rat testis suggest that under certain conditions, artesunate will suppress spermatogenesis (Jewo et al., 2008) indicating that exhaustive studies of the drug's effects on fertility are needed.

The testis, which is the major male reproductive organ, is responsible for sperm production or spermatogenesis. It is suspended in the bilateral compartments of the scrotal sac. Production of spermatozoa from stem cells of the testis is a complex process that requires about 64 days in human (Heller & Clermont, 1964) and 48-53 days in rat (Clermont et al., 1959; Hilscher, 1964). Sertoli cells play a key role in spermatogenesis (Sapori et al. 1986; Sharpe, 1993), whereas Leydig cells are the main source of androgen production (Al-Hazmi et al., 2004). Both types of cells can be readily affected by toxicants and chemical drugs (Spielman, 1998; Papadakis et al., 1999). Alteration in the function of these cells may lead to a change in the hormonal balance, disturbed the the process of spermatozoa development and impaired male fertility (Mones et al., 2000 and 2001). This study therefore was undertaken to further examine the effects of artesunate on the histology of the testis in wistar rats, in view of the fact that the effect of artesunate on the morphology of the testis has already been determined (Izunya et al., 2010).

## Materials and Methods

### Location and Duration of Study

This study was conducted at the histology laboratory of the College of Medicine, Ambrose Alli University, Ekpoma, Edo State, Nigeria. The preliminary studies, animal acclimatization, drug procurement, actual animal experiment and evaluation of results, lasted for a period of one month (January, 2010). However, the actual administration of the drug to the test animals lasted for one week (15th, January to 21st, January 2010).

### Animals

Fifteen adult wistar rats weighing between 100-150g were used for this experiment. They were obtained and maintained in the animal house of the College of Medicine, Ambrose Alli University, Ekpoma, Edo State. They were

divided into three groups A, B, and C of five rats each. Groups A and B were the treatment groups, while Group C served as the control. They were kept in each group per cage and fed with grower's mash produced by Bendel Feeds and Flour Mills Limited, Ewu, Nigeria. Water was given *ad libitum*. They were allowed to acclimatize for one week before commencement of the study. Ethical approval was sought and received from the Department of Anatomy, College of Medicine, Ambrose Alli University, Ekpoma, Edo State on the need to observe completely the rules guiding the employment of rats for scientific studies.

### Drug Administration

The artesunate tablets used for this experiment, were manufactured by Mekophar Chemical Pharmaceutical Join-Stock Company, Ho Chi Minh City, Vietnam and purchased from Irrua Specialist Hospital, Irrua, Edo State. The drug solution was made with distilled water (1mg/ml) and administered to the animals by orogastric tube for a period of seven days. The dosage of artesunate was as per WHO recommendation of 4mg/kg body weight daily for 3 days followed by 2mg/kg body weight daily for the remaining 4 days. All the animals were weighed before the experiment. The drugs were administered to the groups as follows:

Group A: 4mg/kg body weight of artesunate daily for 3 days followed by 2mg/kg body weight daily for the remaining 4 days.

Group B: 8mg/kg body weight of artesunate daily for 3 days followed by 4mg/kg body weight daily for the remaining 4 days.

Group C (Control): Distilled water.

The animals were sacrificed by cervical dislocation 24 h after the last dose on the 8th day of the respective treatment and the testes were harvested.

### Histological study

For light microscopic examination, testicular tissues from each groups were fixed with 10% buffered formalin, embedded with paraffin. After routine processing, paraffin sections of each tissue were cut into 5µm thickness and stained with haematoxylin and eosin (Drury and Wallington, 1967). The photomicrographs of the relevant stained sections were taken with the aid of a light microscope.

## Results

Histological analysis of the testes of rats in Group C showed normal morphological appearance with seminiferous tubules in

various shapes and sizes with stratified epithelium (see Plate 1). Histological analysis of the testes of rats in Group A showed seminiferous tubules in various shapes and sizes with mild sloughing of germ cells from the basement membrane (see Plate 2).

Histological analyses of the testes of rats in Group B also showed seminiferous tubules in various shapes and sizes with mild sloughing of germ cells from the basement membrane and reduced population of germ cells when compared with A and C (see Plate 3).

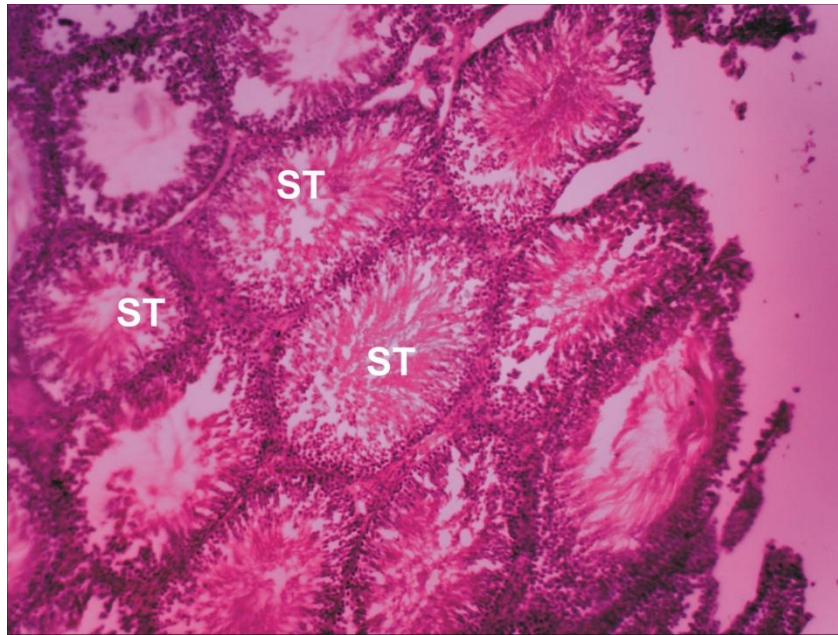


Plate 1 (GROUP C): Control section of the testis (Mag. X100) showing normal histological features. ST- seminiferous Tubules

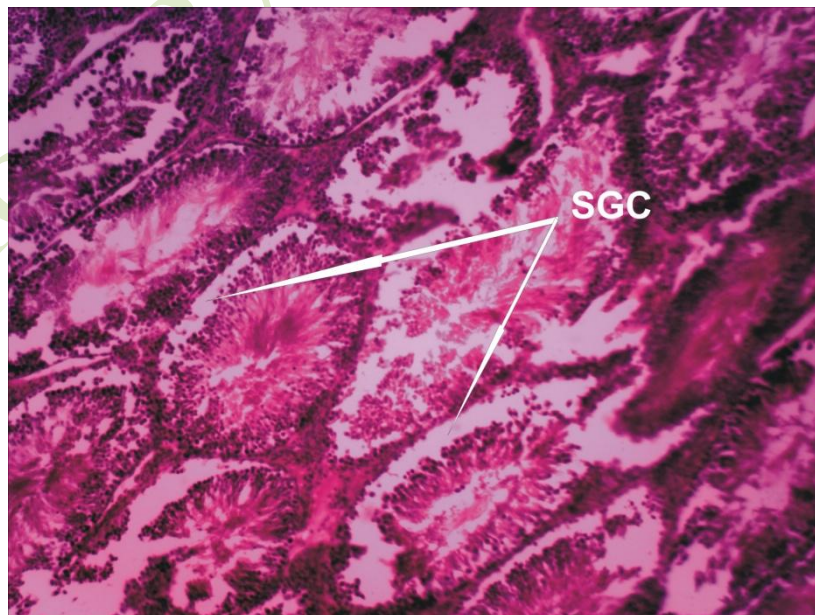


Plate 2 (GROUP A): Treatment section of the testis that received 4mg/kg for 3 days and thereafter 2mg/kg for 2 days of artesunate (Mag. X100), showing mild sloughing of germ cells (SGC) from the basement membrane.

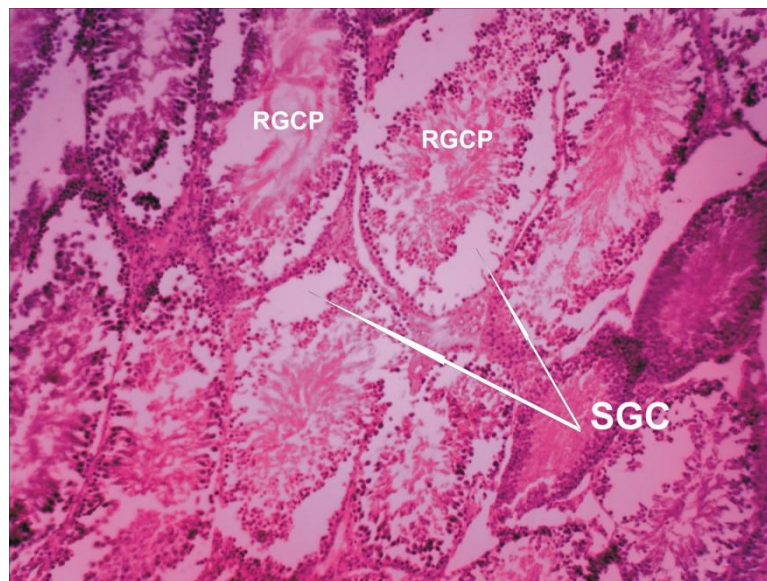


Plate 3 (GROUP B): Treatment section of the testis that received 8mg/kg for 3 days and thereafter 4mg/kg for 4 days of artesunate. (Mag. X100) showing sloughing of germ cells (SGC) from the basement with reduced germ cell population (RGCP).

### Discussion

The histological results suggest that artesunate could cause some degeneration in the rat testes. This was shown by the sloughing of the germinal epithelium from the basement membrane and reduction in the population of the germ cells. These changes were apparently dose dependent. The implication of this is that there is a reduction of viable sperms leading to reduced fertility. This finding agrees with the work of Jewo et al (2008), in which artesunate administration was found to suppress spermatogenesis under certain conditions. Degenerative changes have been reported to result in cell death, which is of two types, namely apoptotic and necrotic cell death (Cohen, 1993; Vaux et al., 1993). These two types differ morphologically and biochemically (Bose and Sinha, 1994). Apoptosis is a non-inflammatory response to tissue damage characterized by a series of morphological and biochemical changes (Sakkas et al., 1999; Sinha and Swerdloff, 1999; Shen et al., 2002; Grunewald et al., 2005). Apoptosis can be triggered in two principal ways: by toxic chemicals or injury leading to damage of DNA or of other important cellular targets, and activation or inactivation of receptors by growth-regulating signal factors in the organism (Schulte-Hermann et al., 1999).

Initiation of apoptosis can result from multiple stimuli, including heat, toxins, reactive oxygen species (ROS), growth factor withdrawal, cytokines such as transforming

growth factor- beta, loss of matrix attachment, glucocorticoid, nitric oxide, and radiation (Thompson et al., 1995; Pollman et al., 1996). These stimuli work in conjunction with other intrinsic factors that determine the cell's potential to undergo apoptosis (McConkey and Orrenius, 1991). In the context of male reproductive tissue, apoptosis helps in elimination of abnormal spermatozoa, thus maintaining the nursing capacity of the Sertoli cells (Sinha and Swerdloff, 1999). However, high levels of ROS disrupt the inner and outer mitochondrial membranes, inducing the release of the cytochrome-C protein and activating the caspase cascade which ultimately results in the fragmentation of a cell's DNA (Wyllie, 1980; Green, 1998; Makker et al., 2009).

Pathological or accidental cell death is regarded as necrotic and could result from extrinsic insults to the cell such as osmotic, thermal, toxic and traumatic effects (Farber et al., 1981). The process of cellular necrosis involves disruption of the membranes structural and functional integrity. Cellular necrosis is not induced by stimuli intrinsic to the cells as in programmed cell death (PCD), but by an abrupt environmental perturbation and departure from the normal physiological conditions (Martins et al., 1978). Generally, artesunate exerts its anti-malarial activity by the generation of reactive oxygen species (ROS) from its endoperoxide bond (Maggs et al., 1988) leading to lipid peroxidation (Robert et al., 2001). The accumulation of lipid

peroxides is toxic to the membrane structure, leading to a change in permeability and to disintegration of cellular organelles (Muller and Ohnesorge, 1982). ROS generation is a normal component of oxidative phosphorylation and plays a role in normal redox control of physiological signaling pathways (Murdoch et al., 2006; Sawyer et al., 2002; Giordano, 2005). However, excessive ROS generation triggers cell dysfunction, lipid peroxidation, and DNA mutagenesis and can lead to irreversible cell damage or death (Murdoch et al., 2006; Sawyer et al., 2002; Giordano, 2005).

ROS are small, oxygen-based molecules that are highly reactive because of unpaired electrons (Papa and Skulachev, 1997). The most prominent ROS are the superoxide anion ( $O_2^{\bullet-}$ ), hydrogen peroxide ( $H_2O_2$ ), and the hydroxyl ion ( $OH^\bullet$ ) (Turner and Lysiak, 2008). Cells also have intrinsic antioxidant systems that counter ROS accumulation. These include enzymes such as catalase, glutathione peroxidases, and superoxide dismutase, and nonenzymatic antioxidants, such as vitamins E, C, beta carotene, ubiquinone, lipotic acid, and urate (Giordano, 2005; Nordberg and Arner, 2001). Nevertheless, under several situations, the rate of generation of ROS exceeds that of their removal and oxidative stress occurs (Giordano, 2005; Di Giulio et al., 1995; Halliwell and Gutteridge, 2000; Livingstone, 2001). However, more severe oxidative stress can cause cell death and even moderate oxidation can trigger apoptosis, while more intense stresses may cause necrosis (Lennon et al., 1991). However, under the severe levels of oxidative stress that cause necrosis, the damage causes ATP depletion, preventing controlled apoptotic death and causing the cell to simply fall apart (Lelli et al., 1998; Lee et al., 1999).

In this study, artesunate may have acted indirectly through generation of high levels of ROS or directly as toxin to the cells of the testis, affecting their cellular integrity and causing defect in membrane permeability and cell volume homeostasis. In cellular necrosis, the rate of progression depends on the severity of the environmental insults. The greater the severity of the insults the more rapid the progression of neuronal injury (Ito et al., 2003). The principle holds true for toxicological insult to the brain and other organs (Martins et al., 1978). Thus, it may be inferred from this result that normal and double normal dose of artesunate resulted in toxic effects on the testis.

## Conclusion

Our study suggests that artesunate at normal dose has a deleterious effect on the histology of the testis of adult wistar rats. Thus, there is a need to determine if these observations in wistar rats may be applicable to humans and in this regard, one can suggest that artesunate at normal dose could be a potential male antifertility agent. We therefore recommend that further studies be carried out in humans to corroborate these findings and that self-medication involving artesunate should be discouraged.

## References

- Al-Hazmi E, Shakar S, Al-Sagaff S, Khoraium S, 2005. Histological changes of testis in mice after administration of doxorubicin HCL (Adribastina), cytotoxic drug. Proceedings of 2nd Saudi Science Conference, Faculty of Science, KAU, Part 1, 99-117.
- Batty KT, Ilett KF, Davis T, 1996. Chemical stability of artesunate injection and proposal for its administration by intravenous infusion. *Journal of Pharmacy and Pharmacology*, 48: 22–26.
- Bose S, Sinha SP, 1994. Modulation of Ochratoxin-produced genotoxicity in mice by vitamin C. *Food and Chemical Toxicology*, 32: 533-537.
- Bremner JG, Alilio MS, Mills A, 2004. Conquering the intolerable burden of malaria: what's new, what's needed: a summary. *American Journal of Tropical Medicine and Hygiene*, 71: 1-15.
- Chanthap L, Tsuyuoka R, Na-Bangchang K, Nivanna N, Suksom D, Sovannarith T, Socheat D, 2005. Investigation of Bioavailability, Pharmacokinetics and safety of new Pediatric formulations of Artesunate and Mefloquine. *Southeast Asian Journal of Tropical Medicine and Public Health*, 36 (1): 34-35.
- Cohen JJ, 1993. Apoptosis. *Immunology Today*, 14: 126-130.
- Clermont Y, 1972. Kinetics of spermatogenesis in mammals: seminiferous epithelium cycle and spermatogonia renewal. *Physiological Reviews*, 52: 198-235.
- Clermont Y, Leblond CP, Messier B, 1959. Dure'e du cycle de l'epithelium se'minal du rat. *Archives of Microscopic Anatomy and Experimental Morphology*, 48: 37–56.
- Dayan AD, 1998. Neurotoxicity and artemisinin compounds: Do the observations in animals justify limitations in clinical use? Paper presented at a conference convened by the International Larveran Association. Annecy, France. 19-22.

- Di Giulio RT, Benson WH, Sanders BM, Van Veld PA, 1995. Biochemical mechanisms: metabolism, adaptation, and toxicity. In: Rand G (Ed.), *Fundamentals of Aquatic Toxicology. Effects, Environmental Fate, and Risk Assessment*. Taylor and Francis, London.
- Drury RAB, Wallington EA, Cameron R, 1967. *Carleton's Histological Techniques: 4th ed.*, Oxford University Press NY, U.S.A., 279-280.
- Eweka AO, Adjene JO, 2008a. Histological studies of the effects of oral administration of artesunate on the superior colliculus of adult wistar rats. *Internet Journal of Tropical Medicine*, 4(2): 1-9.
- Eweka AO, Adjene JO, 2008b. Histological studies of the effects of oral administration of artesunate on the stomach of adult wistar rats. *Internet Journal Health*, 7(1): 1-7.
- Farber JL, Chein KR, Mittnacht S, 1981. The pathogenesis of irreversible cell injury in ischemia. *American Journal of Pathology*, 102: 271-281.
- Genovese RF, Petras JM, Brewer TG, 1995. Arteether neurotoxicity in the absence of deficits in behavioral performance in rats. *Annals of Tropical Medicine and Parasitology*, 89 (4): 447-449.
- Genovese RF, Newman BD, Brewer TG, 2000. Behavioral and neural toxicity of the artemisinin antimalaria arteether, but not artesunate and artelinate in rats. *Journal of Pharmacology, Biochemistry and Behavior*, 67(1): 37-44.
- Giordano FJ, 2005. Oxygen, oxidative stress, hypoxia, and heart failure. *Journal of Clinical Investigation*, 115: 500-508.
- Green DR, 1998. Apoptotic pathways: the roads to ruin. *Cell*, 94: 695-698.
- Grunewald S, Paasch U, Said TM, Sharma RK, Glander HJ, Agarwal A, 2005. Caspase activation in human spermatozoa in response to physiological and pathological stimuli. *Fertility and Sterility*, 83 (Suppl 1): 1106-2.
- Halliwell B, Gutteridge JMC, 2000. *Free Radicals in Biology and Medicine*, 3rd ed. Oxford University Press, Oxford.
- Harinasuta T, Karbwang J, 1994. Qinghaosu: a promising antimalarial. *Journal of American Medical Association*, SEA, 3.
- Heller CH, Clermont Y, 1964. Kinetics of the germinal epithelium in man. *Recent Progress in Hormone Research*, 20: 545-575.
- Hein TT, 1994. An overview of the clinical use of artemisinin and its derivatives in the treatment of falciparum malaria in Vietnam. *Transactions of the Royal Society of Tropical Medicine and Hygiene*, 88 (Supplement): 7-8.
- Hien TT, White NJ, 1993. Qinghaosu. *Lancet*, 341: 603-608.
- Hilscher W, 1964. Beitrage zur orthologic und pathologies des "spermatogenesis" der ratte. *Beitr Pathological Anatomy*, 130: 69-132.
- Ito U, Sparts M, Walker MJR, Warzo I, 2003. Experimental Cerebral Ischemia in Magolian Gerbils (1). Light microscope observations. *Acta Neuropathology USA*, 32: 209-223.
- Ittarat W, Udomsangpeth R, Chotivanich RKT, Looareesuwan S, 1999. The effects of quinine and artesunate treatment on plasma tumor necrosis factor levels in malaria infected patients. *Southeast Asian Journal of Tropical Medicine and Public Health*, 30: 7-10.
- Izunya AM, Nwaopara AO, Aigbiremolen A, Oaikhena GA, 2010. Body and Testicular Weight Changes in Adult Wistar Rats Following Oral Administration of Artesunate. *Research Journal of Applied Science, Engineering and Technology*, 2(3): 302-306.
- Jewo PI, Fadeyibi IP, Saalu LC, Amole OO, Izegbu MC, Ashiru OA, 2008. Effects of Short and Medium Term use of Artesunate on Fertility in Male Rats. *Nigerian Journal of Health and Biomedical Sciences*, 7 (2).
- Lee YJ, Shacter E, 1999. Oxidative stress inhibits apoptosis in human lymphoma cells. *Journal of Biological Chemistry*, 274 (28): 19792-8. doi: 10.1074/jbc.274.28.19792. PMID 10391922.
- Lelli JL, Becks LL, Dabrowska MI, Hinshaw DB, 1998. ATP converts necrosis to apoptosis in oxidant-injured endothelial cells. *Free Radical Biology and Medicine*, 25 (6): 694-702. doi:10.1016/S0891-5849(98)00107-5. PMID 9801070.
- Lennon SV, Martin SJ, Cotter TG, 1991. Dose-dependent induction of apoptosis in human tumour cell lines by widely diverging stimuli. *Cell Proliferation*, 24 (2): 203-14. doi:10.1111/j.1365-2184.tb01150.x. PMID 2009322.
- Livingstone DR, 2001. Contaminant reactive oxygen species production and oxidative damage in aquatic organisms. *Marine Pollution Bulletin*, 42: 656-666.
- Looareesuwan S, 1994. Overview of clinical studies on artemisinin derivatives in Thailand. *Transactions of the Royal Society of Tropical Medicine and Hygiene*, 88 (supplement): s9-s11.
- Makker K, Agarwal A, Sharma R, 2009. Oxidative stress and male infertility. *Indian Journal of Medical Research*, 129: 357-367.
- McConkey DJ, Orrenius S, 1991. In *Apoptosis: The Molecular Basis of Cell Death* (Tome LD and Cope

FO, eds), pp. 227-246, Cold Spring Harbor Laboratory Press.

Maggs JL, Tingle MD, Kitteringham NR, Park BK, 1988. Drug-protein conjugates--XIV. Mechanisms of formation of protein-arylated intermediates from amodiaquine, a myelotoxin and hepatotoxin in man. *Biochemical Pharmacology*, 37 (2): 303-11.

Martins LJ, Al-Abdulla NA, Kirsh JR, Sieber FE, Portera-Cailliau C, 1978. Neurodegeneration in excitotoxicity, global cerebral ischaemia and target deprivation: A perspective on the contributions of apoptosis and necrosis. *Brain Research Bulletin*, 46 (4): 281-309.

Monsees TK, Franz M, Gebhardt S, Winterstein U, Schill WB, Hyatpour J, 2000. Sertoli cell as a target for reproductive hazards. *Andrologia*, 32: 239-246.

Monsees TK, Hinkel S, Mihm K, Endo F, Schill WB, Hyatpour J, 2001. Effects of environmental hormones on the functions of the testicular cells. Proceedings of the 2nd status-seminar "Endocrine disruptors" Berlin 2001, Um Welt Bundesamt, Berlin, 133-136.

Mulenga M, 1998. Facing drug resistance: therapeutic option for treatment of uncomplicated *Plasmodium falciparum* malaria in adult Zambians. *Journal of Medicine and Health Sciences*, 2(1): 11-20.

Muller L, Ohnesorge FK, 1982. Difference response of liver parenchymal cells from starved and fed rats to cadmium. *Toxicology*, 25: 141-150.

Murdoch CE, Zhang M, Cave AC, Shah AM, 2006. NADPH oxidase-dependent redox signalling in cardiac hypertrophy, remodelling and failure. *Cardiovascular Research*, 71: 208-215.

Nontprasert A, Pukrittayakamee S, Dondorp AM, Clemens R, Loareesuwan S, White NJ, 2002. Neuropathologic toxicity of artemisinin derivatives in a mouse model. *American Journal of Tropical Medicine and Hygiene*, 67: 423-429.

Nontprasert A, Pukrittayakamee S, Nosten-Bertrand M, Vanijanonta S, 1998. Assessment of neurotoxicity of parenteral artemisinin derivatives in mice. *American Journal of Tropical Medicine and Hygiene*, 59(4): 519-522.

Nordberg J, Arner ES, 2001. Reactive oxygen species, antioxidants, and the mammalian thioredoxin system. *Free Radical Biology and Medicine*, 31: 1287-1312.

Nwanjo H, Oze G, 2007. Acute Hepatotoxicity Following Administration Of Artesunate In Guinea Pigs. *The Internet Journal of Toxicology*, 4 (1).

Papa S, Skulachev VP, 1997. Reactive oxygen species, mitochondria, apoptosis and aging. *Molecular and Cellular Biochemistry*, 174: 305-319.

Papadakis VE, Vlachopapadopoulou K, Syckle K, Tan C, Sklar C, 1999. Gonadal function in young patients successfully treated for Hodgkin disease. *Journal of Pediatric Oncology*, 32 (5): 366-72.

Pollman MJ, Yamada T, Horiuchi M, Gibbons GH, 1996. Vasoactive substances regulate vascular smooth muscle cell apoptosis. *Circulation Research*, 79: 748-756.

Price R, van Vugt M, Nosten F, Luxemburger C, Brockman A, Phaipun L, Chonsuphajaisiddi T, White N, 1998. Artesunate versus artemether for the treatment of recrudescing multidrug-resistant *falciparum* malaria. *American Journal of Tropical Medicine and Hygiene*, 59: 883-888.

Robert A, Benoit-Vical F, Dechy-Cabaret O, Meunier B, 2001. From classical antimalarial drugs to new compounds based on the mechanism of action of artemisinin. *Journal of Pure and Applied Chemistry*, 73(7): 1173-88.

Sakkas D, Mariethoz E, Manicardi G, Bizzaro D, Bianchi PG, Bianchi U, 1999. Origin of DNA damage in ejaculated human spermatozoa. *Reviews of Reproduction*, 4: 31-7.

Sapori PMH, Chatelain P, Vallier P, Saez JM, 1986. In vitro interaction between Sertoli cells and steroidogenic cells. *Biochemical and Biophysical Research Communications*, 134(2): 957-962.

Sawyer DB, Siwik DA, Xiao L, Pimentel DR, Singh K, Colucci WS, 2002. Role of oxidative stress in myocardial hypertrophy and failure. *Journal of Molecular and Cellular Cardiology*, 34: 379-388.

Schulte-Hermann R, Bursch W, Marian B, Grasl-Kraupp B, 1999. Active cell death (apoptosis) and cellular proliferation as indicators of exposure to carcinogens. *IARC Scientific Publications (Lyon)*, 146: 273-285.

Sharpe RM, 1993. The Sertoli cell. LD Russel and MD Grisword (eds). Cache River Press, Florida. 391-418.

Shen HM, Dai J, Chia SE, Lim A, Ong CN, 2002. Detection of apoptotic alterations in sperm in subfertile patients and their correlations with sperm quality. *Journal of Human Reproduction*, 17: 1266-73.

Sinha HAP, Swerdloff RS, 1999. Hormonal and genetic control of germ cell apoptosis in the testis. *Review of Reproduction*, 4: 38-47.

Spielman H, 1998. Reproduction and development. *Environmental Health Perspectives*, 106: 571-576.

Thompson CB, 1995. Apoptosis in the pathogenesis and treatment of disease. *Science*, 267: 1456-1462.

Turner T, Lysiak JJ, 2008. Oxidative Stress: A Common Factor in Testicular Dysfunction. *Journal*

of Andrology, 29(5): 488–498. DOI: 10.2164/jandrol.108.005132

Udonan EI, 2000. Pharmacology made simple for Nurses and Allied professionals. Jireh Printing Press, Ikot Ekpene. 31-36.

Vaux DL, Haecker G, Strasser A, 1994. An evolutionary perspective on apoptosis. Cell, 76: 777-781.

White NJ, 1994. Clinical Pharmacokinetics and Pharmacodynamics of artesunate and derivatives. Transactions of the Royal Society of Tropical Medicine and Hygiene, 88(suppl1): S41-S43.

Wyllie AH, 1980. Glucocorticoid-induced thymocyte apoptosis is associated with endogenous endonuclease activation. Nature, 284: 555–556.

Biology and Medicine