

Employment of Two-Plan Loop Correction for Dental Transposition Treatment in Orthodontics: Report of Two Cases

Picanço PRB, Picanço GV, Lima FC, Dantas TCFB, Marçal FF

Department of Orthodontics, Paulo Picanço School of Dentistry, Fortaleza, Brazil

Abstract

The aim of this article was to show two cases that used a two-plan loop (T-loop modified) for correcting of dental transposition. The cases showed orthodontic treatments of transposition between lateral incisor and canine treated by two-plan loop. The loop modified showed as a good option to correct transposition with minor possibility of periodontal trauma due the horizontal movement with decreased vertical vectors. Only in second phase vertical movements occurred in order to include the canines in the main arch. The correction was satisfactory and it showed as a viable possibility in the orthodontic clinics offering to the patient a movement more safety and controlled in the vertical dimension.

Key words: Orthodontics, Corrective orthodontics, Tooth transposition

Introduction

The transposition is the alteration of the original place of the irruption of the dental element. This alteration can be completed when the crown and root show in the different correct place or incomplete when only the crown is out of its original position, keeping the root correctly in its original place [1]. The incidence of transposition is about 0.4% of all malocclusions [2], similar incidence also found by others authors (0.51%) [3].

The incidence of teeth with transposition in maxillary is bigger, where the minor of the cases shows bilateral incidence [4]. In mandible, the transposition more common is between the canine and the lateral incisor, being rare the transposition between canine and premolar. The biggest incidence of transposition is female gender [5,6]. In 1995, Peck et al. [7] classified the transposition in the following 5 types: canine and premolar (superior), canine and lateral incisor (superior), canine and first molar (superior), lateral and central incisive (inferior); lateral incisive lateral e canine (inferior). The incidence of the transposition is most common in superior arch, as related by Brezniak et al. [8]. Moreover, cases of transposition with inferior canines are uncommon in scientific literature. In 1999, Taner et al. [9] considered the extraction of inferior canine transposed as a therapeutic option.

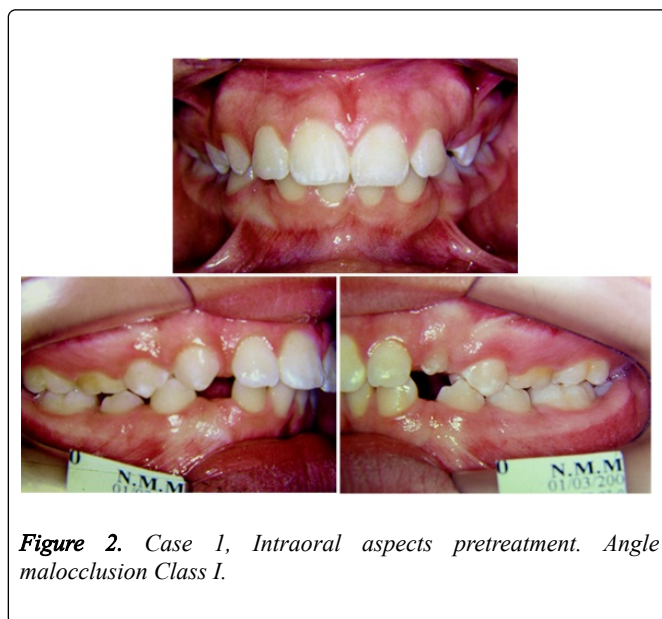
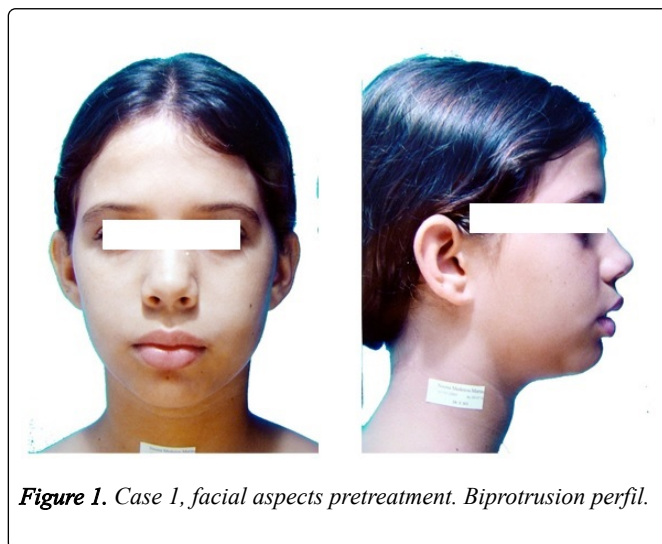
The transposition and its orthodontic correction show as a challenger approach. Although the literature indicates this malocclusion as viable to be treated it is little discussed about different ways to treat this alteration and its limitations associated to convectional mechanics. Thus the aim of the present article is to relate two cases of treatment of dental transposition of the canine with the lateral incisor using a two-plan loop.

Case Presentation

Case 01: Diagnosis and treatment

Brazilian patient, female gender, age 11 years old and 2 months (Figure 1), were attended to Center of Orthodontics Paulo Picanço (Fortaleza, Brazil) for orthodontic evaluation and treatment. The patient shows Angle Class I malocclusion in the final of the mixed dentition (Figure 2). Moreover, the

patient showed deviated midline, bad formation of the right lateral incisor in transposition with the right inferior canine localized in horizontal position next to midline (Figures 2 and 3).



Corresponding author: Dr. Paulo R. B. Picanço, Department of Orthodontics, Paulo Picanço School of Dentistry, Fortaleza-CE, Brazil, Tel: 55 85 982053222; E-mail: paulopicanco@facpp.edu.br

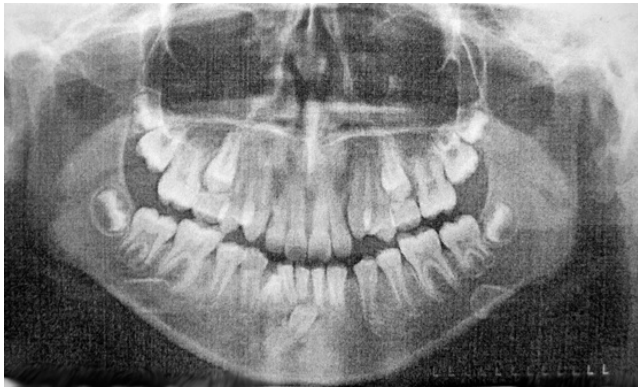


Figure 3. Case 1 - Panoramic radiography of the pretreatment.

Two options of treatment were considered: first the extraction of the teeth 42 and 43 and the maintenance of spaces for future setting of implants. The other option is the extraction of the tooth 42 and traction of the dental element 43 though its favorable situation. The patient was treated with preset Edgewise (American Orthodontics). It was performed access by surgery procedure for the bonding of an attachment in the right inferior canine and it was realized a first traction with steel ligature wire for verticalise the canine. After this step, it was held the confection of a continuous arch with an extensive T-loop modified for keep the movement of the inferior canine in a plan more inferior than others teeth (Figure 4). This loop has as propose to facilitate the pass of the dental element 43 below the teeth avoiding the cervical diameter of the tooth 42 in order to avoid dehiscence in region of dental alveolus. It was used a steel wire 0.014" for confection of the loop in order to avoid resistance in the correction of the canine passing through the teeth. This thickness of wire was chosen for allowing freedom of movement avoiding the radicular resorption.

Evolution of the treatment

During the treatment, it was performed the building of the appliance preset Edgewise slot 0.22×0.25 (American Orthodontics), the right inferior canine was moved for correcting the transposition. The movement of the canine was held in the direction of the midline in the original region of the canine. For this correction of the inferior canine, it was defined the use of a continuous wire with the T-loop for performing the traction of the canine do canine supported in the continuous arch for avoiding the mesialization of the crown in direction to distal force and rotation of the canine during its movement (Figures 4 and 5).

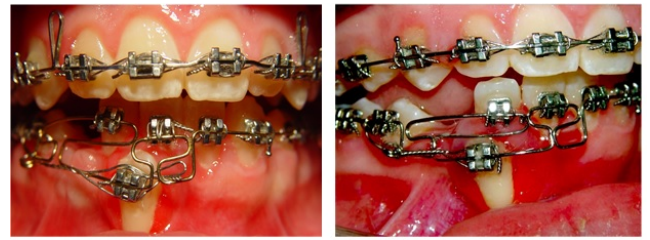


Figure 4. Case 1, mechanics of the two-plans loop.

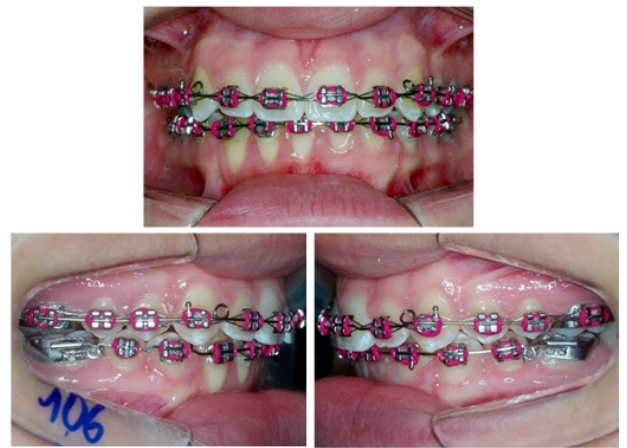

Figure 5. Case 1, aspects of the continuou arch after correction of the canine in its original place.

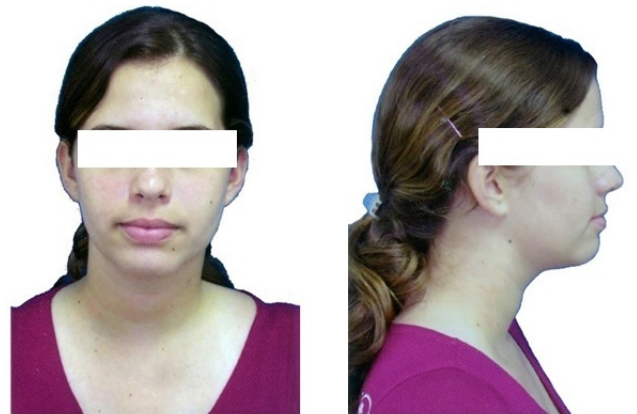

Figure 6. Case 1, posttreatment with good facial aesthetics.

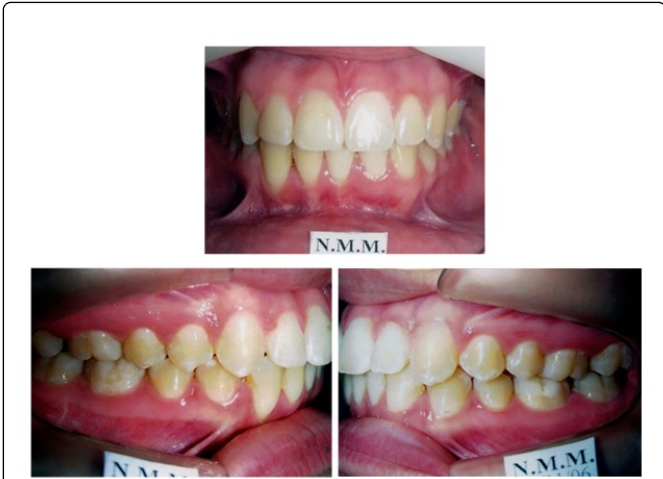

Figure 7. Case 1, after extraction of the 42 (case concluded with 3 inferior incisors).

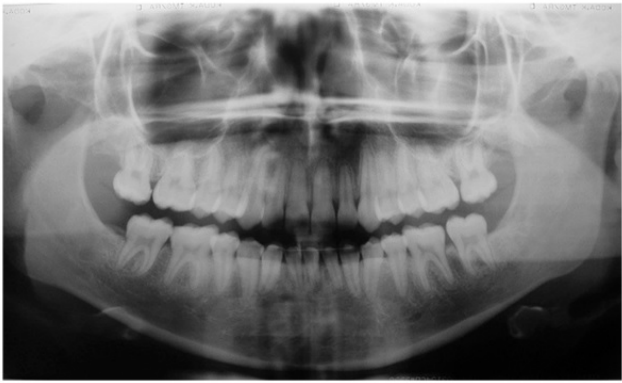

Figure 8. Case 1, final panoramic radiography.

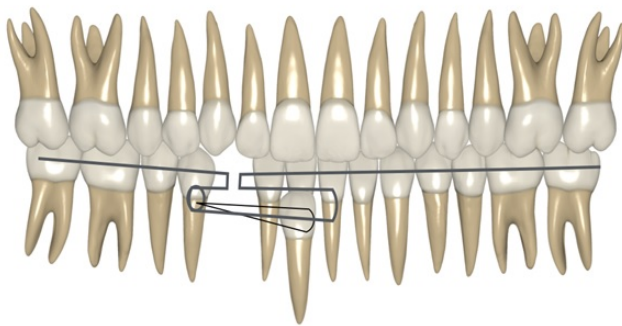


Figure 9. Computational design of the two-plans loop.

After 2 years and 6 months of orthodontic treatment, it was concluded the treatment with corrected occlusal guides, without overjet though of the extraction of the bad formed inferior incisor (Figures 6 and 7) and good cephalometric values. The offer of a minimum recession of the right inferior canine was possible due the incorporation of lingual root torque. The treatment shows a good result though a need of extraction of the inferior lateral incisor. There was a considered improvement in the profile due a verticalization

and intrusion of the molars (Figures 8 and 9). Moreover, the mandible rotated anticlockwise.

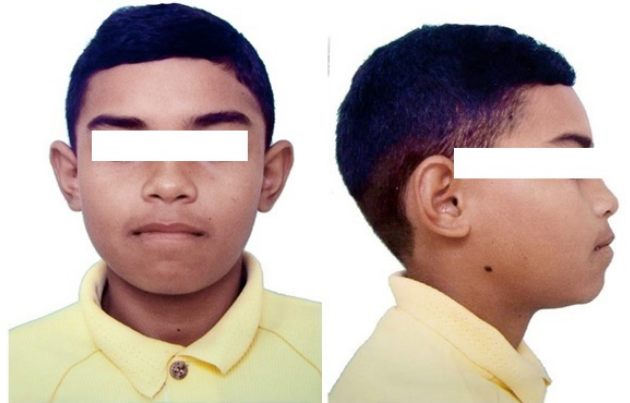

Figure 10. Case 2, facial aspects of the pretreatment.

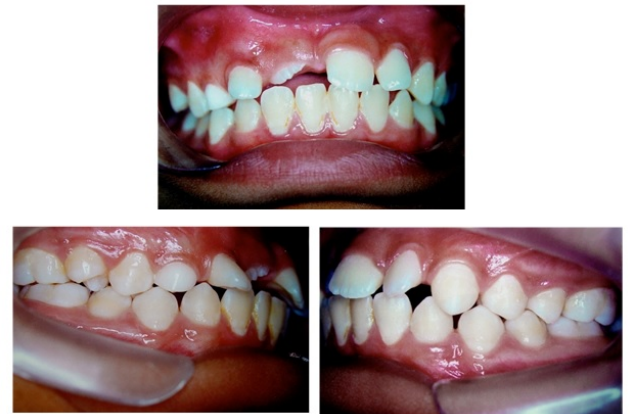

Figure 11. Case 2, angle class I malocclusion, retention of the right superior deciduous canine.

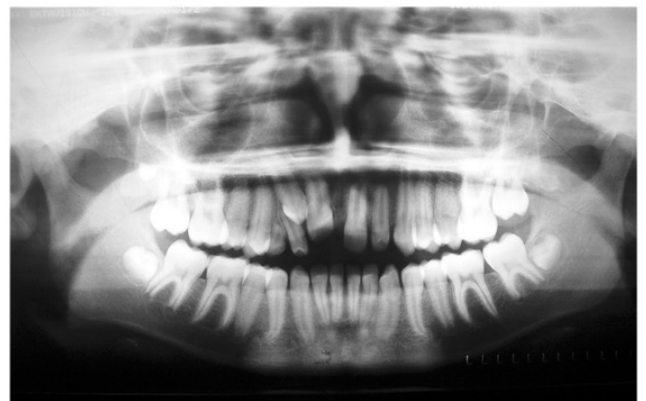

Figure 12. Case 2 – initial panoramic radiography.

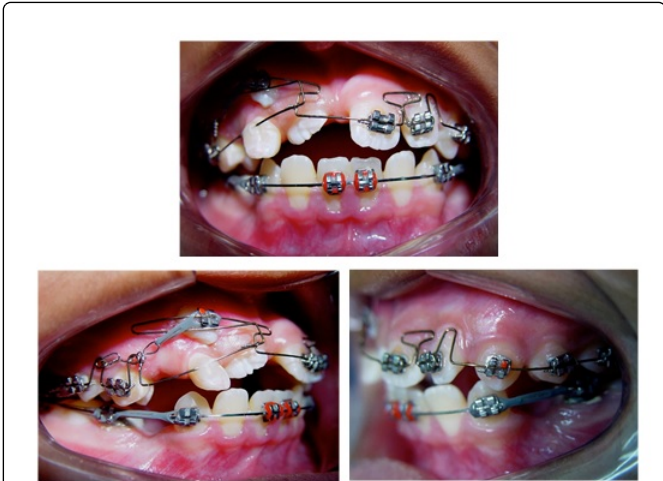


Figure 13. Case 2-use of the two-plans.

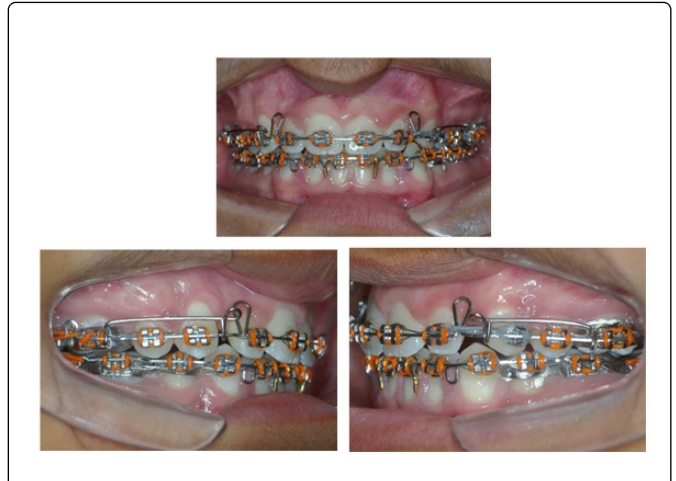


Figure 16. Case 2, intra-oral aspects after the creation of the transposition.

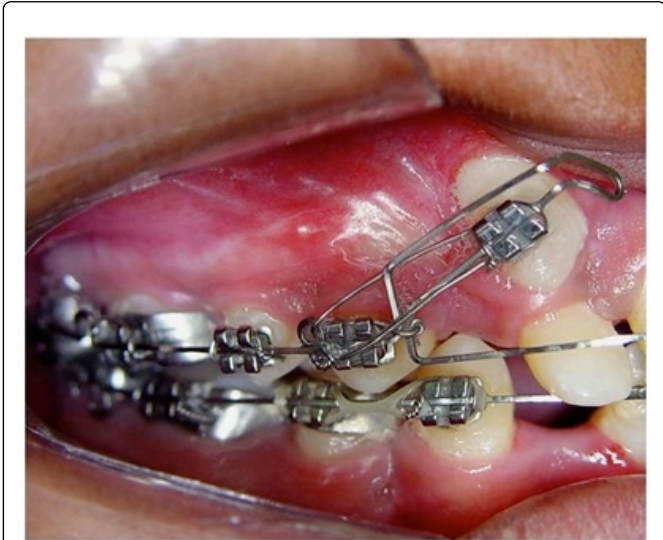


Figure 14. Case 2, two-plans loop for position the canine and finalize the corrections of the transposition.

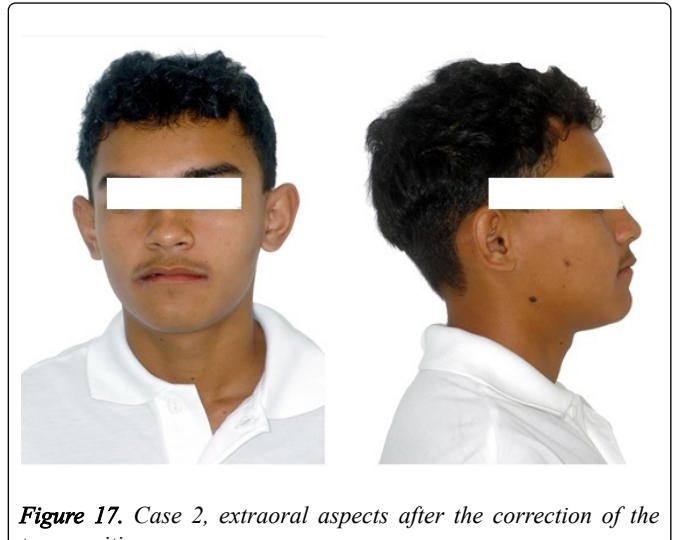


Figure 17. Case 2, extraoral aspects after the correction of the transposition.

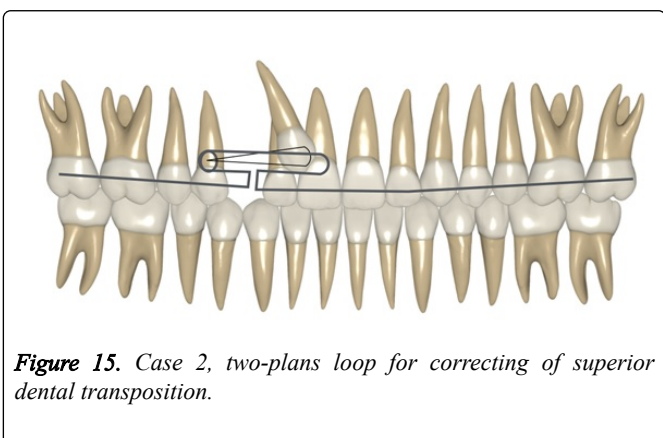


Figure 15. Case 2, two-plans loop for correcting of superior dental transposition.

Case 02: Diagnosis and treatment

The second case is a Brazilian patient, male gender, 12 years and 4 months (Figure 10), Angle malocclusion Class I, in permanent dentition, ported of a incomplete transposition between the right superior lateral incisor and the canine situated by vestibular side (Figures 11 and 12). The patient has indication to perform orthodontic treatment with extraction of 4 due the biprotrusion dento-alveolar. Two options of treatment were chosen: the extraction of the teeth 13, 24, 34 and 44, without correction of the transposition or extraction of the four first-premolars after success of transposition between the teeth 13 and 12 (Figure 13). The patient was treated with the appliance preset Edgewise, Roth (Morelli). It was also performed surgery access for bonding attachment in the transposed tooth. The referred tooth was exposed for being localized in keratinized gingiva.

Evolution of the case

During the orthodontic treatment, it was performed the building of the appliance preset Edgewise, slot 0.22×0.25 (Moreli) (Figures 14 and 15). The two-plan loop was realized with the steel wire 0.014” to start the movement and it was

evolved until the steel wire 0.020" searching to offer freedom for a movement of root of neighbor teeth.

During the correction of the right superior canine, the right superior first premolar was preserved until the assurance of the success of the correction of the transposition (*Figure 16*). The canine was found in region of the inserted gingiva, the bonding of the bracket was held with the opened crown. Besides that it were observed adequate periodontal contour after the correction of the canine.

The phase of the correction of the transposition by the two-plans was finalized and it showed satisfactory (*Figures 16 and 17*). In case of transposed canine is more anterior to the arch of two-plan and it was necessary to make a curve in order to adequate a loop to the anatomy of the case (*Figure 15*). The extraction of 4 first molars only was performed after the success of the transposition. It was used two Bull loops targeting to close spaces in the arch. After these photos, the patient did not return to the orthodontic attendance in the cited center due change of habitational city. By the other hand the transposition was corrected.

Discussion

Teeth transposition is a complex and challenger malocclusion in Orthodontics, being considered complete when crown and root are found transposed or incomplete when the crown is transposed and the root is observed not transposed [10-12]. The present manuscript related therapeutic orthodontic treatment for cases of incomplete transposition in which the canine and lateral incisors were transposed. The occurrence of unilateral transposition is higher than bilateral [13,14], as observed in the cases depicted. Furthermore, the transpositions were encountered one in superior arch and the other in the inferior arch. Nevertheless, most cases of transpositions are located in upper arch, once literature demonstrated twenty times higher incidence of transposition in upper than in lower arch.

The handling of dental transposition requires a complex biomechanics, most often quoted in literature solved by the segmented arch technique [13-16]. The orthodontic mechanic employed in the present cases was a two-plan loop with a modified T-loop targeting first the treatment of horizontal plan transposition, preventing the teeth to move vertically in dental region. A second step (without loop) was undertaken extruding the teeth for the proper insertion in the arch. One conventional T-loop was already cited as a treatment option for adjustment of transposition [14]. The main difference of the loop proposed in the present investigation is the likelihood to avoid distalization force coming from further dental element or external device. Indeed, the curvature of the two-plan loop might work as anchoring for the attachment which will distalize the tooth in first step. Other authors reported the advantages of transposition correction in a continuous arch [17].

A recent investigation advocated the extraction of transposed canines, when they are next to neighboring teeth or when too misplaced [18]. However, specifically in the Case 1, it was not a feasible alternative, once right lower lateral incisor was previously extracted due to crown and radicular malformation which impaired the aesthetic prognosis of the

patient. In Case 2, the patient presented incomplete transposition between right upper canine and right upper lateral incisor. The canine of second report was initially positioned in inserted gingiva and, thus, was treated without torque control. According to Ileri et al. [10], the orthodontic treatments realized without tooth extraction resulted in a favourable final condition. The increase in inclination of lower incisors towards buccal direction was reported by Kokich [11] in cases with extraction of lower incisor, which was not needed in the present Case 2.

The middle line deviation observed before the correction in Case 1 was explained by the position of right lower lateral incisor and canine in transposition nearby middle line. The option to undertake the extraction of element 42 could aid to correct the middle line deviation and avoid the need for an implant thereof. Most complex factor in Case 1 was to maintain the position of canine during the correction of transposition, as the tooth should not move upwards before the right time as well as should move straight without turning to side directions. This required an inclination of the loop to avoid such condition. The patient had the option to undergo right upper canine extraction rather than extraction of right upper first premolar, but, in order to keep the function of canine, it was decided to correct transposition of canine and extract first premolar.

During transposition correction, the tooth was subjected to orthodontic traction through the oral mucosa favouring gingival recession, but the application of lingual torque of root controlled the recession during finalization phase. A striking risk exists during orthodontic traction, as transposed canine lacks a guide for movement. In the case of two-plan loop, horizontal guide is characterized in first plan by the referring loop. This guide plays a fundamental role in avoiding incorrect movement of root towards neighbour teeth, which is pointed out as one of the main reasons for periodontal sequels [14]. The prognosis of inserted gingiva at the end of orthodontic traction possesses direct correlation with traction mechanics according to Kokich [9].

The canines positioned in inserted gingiva or in palate might be pulled in open way, without the risk for periodontal negative effects at the end of the treatment. Canine localized in keratinized gingiva when pulled in open way might bring some gingiva together [18-20]. In such cases, the pulling should be in closed way. In the case reported, due to transposition, the traction was undertaken in open way, as it was not the case of a simple traction, but rather a correction of a transposition. Aiming to avoid the gingival recession condition, it was realized the positive torque in lower canine in order to diminish inevitable recession [19-22]. Morris et al. [18] concluded that orthodontic treatment is not an important issue for the development of gingival recession, there was no correlation between buccalization of incisors and higher incidence of gingival recession.

Conclusion

The two-plan arch strategy herein demonstrated to be a suitable and efficient solution for the treatment of dental transposition in both cases reported. It is indispensable for the orthodontist to have knowledge of different techniques in

order to optimize the practice and offers biomechanics with minor negative effects.

References

- Babacan H, Kilic B, Bicakci A. Maxillary canine-first premolar transposition in the permanent dentition. *Angle Orthodontics*. 2008; **78**: 954-60.
- Demir A, Basciftci FA, Gelgor IE, Karaman AI. Maxillary canine transposition. *Journal of Clinical Orthodontics*. 2002; **36**: 35-37.
- Burnett SE. Prevalence of maxillary canine-first premolar transposition in a composite African sample. *Angle Orthodontics*. 1999; **69**: 187-189.
- Chattopadhyay A, Srinivas K. Transposition of teeth and genetic etiology. *Angle Orthodontics*. 1996; **66**: 147-152.
- Shapira Y, Kufinec MM. Orthodontic management of mandibular canine-incisor transposition. *American Journal of Orthodontics*. 1983; **83**: 271-276.
- Peck L, Peck S, Attia Y. Maxillary canine-first premolar transposition, associated dental anomalies and genetic basis. *Angle Orthodontics*. 1993; **63**: 99-109.
- Peck S, Peck L. Classification of maxillary tooth transpositions. *American Journal of Orthodontics and Dentofacial Orthopedics*. 1995; **107**: 505-517.
- Brezniak N, Ben-Yehuda A, Shapira Y. Unusual mandibular canine transposition: a case report. *American Journal of Orthodontics and Dentofacial Orthopedics*. 1993; **104**: 91-94.
- Taner T, Uzamis M. Orthodontic management of mandibular lateral incisor-canine transpositions: reports of cases. *ASDC Journal of Dentistry for Children*. 1999; **66**: 110-115.
- Ileri Z, Basciftci FA, Malkoc S, Ramoglu SI. Comparison of the outcomes of the lower incisor extraction, premolar extraction and non-extraction treatments. *European Journal of Orthodontics*. 2012; **34**: 681-685.
- Kokich VO Jr. Treatment of a Class I malocclusion with a carious mandibular incisor and no Bolton discrepancy. *American Journal of Orthodontics and Dentofacial Orthopedics*. 2000; **118**: 107-113.
- Weeks EC, Power SM. The presentations and management of transposed teeth. *British Dental Journal*. 1996; **181**: 421-424.
- Cavuoti S, Matarese G, Isola G, Abdolreza J, Femiano F, et al. Combined orthodontic-surgical management of a transmigrated mandibular canine. *Angle Orthodontics*. 2016; **86**: 681-691.
- Hsu YL, Chang CH, Roberts WE. Canine-lateral incisor transposition: Controlling root resorption with a bone-anchored T-loop retraction. *American Journal of Orthodontics and Dentofacial Orthopedics*. 2016; **150**: 1039-1050.
- Janakiraman N, Vaziri H, Safavi K, Nanda R, Uribe F. Management of severely impacted mandibular canines and congenitally missing mandibular premolars with protraction of autotransplanted maxillary premolar. *American Journal of Orthodontics and Dentofacial Orthopedics*. 2016; **150**: 339-351.
- Lorente T, Lorente C, Murray PG, Lorente P. Surgical and orthodontic management of maxillary canine-lateral incisor transpositions. *American Journal of Orthodontics and Dentofacial Orthopedics*. 2016; **150**: 876-885.
- de Oliveira Ruellas AC, de Oliveira AM, Pithon MM. Transposition of a canine to the extraction site of a dilacerated maxillary central incisor. *American Journal of Orthodontics and Dentofacial Orthopedics*. 2009; **135**: S133-139.
- Morris JW, Campbell PM, Tadlock LP, Boley J, Buschang PH. Prevalence of gingival recession after orthodontic tooth movements. *American Journal of Orthodontics and Dentofacial Orthopedics*. 2017; **151**: 851-859.
- Fu PS, Wang JC, Wu YM, Huang TK, Chen WC, et al. Unilaterally impacted maxillary central incisor and canine with ipsilateral transposed canine-lateral incisor. *Angle Orthodontics*. 2013; **83**: 920-926.
- Kokich VG. Surgical and orthodontic management of impacted maxillary canines. *American Journal of Orthodontics and Dentofacial Orthopedics*. 2004; **126**: 278-283.
- Mupparapu M. Patterns of intra-osseous transmigration and ectopic eruption of mandibular canines: review of literature and report of nine additional cases. *Dentomaxillofacial Radiology*. 2002; **31**: 355-360.
- Schmidt AD, Kokich VG. Periodontal response to early uncovering, autonomous eruption, and orthodontic alignment of palatally impacted maxillary canines. *American Journal of Orthodontics and Dentofacial Orthopedics*. 2007; **131**: 449-455.