

Electroanatomical Mapping Systems and Cardiac Arrhythmias: Avoiding Radiations in Pediatric Patients

Matteo Casale^{1*}, Maurizio Mezzetti², Viviana Tulino³, Marco Morelli², Iacopo Ciccarelli², Simone Maffei², Andrea Giovagnoli², Paolo Busacca² and Giuseppe Dattilo¹

¹Department of Clinical and Experimental Medicine, University of Messina, Italy

²Operative Unit of UTIC and Cardiology, Hospital S. Maria della Misericordia, Asur AV 1 Marche, Urbino, Italy

³Neonatal Intensive Care Unit, Hospital "Barone Romeo", Patti, ASP 2 Messina, Italy

Abstract

Introduction: Cardiac arrhythmias are challenging conditions in pediatric patients, especially in the case of newborns. Most of the tachyarrhythmias in children (90.24%) are atrioventricular reentrant tachycardias (AVRT) and atrioventricular nodal reentrant tachycardias (AVNRT). Although the standard 12-lead ECG maintains high diagnostic value, an invasive electrophysiological study with catheter ablation are often required. Unfortunately these procedures are burdened by the use of radiations.

Materials and methods: We performed a systematic research in PubMed and Embase. We found 257 articles of interest but we selected only 36 as the most representative.

Discussion: The main concerns linked to electrophysiological procedures are the need of fluoroscopy and thus the risk of malignancy as well as dermatitis, cataracts, thyroid diseases and birth defects in the patients' offspring. Children and especially newborns have a greater life expectancy so their cumulative risk is greater than adults. For this reason the guiding principle in electrophysiological procedures involving radiations in pediatric subjects is "as low as reasonably achievable" (acronym: ALARA). The development of 3-dimensional (3-D) electroanatomical mapping systems allowed a significant reduction of radiation exposure during catheter ablations. The most recent experiences demonstrated the feasibility and the safety of fluoroless ablation procedures of the most common arrhythmias in children.

Conclusions: Cardiac arrhythmias could be very challenging conditions in pediatric patients. Predictors of complications are body weight <15 kg and age <4 years so it is clear that newborns are the most difficult patients. It is reasonable, because of these evidences, to approach cardiac arrhythmias pharmacologically in younger subjects. More than 20 years of experiences conducted by the electrophysiologists allow us to encourage the use of the electroanatomical mapping systems, with the objective of reducing the radiation exposure in children, especially when accessory pathways are involved.

Keywords: Cardiac arrhythmias; Electrophysiological study; Electroanatomical mapping; Catheter ablation; Radiation exposure; Arrhythmias in children

Introduction

Cardiac arrhythmias in children are challenging conditions [1]. They are especially common in patients admitted in pediatric intensive care unit, with an incidence of 19%. Between them tachyarrhythmias occur more rarely, with an incidence of 2% [2]. Their incidence is greater in children older than 1 year and in patients with grown-up congenital heart diseases [3]. Between all arrhythmias the supraventricular tachycardias are the most common in the newborn [4]. Some of their pathophysiological substrates are related to the electrophysiological properties of pluripotent stem cell-derived cardiomyocytes [5]. However the molecular, functional and morphological features of the myocardium are all involved in arrhythmogenesis [6-9]. Atrial fibrillation and atrial flutter seem to be the less frequent, being almost always associated with specific and reversible conditions or to Fontan's surgical correction of univentricular heart or congenital heart diseases involving atrial dilatation [10]. The most frequent tachyarrhythmias are the atrioventricular reentrant tachycardias (AVRT) and atrioventricular nodal reentrant tachycardias (AVNRT), reported in the 90.24% of the cases [3]. Both are due to an anatomically determined circuit. AVRT is due to a muscular bypass tract (or accessory pathway) in the atrioventricular groove which can be anywhere along the mitral and tricuspid annulus (with the exception of the region between the right and left fibrous trigones). It connects an atrium with the ventricle so that the impulse arising from sinus node reaches the ventricle and

depolarizes part of it (pre-excitation) bypassing the normal pathway of the atrioventricular node (AVN). In certain circumstances (linked to the refractory periods of the structures involved) an impulse is conducted only by the AVN to the ventricle and from here returns to the atrium by the accessory pathway, originating an AVRT (the so called Wolff-Parkinson White syndrome) [1-3]. AVNRT is due to the presence of two pathways in the context of the AVN: a fast pathway and a slow pathway. This situation creates conditions for an impulse to go through one of the two pathways and to return up by the second one: the circuit is totally in the AVN and both atria and ventricles are activated in parallel [1-3]. Although the standard 12-lead ECG maintains high diagnostic value as first line tool [11], a more invasive approach is often required in order to solve definitively both the diagnostic process and the recurrences [12]. It involves electrophysiological testing, mapping and catheter ablation

***Corresponding author:** Casale Matteo, Department of Clinical and Experimental Medicine, Section of Cardiology, University of Messina, Via Consolare Valeria n.1, Azienda Ospedaliera Universitaria "G. Martino", 98125 Messina, Italy, E-mail: mat.casale@gmail.com

Received January 04, 2017; **Accepted** January 19, 2017; **Published** January 25, 2017

Citation: Casale M, Mezzetti M, Tulino V, Morelli M, Ciccarelli I, et al. (2017) Electroanatomical Mapping Systems and Cardiac Arrhythmias: Avoiding Radiations in Pediatric Patients. J Neonatal Biol 6: 245. doi:10.4172/2167-0897.1000245

Copyright: © 2017 Casale M, et al. This is an open-access article distributed under the terms of the Creative Commons Attribution License, which permits unrestricted use, distribution, and reproduction in any medium, provided the original author and source are credited.

of the arrhythmia [13]. These tools proved to be safe and effective both in children and in adults with congenital heart diseases [14,15]. Furthermore particularly complex procedures, involving the puncture of the interatrial septum, were reported to be safe in children [16]. Unfortunately catheter ablation of cardiac arrhythmias is burdened by the use of radiations. A study conducted in 2008 estimated that a single ablation procedure carried out an increase of fatal malignancy risk in lifetime of the 0.02% with a mean fluoroscopy time of 14.4 min [17]. Considering that supraventricular tachycardias are most often nonfatal diseases it seems difficult to justify even a small risk [18], especially in children where the degree of the cellular turnover is higher. In addition it is well known the risk of dermatitis, cataracts, thyroid disease and birth defects in the patients' offspring [19]. On these bases several non-fluoroscopic mapping systems already used in electrophysiological studies in adults have been investigated in terms of feasibility and safety in children [18,19].

Materials and Methods

We performed a systematic research in PubMed and Embase using the keywords 'arrhythmias', 'arrhythmias in newborn', 'arrhythmias in children', 'electrophysiological study', 'electroanatomical mapping', 'catheter ablation', 'radiation exposure', 'non-fluoroscopic cardiac ablation', 'congenital heart diseases'. We found 257 articles of interest but we selected only 36 as the most representative. Inclusion criteria were: a) adherence of at least two key words; b) publication in 2016 or, at least, between 2013 and 2015; c) epidemiological relevance; d) clinical impact. The main exclusion criteria were an adherence at less than two key words, a publication date before 2013 and information overlapping with numbers smaller in comparison to larger trials. These criteria were adopted in combination in order to highlight the most recent advances in this field. In particular the most part of the literature included (15 articles) represents the "state of art" in the 2016 both in terms of epidemiological and clinical relevance (Table 1 and Figure 1). Some of the exceptions are represented by the large epidemiological and clinical studies with high clinical relevance, which were included. Furthermore all the included studies published before 2013 provide consolidated information that, to date, have not changed (Figure 2).

Discussion

Catheter ablation as a treatment for supraventricular tachycardias in children became available in 1990. The Pediatric Radiofrequency Catheter Ablation Registry, developed in order to demonstrate the efficacy and safety of radiofrequency ablation (RFA) on children, is one of the milestones in the literature of electrophysiology. It demonstrated that critical factors in radiofrequency ablation are a body weight and age [20]. A body weight <15 kg is associated with a higher complication rate and an age <4 years is an independent predictor of complications. Furthermore the risk of atrioventricular block was higher in AVNRT compared to AVRT ablation procedures. In 2004 the Prospective Assessment after Pediatric Cardiac Ablation (PAPCA) database further demonstrated the safety and efficacy of RFA in children [21]. In 2000

Year of publication (total 36)	Articles (n)	%
2016	15	42
2015	2	5,5
2014	3	8
2013	2	5,5
Before 2013	14	39

Table 1: Summary of the articles selected, sorted by year of publication with their absolute (n) and percentage (%) number.

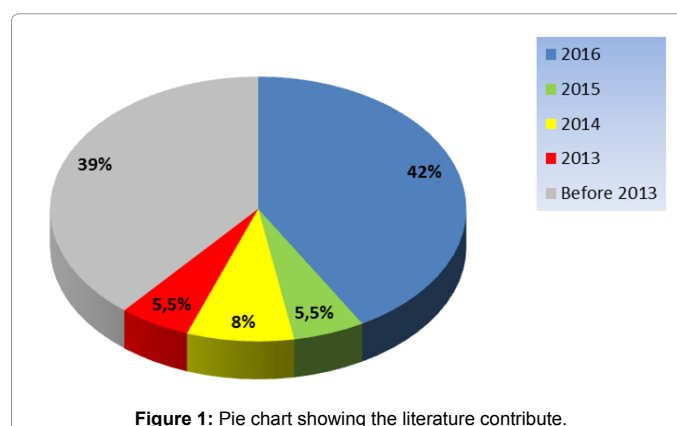


Figure 1: Pie chart showing the literature contribute.

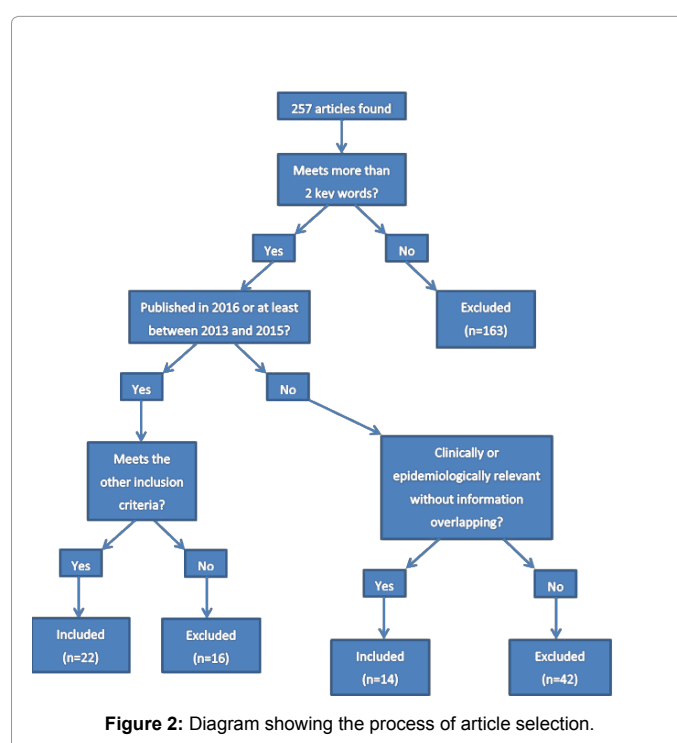


Figure 2: Diagram showing the process of article selection.

a new tool became available: cryoablation [22]. It uses the refrigerant effect of nitrous oxide circulating through the tip of the catheter. The tissue cooling can be stopped if an undesirable effect is seen, allowing the tissue to rewarm before creating a permanent effect. This advance in technology called 'cryomapping' allowed an elimination of the risk of atrioventricular block during AVNRT ablation procedure [23]. These experiences allowed the proper management also in case of extremely young patients [24]. The main concerns linked to these procedures were the need of fluoroscopy and thus the risk of malignancy as well as dermatitis, cataracts, thyroid disease and birth defects in patients' offspring. Children and especially newborns have a greater life expectancy so their cumulative risk is greater than adults [18]. For this reason the guiding principle in electrophysiological procedures involving radiations in pediatric subjects is "as low as reasonably achievable" (acronym: ALARA) [25]. In 2008, Clay et al. estimated that a single ablation procedure with a mean fluoroscopy time of 14.4 minutes carried out an increase of fatal malignancy risk of the 0.02% in lifetime and that the organ with the greatest absorbed dose was

the lung, followed by bone marrow and breast [17]. They concluded that the increased risk of malignancy after a single RFA procedure in children is low. Recently Tomà et al. pointed up that proper balance between risks and benefits is crucial for an optimal outcome and that radiation exposure during radiological exams is minimal, being the risk very small [26]. A review of Gianicolo et al. showed that currently there are methodological limits in the available studies and that accurate risk estimation in adolescents and children undergoing to exposition to ionizing radiations is not well estimated [27]. One of the most recent reviews by Kutanzi et al. highlights the need of minimizing the negative health effects of pediatric exposure to ionizing radiations [28]. On these bases and given that the most frequent arrhythmias in pediatric population are supraventricular tachycardias [3], which are most often not fatal conditions, it seems a reasonable approach a further decrease of radiation exposure [19].

The development of 3-dimensional (3-D) electroanatomical mapping systems allowed a significant reduction of radiation exposure during catheter ablations [18,19,29]. Currently there are two tools available in children: the EnSite system (St. Jude Medical, Inc.) and the CARTO system (Biosense Webster, Inc.). Briefly the EnSite one is based on the measurement of the electrical impedances and the CARTO one on the measurement of magnetic fields deriving from heart (Figure 3). These systems allow a reconstruction of the spatial geometry of the heart's chamber of interest and allow visualization of the ablation catheter in relation to the reconstructed model [18,19,29]. Recently a third system called Rhythmia (Boston Scientific) with highly accurate hybrid tracking, based both on magnetic and impedance technologies, was tested for mapping scar-related atrial tachycardias [30]. However its role in a pediatric population still needs investigation.

In 2013, Scaglione et al. studied the feasibility of a fluoroleless cryoablation in 21 children symptomatic for AVNRT [31]. They combined the advantages of the cryoablation with those ones of the electroanatomical mapping systems. In 19 patients fluoroleless cryoablation was feasible and only in two were needed 45 and 50 seconds of fluoroscopy respectively, because of a difficult progression of the catheters in the venous system. In 2015 the same group conducted another study on 44 children and adolescents affected by AVRT. They showed that an electroanatomical guided ablation of an accessory pathways determining AVRT was feasible both by the way of cryoenergy and of radiofrequency [32]. Another interesting experience of 2016 was conducted by Akdeniz et al. on 35 children affected by idiopathic right ventricular arrhythmias [33]. They demonstrated the efficacy of the electroanatomical mapping in guiding ablations also in challenging arrhythmias such as the ventricular ones, with limited fluoroscopy time. The most recent report of November 2016 by Bigelow et al. was finally conducted on newborns [34]. They reported two cases non-fluoroscopic cardiac ablation on neonates with congenital heart diseases. In one case the newborn was affected by pulmonary atresia and in the second one by Ebstein's anomaly. Both infants were treated successfully minimizing fluoroscopy times. Guided by these evidences we think that electroanatomical mapping systems should be always used in case in pediatric patients, especially in the case of ablation of accessory pathways conditioning atrioventricular reentrant tachycardias. In the case of AVNRT ablation procedures these systems, due to their high costs can be avoidable because of the very limited time of fluoroscopy. In fact the target of an AVNRT is the slow pathway, which is almost always in the postero-inferior aspect of the triangle of Koch [35,36].

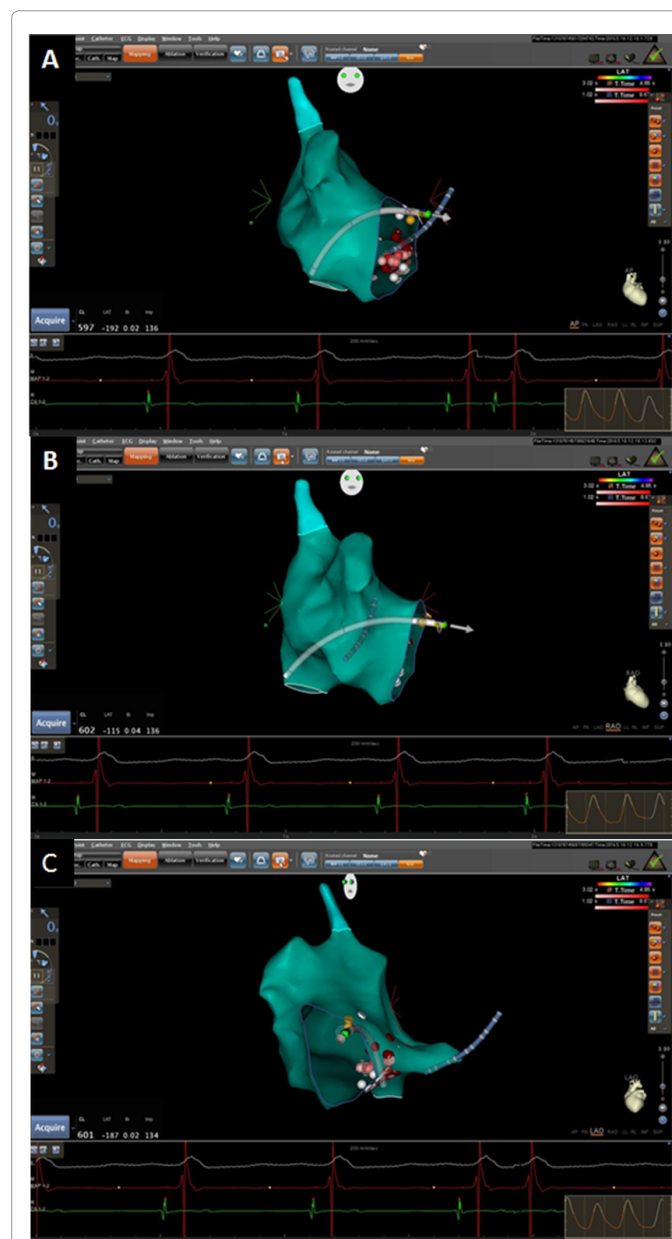


Figure 3: An example of catheter ablation of AVNRT guided by an electroanatomical mapping system. The right atrium was reconstructed in its tridimensional shape and is showed in anteroposterior view (panel A), right anterior oblique (RAO) view (panel B) and left anterior oblique (LAO) view (panel C). During the procedure the image of the chamber of interest can be rotated anyway in order to make the physician aware of the real position of the catheters. The figure shows the ablation catheter (white) in the right atrium and a decapolar catheter positioned in the coronary sinus (blue). Furthermore the system allows visualization of the radiofrequency application points, represented by discs with different colors. Colors are defined before each procedure according to several criteria such as location stability, force over time, impedance drop and temperature. The achievement of the set criteria will result in a color that visually will make the physician aware of the quality of the radiofrequency application.

Conclusion

Cardiac arrhythmias could be challenging conditions, especially if a pediatric patient is involved. Predictors of complications are a body weight <15 kg and an age <4 years so it is clear that newborns are, between the pediatric population, the most difficult patients.

It is reasonable, because of these evidences, to approach cardiac arrhythmias pharmacologically in younger patients [19]. More than 20 years of experiences conducted by the electrophysiologists allow us to encourage the use of the electroanatomical mapping systems in children, with the objective of reducing the radiation exposure, especially if atrioventricular reentrant tachycardias are involved. Currently the progress in the cure of cardiac arrhythmias is following a route that in the future will allow us to overcome the current limitations.

References

- Rivera-Rodríguez L (2009) Diagnosis of tachycardias in pediatric patients. *Arch Cardiol Mex* 79 2: 31-36.
- Cassel-Choudhury GN, Aydin SI, Toedt-Pingel I, Ushay HM, Killinger JS, et al. (2015) Arrhythmias in the paediatric intensive care unit: A prospective study of the rates and predictors of arrhythmias in children without underlying cardiac disease. *Cardiol Young* 25: 1281-1289.
- Hernández-Madrid A, Hocini M, Chen J, Potpara T (2014) Scientific Initiative Committee, European Heart Rhythm Association. How are arrhythmias managed in the paediatric population in Europe? Results of the European Heart Rhythm survey. *Europace* 16: 1852-1856.
- Fuertes Á, Alshweki A, Pérez-Muñuzuri A, Couce ML (2016) Supraventricular tachycardia in newborns and its association with gastroesophageal reflux disease. *An Pediatr (Barc)* 19: 30290-302909.
- Ben-Ari M, Naor S, Zeevi-Levin N, Schick R, Ben Jehuda R, et al. (2016) Developmental changes in electrophysiological characteristics of human-induced pluripotent stem cell-derived cardiomyocytes. *Heart Rhythm* 13: 2379-2387.
- Tanaka H, Matsuyama TA, Takamatsu T (2016) Towards an integrated understanding of cardiac arrhythmogenesis - Growing roles of experimental pathology. *Pathol Int* 67: 8-16.
- Tulino V, Cacace C, Tulino D, Imbalzano E, Dattilo G (2013) Clinical variants in Ebstein's anomaly. *Int J Cardiol* 168: 4969-4970.
- Tulino D, Dattilo G, Tulino V, Marte F, Patané S (2010) A congenital form of junctional ectopic tachycardia. *Int J Cardiol* 145: e54-56.
- Dattilo G, Lamari A, Tulino V, Scarano M, De Luca E, et al. (2012) Congenital valvular heart disease with high familial penetrance. *Recent Prog Med* 103: 581-583.
- Fazio G, Visconti C, D'Angelo L, Novo G, Barbaro G, et al. (2008) Pharmacological therapy in children with atrial fibrillation and atrial flutter. *Curr Pharm Des* 14: 770-775.
- Tipple MA (2000) Usefulness of the electrocardiogram in diagnosing mechanisms of tachycardia. *Pediatr Cardiol* 21: 516-521.
- Voss F, Eckardt L, Busch S, Estner HL, Steven D, et al. (2016) AV-reentrant tachycardia and Wolff-Parkinson-White syndrome: Diagnosis and treatment. *Herzschrittmacherther Elektrophysiol* 27: 381-389.
- Gómez-Flores J, Jacobo-Ruvalcaba A, Márquez MF (2009) Electroanatomic mapping and radiofrequency catheter ablation of focal atrial tachycardias. *Arch Cardiol Mex* 2: 53-57.
- Jiang HE, Li XM, Li YH, Zhang Y, Liu HJ (2016) Efficacy and Safety of Radiofrequency Catheter Ablation of Tachyarrhythmias in 123 Children Under 3 Years of Age. *Pacing Clin Electrophysiol* 39: 792-796.
- Nierras PC, Maranian AP, Wen MS, Chou CC (2016) Radiofrequency Catheter Ablation of Orthodromic Atrioventricular Reentrant Tachycardia in a Child with Congenitally Corrected Transposition of the Great Arteries and Atrial Septal Defect. *Int J Cardiol* 212: 277-279.
- Ehrlinspiel DM, Gass M, Balmer C (2016) Transseptal puncture for radiofrequency catheter ablations of left-sided arrhythmias in a paediatric population. *Cardiol Young* 18: 1-6.
- Clay MA, Campbell RM, Strieper M, Frias PA, Stevens M, et al. (2008) Long-term risk of fatal malignancy following pediatric radiofrequency ablation. *Am J Cardiol* 102: 913-915.
- Papagiannis J, Avramidis D, Alexopoulos C, Kirvassilis G (2011) Radiofrequency ablation of accessory pathways in children and congenital heart disease patients: impact of a nonfluoroscopic navigation system. *Pacing Clin Electrophysiol* 34: 1288-1396.
- Thomas PE, Macicek SL (2016) Catheter Ablation to Treat Supraventricular Arrhythmia in Children and Adults With Congenital Heart Disease: What We Know and Where We Are Going. *Ochsner J* Fall 16: 290-296.
- Kugler JD, Danford DA, Houston KA, Felix G, Pediatric Radiofrequency Ablation Registry of the Pediatric Electrophysiology Society (2002) Pediatric radiofrequency catheter ablation registry success, fluoroscopy time, and complication rate for supraventricular tachycardia. comparison of early and recent eras. *J Cardiovasc Electrophysiol* 13: 336-341.
- Van Hare GF, Javitz H, Carmelli D, Saul JP, Tanel RE, et al. (2004) Prospective assessment after pediatric cardiac ablation. demographics, medical profiles, and initial outcomes. *J Cardiovasc Electrophysiol* 15: 759-770.
- Skanes AC, Dubuc M, Klein GJ, Thibault B, Krahn AD, et al. (2000) Cryothermal ablation of the slow pathway for the elimination of atrioventricular nodal reentrant tachycardia. *Circulation* 102: 2856-2860.
- Kirsh JA, Collins KK, Canon BC, Dubin AM, Fenrich AL, et al. Catheter cryoablation of pediatric AVNRT: are there predictors of success, failure and recurrence?. *Heart Rhythm* 2: S46.
- Kugler JD, Danford DA, Houston K, Felix G (1997) Radiofrequency Catheter Ablation Registry. Radiofrequency catheter ablation for paroxysmal supraventricular tachycardia in children and adolescents without structural heart disease. *Am J Cardiol* 80: 1438-1443.
- Thukral BB (2015) Problems and preferences in pediatric imaging. *Indian J Radiol Imaging* 25: 359-364.
- Tomà P, Cannatà V, Genovese E, Magistrelli A, Granata C (2016) Radiation exposure in diagnostic imaging: wisdom and prudence, but still a lot to understand. *Radiol Med* .
- Gianicolo EA, Pokora R, Krille L, Blettner M (2016) Exposure to ionizing radiation from computed tomography (CT) in childhood and cancer risk. *Epidemiol Prev* 40: 17-19.
- Kutanzi KR, Lumen A, Koturbash I, Miousse IR (2016) Pediatric Exposures to Ionizing Radiation: Carcinogenic Considerations. *Int J Environ Res Public Health* 13: E1057.
- Jan M, Žížek D, Rupar K, Mazic U, Kuhelj D, et al. (2016) Fluoroless catheter ablation of various right and left sided supra-ventricular tachycardias in children and adolescents. *Int J Cardiovasc Imaging* 32: 1609-1616.
- Anter E, McElderry TH, Contreras-Valdes FM, Li J, Tung P, et al. (2016) Evaluation of a novel high-resolution mapping technology for ablation of recurrent scar-related atrial tachycardias. *Heart Rhythm* 13: 2048-2055
- Scaglione M, Ebrille E, Caponi D, Blandino A, Di Donna P, et al. (2013) Single center experience of fluoroless AVNRT ablation guided by electroanatomic reconstruction in children and adolescents. *Pacing Clin Electrophysiol* 36: 1460-1467.
- Scaglione M, Ebrille E, Caponi D, Siboldi A, Bertero G, et al. (2015) Zero-Fluoroscopy Ablation of Accessory Pathways in Children and Adolescents: CARTO3 Electroanatomic Mapping Combined with RF and Cryoenergy. *Pacing Clin Electrophysiol* 38: 675-681.
- Akdeniz C, Gul EE, Celik N, Karacan M, Tuzcu V (2016) Catheter ablation of idiopathic right ventricular arrhythmias in children with limited fluoroscopy. *J Interv Card Electrophysiol* 46: 355-360.
- Bigelow AM, Arnold BS, Padrut GC, Clark JM (2016) Non-fluoroscopic cardiac ablation of neonates with CHD. *Cardiol Young*.
- Gaita F, Riccardi R, Scaglione M, Bocchiardo M, Richiardi E, et al. (1993) Ablation of supraventricular paroxysmal nodal reentrant tachycardia. *Cardiologia* 38: 183-188.
- Wathen M, Natale A, Wolfe K, Yee R, Newman D, et al. (1992) An anatomically guided approach to atrioventricular node slow pathway ablation. *Am J Cardiol* 70: 886-889.