

Effect of Teriparatide and Alendronate on Spinal Fusion in Rats with Glucocorticoid-Induced Osteoporosis

Mohamed El-Sayed Mahmoud*

Department of Medical Pharmacology, Cairo University, Cairo, Egypt

ABSTRACT

Background: Spinal fusion surgery is one of the standard treatments for degenerative and traumatic spine diseases, delayed union or pseudarthrosis of grafting bone after surgery create more serious problems in performing spinal fusion surgery for patients with Glucocorticoid Induced Osteoporosis (GIOP).

Purpose: To elucidate the effect of intermittent administration of TPTD or alendronate on spinal fusion in rats with GIOP.

Study design: An experimental animal study of rats under continuous glucocorticoid (GC) exposure undergoing spinal fusion surgery and administration of TPTD or Alendronate.

Methods: 24 Male albino rats weighing 250-300 g. Six rats were subcutaneously injected with saline per week for 6 weeks before. The other 18 rats were subcutaneously injected with MP five times per week at a dose of 5 mg/kg/d for 6 weeks before surgery. After 6 weeks of MP administration, rats were randomized into three groups before surgery; rats in the control group (CNT group; n6) were given subcutaneous injections of 0.9% saline five times per week for 6 weeks, and rats in the alendronate group (n6) were given subcutaneous injections of 15 mcg/kg/d of alendronate for 6 weeks and rats in the TPTD group (n6) were given subcutaneous injections of 40 mcg/kg/d of TPTD five times per week for 6 weeks. After grouping, all rats were underwent posterolateral spinal fusion (L4-L5) with iliac crest autograft. The following assessments were performed: microstructural analysis of the fusion mass and adjacent vertebrae (L6); fusion assessment, with manual palpation testing; and bone histomorphometrical analysis of the fusion mass.

Results: in the alendronate group and In the TPTD group, values for bone volume and other bone microstructural parameters at the fusion mass increased and peaked 4 weeks after surgery, and these values were significantly greater than those for the control (CNT) group at 4 and 6 weeks after surgery. Fusion assessment showed that fusion rate was higher in the alendronate group and in the TPTD group than in the CNT group (CNT group: 0%, alendronate group 67%; TPTD group: 84%).

Conclusion: Under continuous GC exposure in a rat model of spinal fusion, alendronate or intermittent TPTD administration were stimulating bone formation at the fusion mass and increasing the fusion rate. Intermittent TPTD administration also improved bone microarchitecture of adjacent vertebrae.

Keywords: Teriparatide; Alendronate; Glucocorticoid-induced osteoporosis; Bone graft; Spinal fusion

Correspondence to: Dr. Mahmoud MES, Department of Medical Pharmacology, Cairo University, Cairo, Egypt, Tel: 00201010600357; E-mail: drmohamedalsayed@gmail.com

Received: April 01, 2021; **Accepted:** April 15, 2021; **Published:** April 22, 2021

Citation: Mahmoud MES (2021) Effect of Teriparatide and Alendronate on Spinal Fusion in Rats with Glucocorticoid-Induced Osteoporosis. J Clin Exp Pharmacol. 11:280.

Copyright: © 2021 Mahmoud MES. This is an open-access article distributed under the terms of the Creative Commons Attribution License, which permits unrestricted use, distribution, and reproduction in any medium, provided the original author and source are credited.

INTRODUCTION

Glucocorticoids (GCs) are potent anti-inflammatory and immunosuppressive agents used widely for the treatment of diseases such as asthma, chronic lung disease, rheumatoid arthritis and other connective tissue diseases, inflammatory bowel disease, and neuromuscular disease. However, one of drawback of prolonged GC treatment leads to trabecular bone loss and osteoporosis [1,2]. Prolonged exposure to GCs has the primary effect on decreasing bone formation because of the inhibition of the differentiation, activity, and life span of osteoblasts and osteocytes [3,4]. GCs osteoporosis showed a greater reduction in bone formation at the cellular and tissue levels compared with those with postmenopausal osteoporosis [5].

Spinal fusion surgery is one of the standard treatments for degenerative and traumatic spine diseases. In performing it, surgeons generally use bone grafting to restore mechanical stability to the affected spinal segment by bridging bone between the vertebrae, and successful bony union at unstable spine segments leads to pain relief and neurologic recovery [6-9]. In particular, delayed union or pseudarthrosis of grafting bone, instrumentation failure, and adjacent vertebral fractures after surgery create more serious problems in performing spinal fusion surgery for patients with glucocorticoid-induced osteoporosis (GIOP) [10]. Depending on the pathophysiology of GIOP, pharmacological agents that stimulate bone formation and accelerate bone remodeling may hold the promise of resolving these problems. Intermittent administration of parathyroid hormone (PTH) has a potent stimulatory effect on bone remodeling [11,12]. It has been reported that intermittent administration of teriparatide (TPTD) increases the cortical and cancellous bone mass, improves the microarchitecture of bone, and reduces the risk of osteoporotic vertebral fractures.

Teriparatide has been widely used for the treatment of postmenopausal women and men with severe osteoporosis [13-15]. In addition, several randomized controlled clinical trials have shown the effectiveness of TPTD for treating GIOP, which was superior to that of antiresorptive bisphosphonates [16-18]. Teriparatide induces the maturation of circulating osteoblast precursors and differentiation of lining osteoblasts, stimulates the preexisting osteoblasts to form new bone, and reduces osteoblast and osteocyte apoptosis [19-21]. Over the last decade, bisphosphonates have become the cornerstone of osteoporosis treatment [22]. They are used for treating and preventing osteoporosis and oncological diseases that result in increased bone remodeling [23]. During bone reabsorption, the drug is absorbed by the osteoclasts and causes rupture of the cytoskeleton, loss of the pleated border, inhibition of lysosomal enzymes, loss of reabsorptive activity and death due to apoptosis [24]. Thus, there is a diminution of osteoclastic activity, without direct interference with neoformation activity [25]. Sodium alendronate (ALN) is a second-generation amino-bisphosphonate that is a potent inhibitor of osteoclastic reabsorption [26]. Use of ALN suppresses bone remodeling [27-29] and increases bone mineral density (BMD), thereby contributing toward avoiding vertebral and non-vertebral

fractures. Through using ALN, bone turnover markers present lower levels.

METHODS

Population of study and disease condition

Male albino rats 8 weeks weighing 250-300 g (Purchased from animal house, research institute of ophthalmology, Giza, Egypt) induction of osteoporosis and autograft.

Background and demographic characteristics

Male albino rats weighing 250-300 g, maintained under standard laboratory conditions at 25°C and normal photoperiod (12 hour dark/12 hour light) are used for the experiment.

Chemicals and reagent

- Methylprednisolone (MP) Sodium Succinate for Injection USP was purchased from Pfizer (Egypt) and dissolved in saline to 5 mg/kg
- Alendronate was purchased from Multi-Apex Pharma S.A.E.-Egypt TPTD acetate (Lilly) prefilled pens
- Rat Osteocalcin (OC) ELISA Kits
- Tartrate resistant acid phosphatase type 5b ELISA Kits

Experimental design

Six rats were subcutaneously injected with saline per week for 6 weeks before surgery and were euthanized with anesthetic agents as a baseline group. The other 18 rats were subcutaneously injected with MP five times per week at a dose of 5 mg/kg/d for 6 weeks before surgery. After 6 weeks of MP administration, rats were randomized into three groups before surgery; rats in the control group (CNT group; n6) were given subcutaneous injections of 0.9% saline five times per week for 6 weeks, and rats in the alendronate group (n6) were given subcutaneous injections of 15 mcg/kg/d of alendronate for 6 weeks and rats in the TPTD group (n6) were given subcutaneous injections of 40 mcg/kg/d of TPTD five times per week for 6 weeks. After grouping, all rats were underwent posterolateral spinal fusion (L4-L5) with iliac crest autograft. Saline or alendronate or TPTD injection started just after the surgery and continued for 6 weeks until the animals were euthanized, and MP administration also continued for 6 weeks until the animals were euthanized. All rats were weighed weekly, and the doses of MP Alendronate and TPTD were adjusted accordingly. At 6 weeks after surgery, all rats were euthanized with anesthetic agents (Figures 1-5).

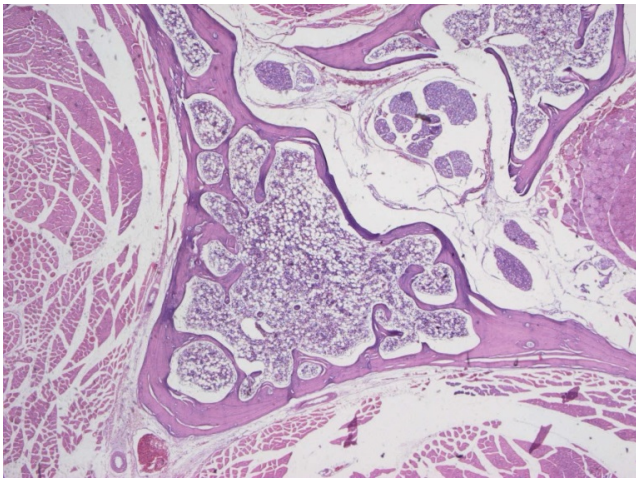


Figure 1: Marked osteoporotic changes.

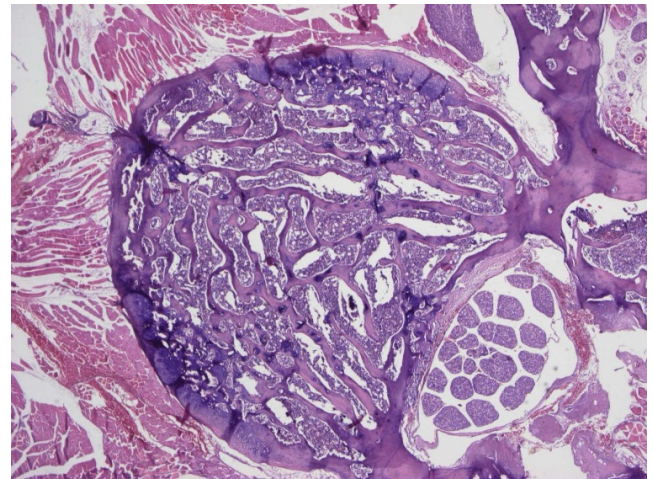


Figure 4: No osteoporotic changes.

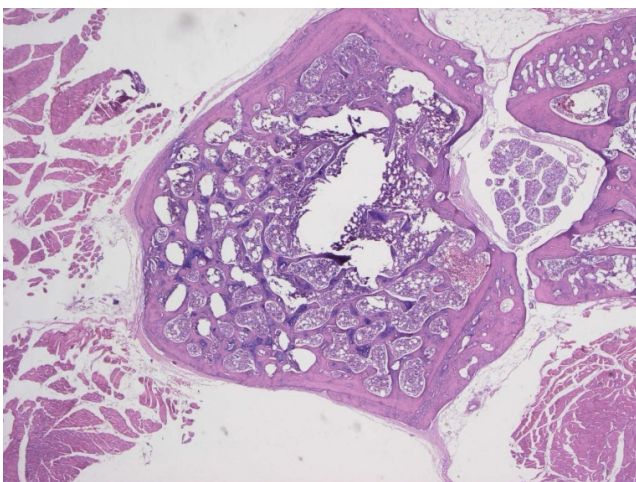


Figure 2: Moderate osteoporotic changes.

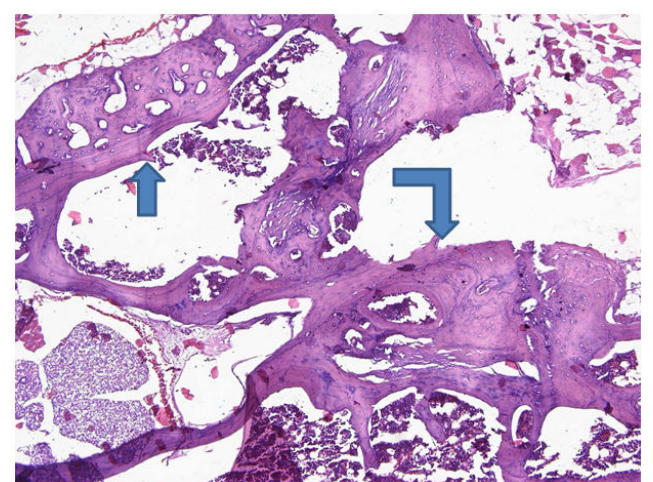


Figure 5: Straight arrow shows pre-existing lamellar bone and bended arrow shows reactive woven bone blending with lamellar bone of the other bony piece (site of fusion).

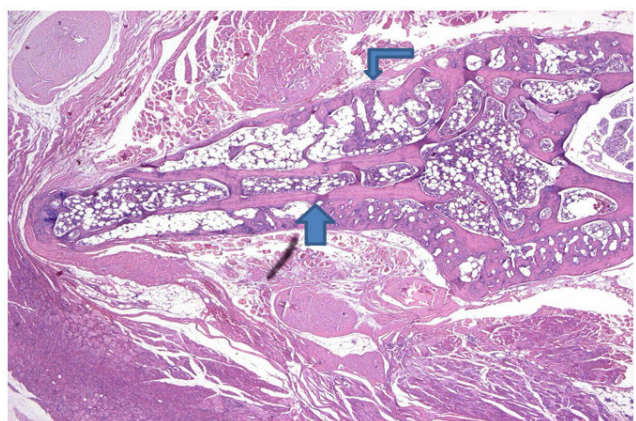


Figure 3: Straight arrow pointing at pre-existing lamellar bone and bended arrow show prominent woven new bone formation site of fusion.

Surgical procedures

Anesthesia was induced by intraperitoneal injection of a cocktail of two drugs: 50 mg/kg of ketamine (Dawaya, Egypt) and 40 mg/kg of propofol (Diprivan, Zeneca) [30,31]. After the surgical field was shaved and preprocessed, rats were placed in a prone position and then L4-L5 posterolateral fusion was [32]. The spine was approached through a single midline skin incision and two paramedian fascial incisions. Spinal level was identified by the iliac crests. After exposure, the transverse process and lateral gutters of the L4 and L5 vertebrae were decorticated until cancellous bone was observed.

Approximately 0.2 g of corticocancellous bone was harvested from each iliac wing. The surgical sites were irrigated, and the harvested graft was placed into the fusion beds. The fascia was closed with 4/0 vicryl sutures and skin was closed with 3-0 prolene sutures. Postoperative antibiotics were given intramuscular for 3 days (Ceftriaxone 50 mg/kg once daily).

Fusion assessment

After the animals were euthanized, the lumbar spines were dissected and fixed with 10% formalin, and non-ligamentous soft tissues were cleaned. The harvested lumbar spines were gently palpated, and lateral side-bending motion at the L4-L5 level was compared with the motion at the adjacent levels above (L3-L4) and below (L5-L6). Manual palpation testing of the L4-L5 segments was performed. Also histological assessment was done.

Serum bone metabolism markers: Blood samples were collected by retro orbital puncture before the animals were euthanized; the samples were stored at 83°C for analyzing serum bone metabolism markers. Osteocalcin (OC), a bone formation marker, and tartrateresistant acid phosphatase type 5b (TRACP-5b), a bone resorption marker, were analyzed using commercially available enzyme-linked immunosorbent assay kits.

Statistical analysis

All collected questionnaires were revised for completeness and consistency. Pre-coded data was entered on the computer using "Microsoft Office Excel Software" program (2010) for windows. Data was then transferred to the Statistical Package of Social Science Software program, version 24 (SPSS) to be statistically analyzed. Data was summarized using mean, and standard deviation for quantitative variables and frequency and percentage for qualitative ones. P values less than 0.05 were considered statistically significant, and less than 0.01 were considered highly significant. Graphs were used to illustrate some information.

RESULTS

Development of glucocorticoid induced osteoporosis in model rats. This study was performed for the period of 3 months and no rats died in the study period. After 5 mg/kg MP administration for 6 weeks, the rats' body weight increased 99.6 ± 10.4 g from the first administration. Bone mineral density at vertebrae adjacent to the surgical site (L6) decreased approximately 20% compared with the baseline groups that were not treated with MP. From these results, we confirmed that GIOP rats were successfully developed as described by Hulley et al. [30].

Fusion assessment: Fusion rate was higher in the TPTD group than in the alendronate group than in the CNT group (CNT, 0/6 [0%]; alendronate 4/6 [67%]; TPTD, 5/6 [84%]).

DISCUSSION

Our study shows that intermittent TPTD administration during continuous GC exposure accelerates the bone modeling and remodeling processes predominantly by stimulating bone formation at the fusion mass, increasing the fusion rate, and improving the bone microarchitecture of vertebrae adjacent to the surgical site in a rat model of spinal fusion [31-33].

Although the mechanism by which TPTD and its analog improve bone healing in GC-treated animals is not completely understood, these agents are considered to suppress osteoblast apoptosis and dysfunction [34,35]. Recently, GC induced suppression in bone formation was described as being the result of upregulation of Wnt/ β -catenin antagonists, such as Dickkopf-related protein 1. TPTD targets osteocytes and reduces the expression of Wnt/ β -catenin antagonists, sclerostin, and Dickkopf-related protein 1 [36]. For patients with GIOP, intermittent TPTD administration is a logical bone anabolic therapy that can cancel the activation of Wnt/ β -catenin antagonists by GCs. In our study, the fusion rate during GC exposure was higher in the alendronate and TPTD groups than in the CNT group. The impairment of bone formation because of prolonged GC exposure may retard the effect of TPTD in spinal fusion. This retardation may be resolved by accelerating the beginning TPTD administration.

Our histologic findings suggest that bone turnover was accelerated in the TPTD group by stimulating bone formation predominantly at the fusion mass [30]. We found that serum OC levels were greater in the TPTD group than in the CNT group [30,32]. We collected blood samples at 6 weeks after surgery, and we believe that the peak of bone formation and resorption occurred before that point. In addition, OC is secreted by differentiated mature osteoblasts and there is a possibility that the number of mature osteoblasts decreased in rats with GIOP [37]. Serum TRACP-5b levels were significantly low in the TPTD group than in the CNT group in our study, and bone resorption was enhanced systemically in the TPTD group.

Bisphosphonates decrease the degree of bone growth but without interfering with the quality of the mechanical resistance of the bone. In other words, ALN enables prevention of resorption, but the bone maintains its normal structural and mechanical characteristics [38]. Bisphosphonates make the bone turnover slower and provide more time for bone structural organization, without impairing or altering the mechanical properties of the tissue rats have a metabolism that is twice as fast as that of humans. This study in agreement with the study of Lawrence et al. reported that intermittent administration of TPTD (20 μ g/kg per day) in a healthy animal model of spinal fusion led to an increased fusion rate [32,39]. Also with the study of Abe et al. reported that intermittent administration of TPTD (40 μ g/kg per day) enhanced bone turnover predominantly by increasing bone formation at the graft site and led to the acceleration of spinal fusion in a rat [30]. Ohtori et al. reported that daily subcutaneous TPTD injection in postmenopausal women with osteoporosis after posterolateral fusion surgery produced better bone union than oral bisphosphonate [40].

They also reported that TPTD treatment reduced the healing time for spinal fusion. However, there have been no studies of the effect of intermittent TPTD administration on the union of grafted bone in spinal fusion surgery of patients with GIOP [41].

CONCLUSION

The intermittent administration of TPTD accelerated the bone modeling and remodeling processes after spinal fusion in a rat model with GIOP by stimulating bone formation predominantly at the fusion mass, increasing the fusion rate, and improving the bone microarchitecture of the vertebrae adjacent to the surgical site. Alendronate also accelerate graft fusion but less than TPTD.

REFERENCES

- Lane NE, Lukert B. The science and therapy of glucocorticoid induced bone loss. *Endocrinol Metab Clin North Am.* 1998;27(2): 465-483.
- Bultink IE, Baden M, Lems WF. Glucocorticoid-induced osteoporosis: an update on current pharmacotherapy and future directions. *Expert Opin Pharmacother.* 2013;14(2):185-197.
- O'Brien CA, Jia D, Plotkin LI, Bellido T, Powers CC, Stewart SA, et al. Glucocorticoid act directly on osteoblasts and osteocytes to induce their apoptosis and reduce bone formation and strength. *Endocrinology.* 2004;145(4):1835-1841.
- Liu Y, Porta A, Peng X, Gengaro K, Cunningham EB, Li H, et al. Prevention of glucocorticoid-induced apoptosis in osteocytes and osteoblasts by carbindin-D28k. *J Bone Miner Res.* 2004;19(3):479-490.
- Dalle Carbonare L, Arlot ME, Chavassieux PM, Roux JP, Portero NR, Meunier PJ. Comparison of trabecular bone microarchitecture and remodeling in glucocorticoid-induced and postmenopausal osteoporosis. *J Bone Miner Res.* 2001;16(1):97-103.
- Bridwell KH, Sedgewick TA, O'Brien MF, Lenke LG, Baldus C. The role of fusion and instrumentation in the treatment of degenerative spondylolisthesis with spinal stenosis. *J Spinal Disord.* 1993;6(6): 461-472.
- McGuire RA, Amundson GM. The use of primary internal fixation in spondylolisthesis. *Spine.* 1993;18(12):1662-1672.
- West JL III, Bradford DS, Ogilvie JW. Results of spinal arthrodesis with pedicle screw-plate fixation. *J Bone Joint Surg Am.* 1991;73:1179-1184.
- Zdeblick TA. A prospective, randomized study of lumbar fusion: preliminary results. *Spine.* 1993;18(8):983-991.
- Ito M, Kaneda K. Osteopenia: vertebrectomy and fusion. In: Herkowitz H, Dvorak J, Bell G, Nordin M, Grob D (eds) *The lumbar spine* (3rd edn), Hagerstown, MD, USA: Lippincott Williams & Wilkins, 2004:683-689.
- Dempster DW, Cosman F, Parisien M, Shen V, Lindsay R. Anabolic actions of parathyroid hormone on bone. *Endocr Rev.* 1993;14(6): 690-709.
- Dempster DW, Cosman F, Kurland ES, Zhou H, Nieves J, Woelfert L, et al. Effects of daily treatment with parathyroid hormone on bone microarchitecture and turnover in patients with osteoporosis: a paired biopsy study. *J Bone Miner Res.* 2001;16(10):1846-1853.
- Finkelstein JS, Klibanski A, Schaefer EH, Hornstein MD, Schiff I, Neer RM. Parathyroid hormone for the prevention of bone loss induced by estrogen deficiency. *N Engl J Med.* 1994;331(24): 1618-1623.
- Lindsay R, Nieves J, Formica C, Henneman E, Woelfert L, Shen V, et al. Randomised controlled study of effect of parathyroid hormone on vertebral-bone mass and fracture incidence among postmenopausal women on oestrogen with osteoporosis. *Lancet.* 1997;350(9077): 550-555.
- Neer RM, Arnaud CD, Zanchetta JR, Prince R, Gaich GA, Reginster JY, et al. Effect of parathyroid hormone (1-34) on fractures and bone mineral density in postmenopausal women with osteoporosis. *N Engl J Med.* 2001;344(19):1434-1441.
- Saag KG, Zanchetta JR, Devogelaer JP, Adler RA, Eastell R, See K, et al. Effects of teriparatide versus alendronate for treating glucocorticoid-induced osteoporosis: thirty-six-month results of a randomized, double-blind, controlled trial. *Arthritis Rheum.* 2009; 60(11):3346-3355.
- Saag KG, Shane E, Boonen S, Marin F, Donley DW, Taylor KA, et al. Teriparatide or alendronate in glucocorticoid-induced osteoporosis. *N Engl J Med.* 2007;357(20):2028-2039.
- Karras D, Stoykov I, Lems WF, Langdahl BL, Ljunggren EO, Barrett A, et al. Effectiveness of teriparatide in postmenopausal women with osteoporosis and glucocorticoid use: 3-year results from the EFOS study. *J Rheumatol.* 2012;39(3):600-609.
- Amelio D'P, Tamone C, Sassi F, Amico D'L, Roato I, Patanè S, et al. Teriparatide increases the maturation of circulating osteoblast precursors. *Osteoporos Int.* 2012;23(4):1245-1253.
- Qin L, Raggatt LJ, Partridge NC. Parathyroid hormone: a double edged sword for bone metabolism. *Trends Endocrinol Metab.* 2004;15(2):60-65.
- Datta NS. Osteoporotic fracture and parathyroid hormone. *World J Orthop.* 2011;2(8):67-74.
- Da Paz LH, De Falco V, Teng NC, Dos Reis LM, Pereira RM, Jorgetti V. Effect of 17beta-estradiol or alendronate on the bone densitometry, bone histomorphometry, and bone metabolism of ovariectomized rats. *Braz J Med Biol Res.* 2001;34(8):1015-1022.
- Fisher A, Martin J, Sriksalanukul W, Davis M. Bisphosphonate use and hip fracture epidemiology: ecologic proof from the contrary. *Clin Interv Aging.* 2010;5(1):355-362.
- Skipitz R, Johansson HR, Ulrich SD, Werner A, Aspenberg P. Effect of alendronate and intermittent parathyroid hormone on implant fixation in ovariectomized rats. *J Orthop Sci.* 2009;14(2):138-143.
- Christopoulou GE, Stavropoulou A, Anastassopoulos G, Panteliou SD, Papadaki E, Karamanos NK, et al. Evaluation of modal damping factor as a diagnostic tool for osteoporosis and its relation with serum osteocalcin and collagen I N-telopeptide for monitoring the efficacy of alendronate in ovariectomized rats. *J Pharm Biomed Anal.* 2006;41(3): 891-897.
- Lindsay R, Silverman SL, Cooper C, Hanley DA, Barton I, Broy SB et al. Risk of new vertebral fracture in the year following a fracture. *JAMA.* 2001;285(3):320-323.
- Azuma Y, Sato H, Oue Y, Okabe K, Ohta T, Tsuchimoto M, et al. Alendronate distributed on bone surfaces inhibits osteoclastic bone resorption in vitro and in experimental hypercalcemia models. *Bone.* 1995;16(2):235-245.
- Iwamoto J, Miyata A, Sato Y, Takeda T, Matsumoto H. Five-year alendronate treatment outcome in older postmenopausal Japanese women with osteoporosis or osteopenia and clinical risk factors for fractures. *Ther Clin Risk Manage.* 2009;5(1):773-779.
- Orwoll E, Ettinger M, Weiss S, Miller P, Kendler D, Graham J, et al. Alendronate for the treatment of osteoporosis in men. *N Engl J Med.* 2000;343(9):604-610.
- Hulley PA, Conradie MM, Langeveldt CR, Hough FS. Glucocorticoid-induced osteoporosis in the rat is prevented by the tyrosine phosphatase inhibitor, sodium orthovanadate. *Bone.* 2002;31:220-229.
- Abe Y, Takahata M, Ito M, Irie K, Abumi K, Minami A. Enhancement of graft bone healing by intermittent administration of human parathyroid hormone (1-34) in a rat spinal arthrodesis model. *Bone.* 2007;41(5):775-785.
- Kawai S, Takagi Y, Kaneko S, Kurosawa T. Effect of three types of mixed anesthetic agents alternate to ketamine in mice. *Exp Anim.* 2011;60(5):481-487.

33. Lawrence JP, Ennis F, White AP, Magit D, Polzhofer G, Drespe I, et al. Effect of daily parathyroid hormone (1-34) on lumbar fusion in a rat model. *Spine J.* 2006;6(4):385-390.
34. Jilka RL, Weinstein RS, Bellido T, Roberson P, Parfitt AM, Manolagas SC. Increased bone formation by prevention of osteoblast apoptosis with parathyroid hormone. *J Clin Invest.* 1999;104(4):439-446.
35. Yao W, Cheng Z, Pham A, Busse C, Zimmermann EA, Ritchie RO, et al. Glucocorticoid-induced bone loss in mice can be reversed by the actions of parathyroid hormone and risedronate on different pathways for bone formation and mineralization. *Arthritis Rheum.* 2008;58(11):3485-3497.
36. Baron R, Hesse E. Update on bone anabolics in osteoporosis treatment: rationale, current status, and perspectives. *J Clin Endocrinol Metab.* 2012;97(2):311-325.
37. Neugebauer BM, Moore MA, Broess M, Gerstenfeld LC, Hauschka PV. Characterization of structural sequences in the chicken osteocalcin gene: expression of osteocalcin by maturing osteoblasts and by hypertrophic chondrocytes in vitro. *J Bone Miner Res.* 1995; 10(1): 157-163.
38. Lepola VT, Kippo K, Hannuniemi R, Lauren L, Virtamo T, Osterman T, et al. Bisphosphonates clodronate and etidronate in the prevention of ovariectomy-induced osteopenia in growing rats. *J Bone Miner Res.* 1996;11(10):1508-1517.
39. Giavaresi G, Fini M, Torricelli P, Martini L, Giardino R. The ovariectomized ewe model in the evaluation of biomaterials for prosthetic devices in spinal fixation. *Int J Artif Organs.* 2001;24(11):814-820.
40. Rodan GA. Alendronate preclinical studies. *J Clin Rheumatol.* 1997;3(2):34-36.
41. Ohtori S, Inoue G, Orita S, Yamauchi K, Eguchi Y, Ochiai N, et al. Teriparatide accelerates lumbar posterolateral fusion in women with postmenopausal osteoporosis: prospective study. *Spine.* 2012;37(23):E1464-E1468.