

## Effect of High Dose of Selenium Nanoparticles on Alimentary Tract in Rodents

Salome Khbulava<sup>1,2\*</sup>, Nino Chichivishvili<sup>1,2</sup>, Naili Shavshishvili<sup>3</sup>, Karen Mulkijanyan<sup>4</sup>, Nodar Khodeli<sup>5</sup>, Mikheil Jangavadze<sup>3</sup>, Zurab Tsagareli<sup>1</sup>, Manana Dgebuadze<sup>1</sup> and Giorgi Phichkhaia<sup>1</sup>

<sup>1</sup>A. Natishvili Institute of Morphology, Tbilisi State University, Tbilisi, Georgia

<sup>2</sup>Teaching University Geomedi, Tbilisi, Georgia

<sup>3</sup>Department of Pathology, Faculty of Medicine, Tbilisi State University, Tbilisi, Georgia

<sup>4</sup>Department of Preclinical Pharmacological Research, I. Kutateladze Institute of Pharmacochimistry, Tbilisi State Medical University, Tbilisi, Georgia

<sup>5</sup>Scientific-Training Center of Experimental Surgery, Tbilisi State University, Tbilisi, Georgia

### Abstract

In recent years, application of nanoparticles in different fields of biomedical research, paves its way. Nanosized drugs are claimed to decrease toxicity and reduce the needed dose. Selenium is one of the essential trace element in the body that exhibits both anti-oxidative and pro-oxidative effects and is of great importance for nourishment and medicine. Like other nanoparticles, selenium nanoparticles (SeNPs) possess some unique mechanical, optical, electrical, biologic and chemical properties as compared with bulk materials. The aim of the study was to evaluate the possible effects of orally consumed high doses of SeNPs on rodents' alimentary tract after single (1000 and 5000 mg/kg) and repeated (500 mg/kg) 90 day administration.

**Keywords:** Selenium nanoparticles; Alimentary tract; Toxicity

### Introduction

An important role of elementary selenium (Se), as a micronutrient is well-known. In nature Se is represented in different forms: selenide, selenite, selenate, and elemental selenium. The latter is water-insoluble and thus is considered biologically inert. Dietary selenium is present as sodium selenite and other selenium-containing organic compounds, such as L-selenomethionine and L-selenocysteine [1].

Se deficiency causes arrhythmias, heart failure, cardiomegaly, cardiomyopathy, thromboemboly, myocardial infarction [2-4]. As well, it decreases protective ability of the body to free radicals [5], including reactive oxygen species (ROS) during oxidative stress. It has been confirmed that selenium can improve the activities of the selenoenzyme such as selenium-dependent glutathione peroxidases (Se-GSH-Px) which act as a function of redox centers and prevent free radicals from damaging cells and tissues. Interest towards the synthesis of selenium nanoparticles (SeNPs) and their bioactivity raised after elemental selenium nanospheres (300 nm) have been found in certain anaerobic bacteria [6].

Recent studies demonstrated the positive impact of selenium nanoparticles (SeNPs) on different organ systems. SeNPs appeared to have antioxidant, antimicrobial, anti-carcinogenic properties [7-9] characterized by good permeability in tissues [9,10] SeNPs show better biocompatibility, bioefficacy, and lower toxicity compared with inorganic and organic selenocompounds [11-13].

The chemopreventive effects of selenium in animals usually occur at 1-3 µg Se/g diet [14], although a dietary selenium toxicity threshold value of 3-4 µg Se/g diet has been proposed [15]. In patients with gut cancer Se supplementation improved the clinical course of general conditions [16]. Several studies describe protective effect of Se against UV light, [17] lead [18], mercury [19-22] and cadmium [22], progression of HIV infection [23], as enhancer of immune system [24,25].

The present study aimed to evaluate the effect of high oral doses of SeNPs suspension single and continuous exposure on rodents' alimentary tract.

### Materials and Methods

#### Preparation of SeNPs

SeNPs were prepared in Tbilisi State University A.Natishvili Institute of Morphology by mechano-sonochemical method. Pure selenium metallic powder (50-80 µm) was grinded in planetary ball mill DECO-PBM-V-0.4L and then additionally treated in ultrasonic homogenizer UZDN-1 U4.2 to bring particle size below 100 nm [26].

#### Characterization of SeNPs

Selenium powder-derived nanoparticles were characterized by JEOL JSM-6510 LV scanning electron microscope, supplied with X-Max N20 detector, Zeiss Ultra 55 scanning electron microscope and JOEL JEM-100SX transmission electron microscope.

#### In vivo animal study

Albino rats (b.w. 250-300 g) were used for the experiment. The rats were housed in groups in plastic cages with stainless-steel grid tops and kept under standard conditions (t 22 ± 2°C, humidity 50%, 12/12 hr. light/dark cycle) with free access to food and water. SeNPs safety was determined in acute oral toxicity and chronic toxicity studies accordingly to OECD guideline for testing of chemicals [27,28].

All studies were conducted in accordance with current international standards (Directive 2010-63-EU on the Protection of Animals Used for Scientific Purposes, 2010 [29]; Guide for the Care and Use of Laboratory Animals, 8<sup>th</sup> edition 2011 [30].

**\*Corresponding author:** Salome Khbulava, A. Natishvili Institute of Morphology, Tbilisi State University, Tbilisi, Georgia, Tel: 995593000993; E-mail: [kubulava.salome@gmail.com](mailto:kubulava.salome@gmail.com)

**Received:** March 29, 2019; **Accepted:** April 15, 2019; **Published:** April 22, 2019

**Citation:** Khbulava S, Chichivishvili N, Shavshishvili N, Mulkijanyan K, Khodeli N, et al. (2019) Effect of High Dose of Selenium Nanoparticles on Alimentary Tract in Rodents. J Nanomed Nanotechnol 10: 531. doi: [10.35248/2157-7439.19.10.531](https://doi.org/10.35248/2157-7439.19.10.531)

**Copyright:** © 2019 Khbulava S, et al. This is an open-access article distributed under the terms of the Creative Commons Attribution License, which permits unrestricted use, distribution, and reproduction in any medium, provided the original author and source are credited.

## SeNPs administration schemes

**Single administration:** 8-12 week 11 albino rats were randomly divided in three groups, 3 rats in each group (1 female and 2 male rat) and 5 rats (1 female and 4 male) for control study. Females were nulliparous and non-pregnant. Test substance was administered in a single dose by gavage using a stomach tube. Animals were fasted for 24 h (with free access to water) prior to dosing.

Group I assigned as control and received single dose normal saline 0.9%.

Groups II and III were given SeNPs suspension single dose 1000 mg/kg and 5000 mg/kg, correspondingly.

Animals were monitored individually after dosing every 30 minutes during the first 4 hours, then every 6 hours during the first 24 hours, and twice a day thereafter, for a total of 7 days. On day 7, the rats were fasted (water ad libitum) overnight and then euthanized with CO<sub>2</sub> at flow rate 5 L/min per cage.

**Repeated administration:** 8-12 week albino rats were randomly divided in two groups, 10 animals in the group. Test SeNPs water suspensions were administered once a day for 90 days as described above.

Group I (control) was given normal saline 0.9%.

Group II was given SeNPs suspension 500 mg/kg for 90 days.

## Histopathological evaluation

An autopsy was performed immediately after the euthanasia. The intestines were harvested, rinsed with normal saline and then fixed in 4% formaldehyde for 48 hours at room temperature. Organs were dehydrated in a graded series of ethanol, embedded in paraffin and sectioned into slices of 5 μm thickness provided by a rotary microtome. Then, sections were deparaffinized, stained with hematoxylin and eosin (H&E) and examined using a bright-field microscope.

## Results

### Estimation of particle size

Pure selenium powder was grinded for 4 hours in planetary ball mill DECO-PBM-V-0.4L and characterized by JEOL JSM-6510 LV scanning

electron microscope, supplied with X-Max N20 detector (Figure 1). Further size reduction was done by ultrasonic irradiation for 20 min and the obtained samples were characterized using Zeiss Ultra 55 scanning electron microscope (Figure 2). Finally, Se-NPs were suspended in deionized water and irradiated for more 20 min. The mean particle size of Se-NPs was <100 nm (TEM JOEL JEM-100SX) (Figure 3).

### Animal study

During the experiments no lethality was detected. None of tested Se-NP formulations caused changes in skin and fur condition, eyes and mucous membranes. There was no difference in defecation rate or feces consistency between control and experimental groups. As well gastric metaplasia or hemorrhage were not detected neither in single nor in multiple SeNPs administration.

Single dose of SeNPs 1000 mg/kg caused destructive changes in intestines. Signs of initial epithelial erosion and desquamation were evident, intense eosinophilia and abundant cellular infiltration was found in cryptae zones. Vascular lumen showed SeNPs as black colored deposits (Figure 4A). Mesenteric vessel lumen showed black-colored masses, more abundantly into the veins, filling the vein lumen completely (Figure 4B).




Figure 1: Selenium powder after 4 hours grinding. JEOL JSM-6510 LV SEM.




Figure 2: Selenium after 20 minutes of ultrasonic irradiation. Zeiss Ultra55 SEM.



Signs of disorganization of mucosa and muscular layers in large intestine were observed after the administration of SeNPs single dose 5000 mg/kg. Specifically, the lesion and lymphoid infiltration of mucosal layer were seen, which is resulted from non-specific tissue reaction on maximally high dosage of SeNPs considered by the protocol [27]. Black-colored deposits of SeNPs were observed in vascular lumen. This substance can be seen in small amount in perivascular tissue areas as well (Figures 5A and 5B).

Morphological study of intestinal tissue after 90 days administration of SeNPs 500 mg/kg revealed well defined plicae and criptae, with parallel alignment of criptae. Epithelium in criptae contained high number of goblet cells, secreting mucus and excreting it into the criptae lumina. All layers were intact, mucosa, lamina propria, submucosa, muscularis mucosae and muscularis externa were well defined, without any notable changes (Figure 6).

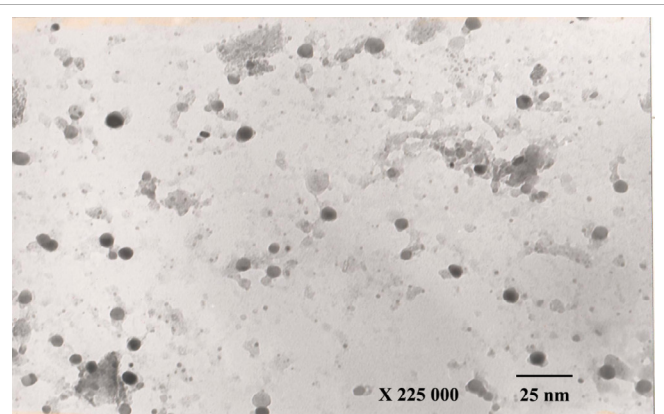


Figure 3: SeNPs after Ultrasonic Irradiation. TEM (JOEL JEM-100SX).

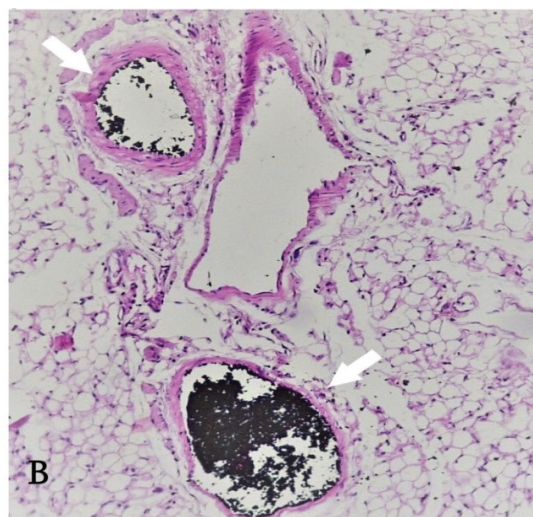
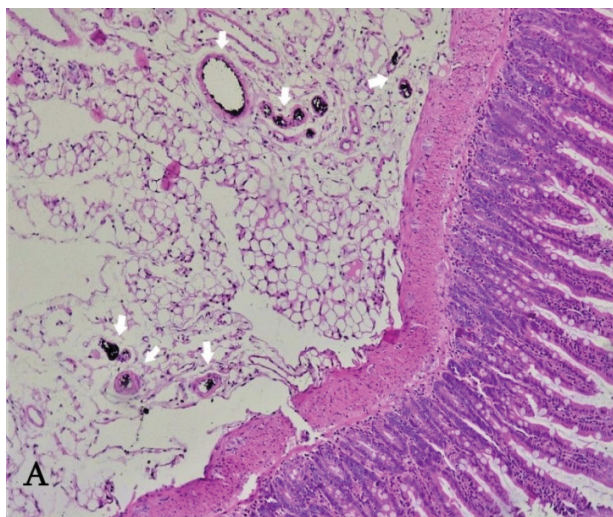


Figure 4: Histopathological effects of SeNPs 1000 mg/kg on rat intestines after single exposure. H&E (A)X100 (B)X200. White arrows - deposits of SeNPs.

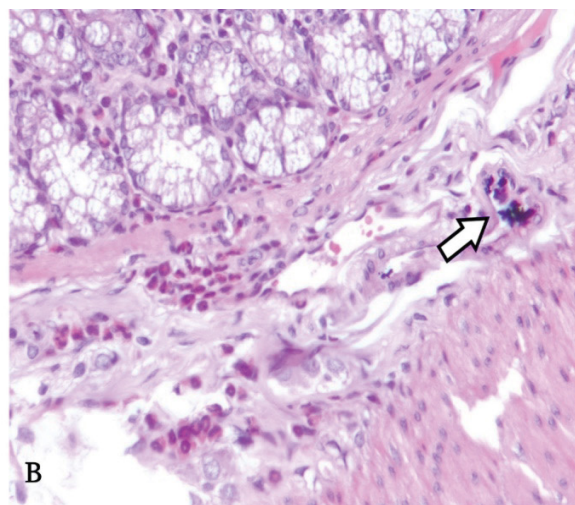
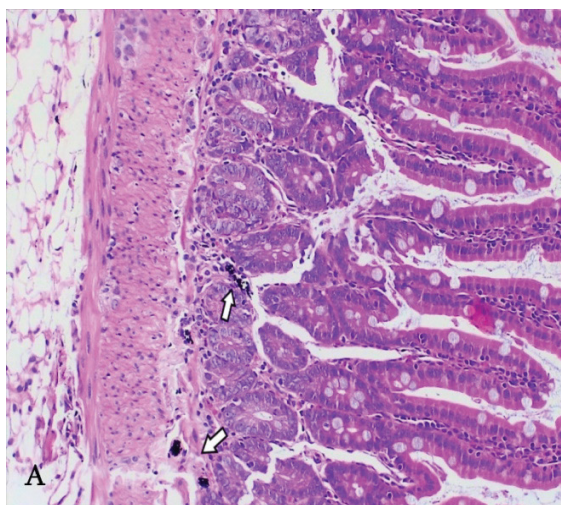
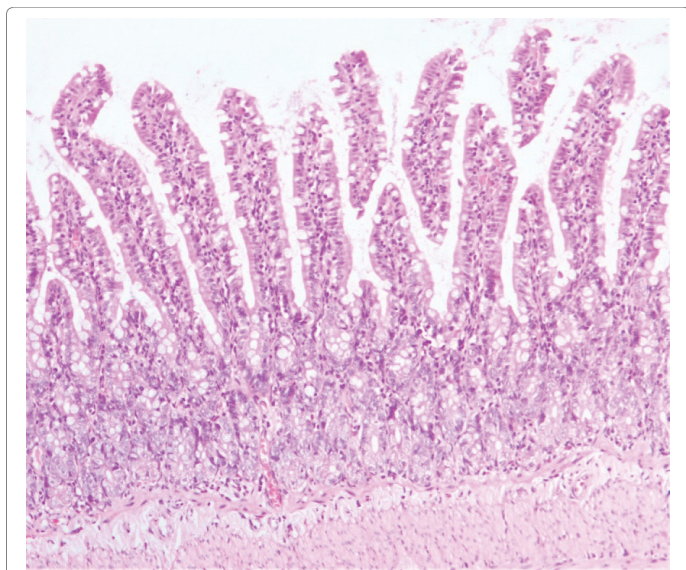


Figure 5: Histopathological effects of SeNPs 5000 mg/kg on rat intestines after single exposure. H&E (A)X200; (B) X400. White arrows (deposits of SeNPs).





**Figure 6:** Histopathological effects of SeNPs 500 mg/kg on rat intestines after continuous (90 days) exposure. H&E, X200.

## Discussion and Conclusion

Neither single (5000 mg/kg) nor repeated (500 mg/kg) oral administration of SeNPs causes no lethality. Histopathological evaluation of rodents' alimentary tract after oral administration of high doses of SeNPs shows that toxicity of SeNPs is dose and time depended. SeNPs appeared to be much less toxic during the multiple (90 days) exposure in comparison to single exposure.

The study revealed that the repeated administration of SeNPs at supranutritional level does not cause gastric metaplasia and hemorrhage, gastritis or vascular congestion, and disorganization of intestinal structure, as intestinal villi and wall layers remain unchanged.

Thus, it can be suggested that it is possible to vary the supranutritional level of SeNPs suspensions in wide doze interval. This fact can be helpful for the determination of the most effective regimens of treatment by micronutrients.

Further studies are required to clarify the SeNPs toxicity to get a deep insight into its mechanism.

## Acknowledgment

This work was supported by Shota Rustaveli National Science Foundation, call for Ph.D. fellowships. Grant number (PhDF2016\_92).

## References

1. Hatfield DL, Berry MJ, Gladyshev VN (2012) *Selenium Its Molecular Biology and Role in Human Health*. Springer-Verlag New York, USA.
2. Oropeza-Moe M, Wisløff H, Bernhoft A (2014) Selenium Deficiency Associated Porcine and Human Cardiomyopathies. *J Trace Elem Med Biol* 31: 148-156.
3. Aro A, Alfthan G, Varo P (1995) Effects of Supplementation of Fertilizers on Human Selenium Status in Finland. *Analyst* 120: 841-843.
4. Lipinski B (2017) Sodium Selenite as an Anticancer Agent. *Anticancer Agents Med Chem* 17: 658-661.
5. Burke MP, Opeskin K (2002) Fulminant Heart Failure due to Selenium Deficiency Cardiomyopathy (Keshan Disease). *Med Sci Law* Pp: 10-13.
6. Dhanjal S, Cameotra SS (2010) Aerobic biogenesis of selenium nanospheres by *Bacillus cereus* isolated from coalmine soil. *Microbial Cell Factories* 9: 52.
7. Wadhvani SA, Shedbalkar UU, Singh R, Chopade BA (2016) Biogenic selenium nanoparticles current status and future prospects. *Appl Microbiol Biotechnol* 100: 2555-2566.
8. Wong K (2014) Preparation of Highly Stable Selenium Nanoparticles with Strong Anti-tumor Activity Using Tiger Milk Mushroom. *Drug Discov and Nutraceutical*.
9. Wang Y, Yan X, Fu L (2013) Effect of selenium nanoparticles with different sizes in primary cultured intestinal epithelial cells of crucian carp, *Carassius auratus gibelio*. *Int J Nanomedicine* 8: 4007-4013.
10. Kuzmin PG, Shafeev GA, Voronov VV, Raspopov RV, Arianova EA, et al. (2012) Bioavailable nanoparticles obtained in laser ablation of a selenium target in water. *Quantum Electron* 42: 1042-1044.
11. Zhang JS, Gao XY, Zhang LD, Bao YP (2001) Biological effects of a nano red elemental selenium. *BioFactors* 15: 27-38.
12. Zhang J, Wang H, Bao Y, Zhang L (2004) Nano red elemental selenium has no size effect in the induction of seleno-enzymes in both cultured cells and mice. *Life Sci* 75: 237-244.
13. Zhang J, Wang H, Yan X, Zhang L (2005) Comparison of short-term toxicity between Nano-Se and selenite in mice. *Life Sci* 76: 1099-1109.
14. Ip C, Ganther HE (1990) Activity of methylated forms of selenium in cancer prevention. *Cancer Res* 50: 1206-1211.
15. Maier KJ, Knight AW (1994) Ecotoxicology of selenium in freshwater systems. *Rev Environ Contam Toxicol* 134: 31-48.
16. Federico A, Iodice P, Federico P, Del Rio A, Mellone M, et al. (2001) Effects of selenium and zinc supplementation on nutritional status in patients with cancer of digestive tract. *Eur J Clin Nutr* 55: 293-297.
17. Rafferty TS, Green MHL, Lowe JE, Arlett C, Hunter JAA, et al. (2003) Effects of selenium compounds on induction of DNA damage by broadband ultraviolet radiation in human keratinocytes. *Br J Dermatol* 148: 1001-1009.
18. Aykin-Burns N, Ercal N (2006) Effects of selenocystine on lead-exposed Chinese hamster ovary (CHO) and PC-12 cells. *Toxicol Appl Pharmacol* 214: 136-143.
19. Lemire M, Mergler D, Fillion M, Passos CJ, Guimarães JR, et al. (2006) Elevated blood selenium levels in the Brazilian Amazon. *Sci Total Environ* 366: 101-111.
20. Kaur P, Evje L, Aschner M, Syversen T (2009) The in vitro effects of selenomethionine on methylmercury-induced neurotoxicity. *Toxicol Vitr* 23: 378-385.
21. Peterson SA, Ralston NV, Peck DV, Van Sickle J, Robertson JD, et al (2009) How Might Selenium Moderate the Toxic Effects of Mercury in Stream Fish of the Western U.S.? *Environ Sci Technol* 43: 3919-3925.
22. Frisk P, Yaqob A, Lindh U (2002) Indications of selenium protection against cadmium toxicity in cultured K-562 cells. *Sci. Total Environ.* 296: 189-197.
23. Hurwitz BE (2007) Suppression of Human Immunodeficiency Virus Type 1 Viral Load with Selenium Supplementation. *Arch Intern Med* 167: 148.
24. Kiremidjian-Schumacher L, Roy M, Wishe HI, Cohen MW, Stotzky G (1994) Supplementation with selenium and human immune cell functions. *Biol Trace Elem Res* 41: 115-127.
25. Valdiglesias V, Pásaro E, Méndez J, Laffon B (2010) In vitro evaluation of selenium genotoxic, cytotoxic, and protective effects: a review. *Arch Toxicol* 84: 337-351.
26. Khubulava S, Chichiveishvili N, Khodeli N, Phichkhaia GM (2018) Preparation of Selenium Nanoparticles with Mechano-sonochemical Methods. *Asian J Pharm* 12.
27. Oecd guideline for testing of chemicals (2002) Acute Oral Toxicity - Acute Toxic Class Method.
28. Oecd guideline for testing of chemicals (2018) Chronic Toxicity Studies.
29. Directive 2010/63/Eu (2010) Legislation for the protection of animals used for scientific purposes. *Off J Eur Union* Pp: 33-79.
30. National Research Council (2011) *Guide for the Care and Use of Laboratory Animals*. (8<sup>th</sup> Edtn) National Academies Press, 500 Fifth Street, NW, Lockbox 285, Washington, DC, USA.