

Diabetic Mastopathy; Case Report and Review of Literature

Shailesh Chaturvedi^{1*}, Justine Downing¹ and Lesley S Carson²

¹Breast Unit, Aberdeen Royal Infirmary, Foresterhill, Aberdeen AB25 2ZN, UK

²Department of Pathology, Aberdeen Royal Infirmary, Foresterhill, Aberdeen AB25 2ZN, UK

Abstract

Two cases of Diabetic Mastopathy presented at our Breast unit over the period of 12 months between June 2003 and June 2004. Both cases were seen in patients with Type 1 Diabetes Mellitus. Triple Assessment (Physical examination, imaging and Fine needle aspiration cytology) did not give a definite diagnosis and hence an excision biopsy had to be performed to achieve the final diagnosis. Case number 1 had all the classical Histological features of Diabetic Mastopathy. These two cases demonstrate importance of core/excision biopsy of suspicious lesions in diabetics before counselling the patient and making final management plan.

Keywords: Diabetic mastopathy; Lymphocytic lobulitis; Breast malignancy

Introduction

Diabetic Mastopathy is a rare condition that presents as a lump in the breast in patients with Type 1 Diabetes. The lump usually has all the features of malignancy on clinical examination. Imaging and Fine Needle Aspiration Cytology (FNAC) fail to provide the diagnosis. Core or excision biopsy is required to reach the definitive diagnosis for this benign condition. This report highlights the diagnostic dilemma for the clinician and anxiety for the patient. Awareness of this condition may help breast surgeon to reassure the patient with possible diagnosis of diabetic mastopathy in presence of normal FNAC report.

Case Study

Case 1

A 30-year-old lady was referred to the symptomatic breast clinic with a history of a left breast lump, increasing in size for 6 weeks. Her past medical history included a 24-year history of Insulin Dependent Diabetes Mellitus, complicated by retinopathy and depression.

Her reproductive history included menarche at fifteen and two deliveries, the first one at 20 years of age. Family history illustrated two maternal aunts who had suffered from breast cancer in their fifties.

On clinical examination this lesion was noted as a tender, irregular hard lump approximately 1cm in diameter, adjacent to areola at the 3 o'clock position in the left breast.

Mammography was not performed in this lady as she was under 35 years of age (Scottish Intercollegiate Guidelines Network), she did however have an Ultrasound Scan. This was scored as indeterminate (U3); "an ill-defined solid nodule, 0.4 cm×0.4 cm×0.3 cm".

In view of the indeterminate nature of the USS report, Fine Needle Aspiration was attempted. Two passes were made, these demonstrated fibro-fatty tissue, with scattered bare nuclei and 1 small group of ductal cells. This was reported as being C1, inadequate for diagnosis. In view of her family history and clinically suspicious lump, patient underwent excision biopsy of the lesion to obtain a definitive diagnosis. Histology demonstrated all the typical diagnostic features of Diabetic Mastopathy (Figures 1 and 2).

Case 2

A 48 year old lady presented to the symptomatic breast clinic with

a nodular lump in the upper and outer quadrant of her right breast. On clinical examination this lesion was a mobile, benign feeling lump, 1.3 cm×0.5 cm in the tail of the right breast.

Mammography demonstrated breasts composed of dense glandular tissue, with an impression of an opacity lying posteriorly on the right oblique view, which disappeared on right oblique coned view. The mammography was scored as suspicious of malignancy (M4) Ultrasound scan revealed a 1.4 cm normal looking lymph node in the axillary tail on the left breast, with no abnormality in the right breast or axilla Fine needle aspiration demonstrated benign cells (C2).

This was her 4th visit to the same clinic. This was recorded as clinically benign lesion in 1993, with a mammogram demonstrating no focal lesion. Ultrasound Scan scored 2 (benign), with an area of fibrocystic disease in the upper aspect of the right breast. No focal area of suspicion was noted. FNA at this time was benign and a diagnosis of

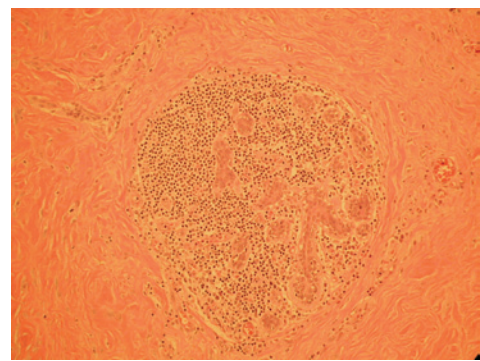


Figure 1: Lymphocytic infiltration of breast lobule (photomicrograph magnification ×200).

***Corresponding author:** Chaturvedi S, Consultant Breast Surgeon & Senior Lecturer in Surgery, Ward 34, Aberdeen Royal Infirmary, Foresterhill, Aberdeen AB25 2ZN, UK, Tel: +44-1224-554466; E-mail: s.chaturvedi@btinternet.com, s.chaturvedi@nhs.net

Received March 05, 2013; Accepted May 27, 2013; Published May 30, 2013

Citation: Chaturvedi S, Downing J, Carson LS (2013) Diabetic Mastopathy; Case Report and Review of Literature. Trop Med Surg 1: 126. doi:10.4172/2329-9088.1000126

Copyright: © 2013 Chaturvedi S, et al. This is an open-access article distributed under the terms of the Creative Commons Attribution License, which permits unrestricted use, distribution, and reproduction in any medium, provided the original author and source are credited.

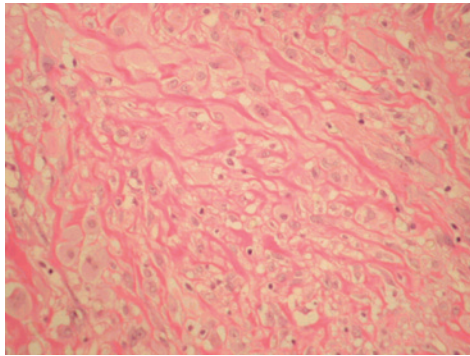


Figure 2: Densely aggregated epithelioid fibroblastic cells amongst collagen fibres (photomicrograph magnification $\times 400$).

fibrocystic disease was established, it was agreed no further intervention was warranted.

Further visits to the symptomatic breast clinic in 1995 and 2000 also demonstrated benign breast disease, confirmed by negative mammography and ultrasound scanning.

This patient had an extensive past medical history including, Insulin Dependent Diabetes Mellitus since childhood, complicated by peripheral neuropathy and retinopathy. This lady also suffered an Anterior Myocardial Infarction in 2002 followed by angioplasty. Other significant medical history included asthma, epilepsy and hypothyroidism.

In view of her multiple attendances at breast clinic and M4 Mammography and no correlation between ultrasound and cytology, it was felt, she would benefit from excision biopsy for a definitive diagnosis and her own peace of mind. This was carried out in May 2004. Pathology demonstrated diabetic mastopathy.

Discussion

Diabetic Mastopathy is an uncommon fibro-inflammatory disease affecting the breast in patients with a long history of Type 1 Insulin Dependent Diabetes Mellitus. These lesions are normally associated with diabetic patients who also have complications of diabetes i.e. retinopathy and neuropathy. They have been described as occurring unilaterally, bilaterally and with recurrences [1].

Similar lesions, found in patients with no history of Diabetes, are known as Sclerosing lymphocytic lobulitis. These are thought to be associated with other autoimmune diseases. It has been postulated that the pathogenesis of these conditions is secondary to the autoimmune reaction to abnormal accumulation of extracellular matrix and advanced glycosylated end products, creating a "neo-antigen" that triggers a secondary autoimmune reaction with B cell proliferation and autoantibody formation [1].

This disease was first described in 1984 by Soler and Khardouri [2], they identified its correlation with long-standing type 1 diabetes mellitus.

One of the problems associated with the diagnosis of this condition is its resemblance to breast cancer on clinical evaluation. The lump is usually hard, irregular and some time with skin tethering on clinical examination.

When mammography is carried out, very dense breast tissue is seen, occasionally with an irregular focal mass or area of asymmetry

[2]. Ultrasound investigation can often support the clinical diagnosis of breast cancer, demonstrating an irregular hypoechoic mass with striking posterior acoustic shadowing [3].

One series by Wong et al. describes the use of colour Doppler ultrasound and MR imaging to differentiate benign diabetic mastopathy from breast cancer. Masses which are vascular on Doppler ultrasound and show enhancing masses at MR imaging are more likely to represent malignant lesions [4].

Ultimately the diagnosis of Diabetic Mastopathy is made on histology from core or excision biopsy.

In 1992, Tomaszewski et al. [5] described typical identifying features of diabetic mastopathy. Invariably patient has Type 1 diabetes, associated with secondary diabetic complications. Pathological findings of dense fibrosis with lymphocytic ductitis and lobulitis, lymphocytic perivascularitis and epithelioid fibroblasts are the main feature, though presence of epithelioid fibroblasts was thought to be diagnostic feature of diabetic mastopathy.

Further research by Ely et al. [6] demonstrated the presence of these epithelioid cells were seen in patients without the history of diabetes, therefore it is not as specific as first thought though their appearance may precede the onset of clinical diabetes or autoimmune disease.

Although tissues being affected by immune mediated mechanisms may demonstrate an increase in incidence of tumours in other places, there are no reported cases of these lesions of diabetic mastopathy undergoing any malignant change.

Conclusion

In summary we present these two cases of rather rare clinical entity which could be mistaken for breast cancer on clinical examination with indeterminate or suspicious features on triple assessment. The histology in case 1 was typical and showed every diagnostic feature of diabetic mastopathy. Excision biopsy becomes necessary for a definitive diagnosis. Further evaluation with colour Doppler ultrasound and Magnetic Resonance Imaging (MRI) techniques may be required to assess the benefit of these modalities for assessment of breast lumps in patients with Type 1 diabetes.

References

1. Camuto PM, Zetrenne E, Ponn T (2000) Diabetic mastopathy: a report of 5 cases and a review of the literature. Arch Surg 135: 1190-1193.
2. Soler NG, Khardori R (1984) Fibrous disease of the breast, thyroiditis, and cheiroarthropathy in type I diabetes mellitus. Lancet 1: 193-195.
3. Feder JM, de Paredes ES, Hogge JP, Wilken JJ (1999) Unusual breast lesions: radiologic-pathologic correlation. Radiographics 19 Spec No: S11-26.
4. Wong KT, Tse GM, Yang WT (2002) Ultrasound and MR imaging of diabetic mastopathy. Clin Radiol 57: 730-735.
5. Tomaszewski JE, Brooks JS, Hicks D, Livolsi VA (1992) Diabetic mastopathy: a distinctive clinicopathologic entity. Hum Pathol 23: 780-786.
6. Ely KA, Tse G, Simpson JF, Clarfeld R, Page DL (2000) Diabetic mastopathy. A clinicopathologic review. Am J Clin Pathol 113: 541-545.