

Description of *Trypanosoma dromedarius* (n.sp.) Infecting Camels by Light and Electron Microscopy with Refer to its Life Cycle

Barakat Shehata Abd-Elmaleck^{1*}, Gamal Hassan Abed¹ and Ahmed Mohammad Mandour²

¹Department of Zoology, Faculty of Science, Assiut University, Assiut, 71516, Egypt

²Department of Parasitology, Faculty of Medicine, Assiut University, Assiut University, Egypt

*Corresponding author: Barakat Shehata Abd-Elmaleck, Department of Zoology, Faculty of Science, Assiut University, Assiut, 71516, Egypt, Tel: 0201113532752; Fax: 002088342708; E-mail: barakatshehata@yahoo.com

Received date: Jun 19, 2014; Accepted date: Nov 26, 2014; Published date: Dec 1, 2014

Copyright: © 2014 Abd-Elmaleck, et al. This is an open-access article distributed under the terms of the Creative Commons Attribution License, which permits unrestricted use, distribution, and reproduction in any medium, provided the original author and source are credited.

Abstract

Out of 195 *Camelus dromedarius* examined only 19 were infected (9.7 %) with this parasite. The life cycle of *T. sp.* involves many morphologically distinct stages-more than described for any other genus in the Trypanosomatidae. This parasite was appeared for the first time in *Camelus dromedarius* at Assiut, Egypt.

Most of stages of *T. dromedarius* (n.sp.) which were appeared in the blood of *Camelus dromedarius* are amastigotes stages. At the same time spheromastigots, epimastigote stages and trypomastigote stages with two shapes slender and broad. In experimental infection, the trypanosome was found to be transmissible to laboratory white mice, also metacyclic and amstigote formes were seen.

Keywords: *Camelus dromedaries*; Spheromastigote; Metacyclic; Trypomastigote; Experimental; Amastigote; Epimastigote

Introduction

The majority of trypanosomes reported in bats have not been cultivated, and their classification has been based exclusively on the morphology of blood trypomastigotes. Large blood trypanosomes of the subgenus *Megatrypanum*, followed by small blood forms of the sub-genus *Schizotrypanum*, comprise the majority of the trypanosomes reported in bats throughout South America, Asia, Europe and, especially, Africa [1-4].

The subgenus *Megatrypanum*, originally comprising large blood trypanosomes from artiodactyls [5], was amended exclusively on a morphological basis to include any large tryp-anosome found in bats, monkeys and rodents [6].

Molecular phylogenetic analysis has demonstrated the polyphyly of the traditional subgenus *Megatrypanum*, which was revised as a clade comprising trypanosomes from ruminants headed by the type species *T. theileri*, a cosmopolitan parasite of cattle [7-10]. However, in the reappraisal of this subgenus, other species from non-ruminant hosts that putatively belong to this subgenus need to be phylogenetically positioned, especially those from bats.

Trypanosoma cruzi is the etiologic agent of Chagas disease, an endemic parasitosis in Latin America with 12 to 14 million people infected [11]. The parasite's biological cycle includes three fundamental forms characterized by the relative positions of the flagellum, kinetoplast, and nucleus [12]. (a) Trypomastigotes: 20 µm long, fusiform, subterminal kinetoplast, constitute the infecting form, and are found in mammalian blood and the hindgut of triatomine bugs; they do not multiply.

In mammals they are the disseminators of blood-borne infection [12]. (b) Epimastigotes: Also 20 µm long, kinetoplast anterior to the

nucleus, fusiform. They represent the parasite's multiplicative form in the triatomid's intestine, and are the predominant form in culture. For this reason it is the form most commonly used in biochemical studies [12]. (c) Amastigotes: Approximately 2 µm in diameter, round, without an emergent flagellum. They multiply by means of binary fission inside mammalian host cells, producing their rupture, and liberating trypomastigotes into the bloodstream that can once again invade any nucleated cell [12]. They can be grown in culture in muscle cells, fibroblasts, and macrophages among others [4,13].

Trypanosoma dromedarius (n.sp.) was infected *Camelus dromedarius* for the first time in Egypt through the present work so that; the present work aims to describe the different stages by both light and electron microscopy and to examine the zoonotic importance of the new parasite on the experimental animals (white rats).

Material and Methods

Out of 195 blood samples of camels (*Camelus dromedarius*) examined for blood protozoan parasites collected from different localities of Slaughter houses at Assiut city, Egypt (Dairout, Beni Ady, Elethamna). These freshly collected blood samples were divided in two groups one in a tube coated with EDTA, and the other in a test tube for Centrifugation to obtain sera. Thick and thin blood smears were made for morphological examination of some protozoan blood parasites. Electron microscopic studies.

TEM

Few drops from blood which is highly infected with *Trypanosoma*, *Babesia* and *Theileria* immediately fixed in 3 ml. of 3% glutaraldehyde solution in phosphate buffer (PH 7.2), for 24 hours and kept at 4°C in refrigerator. The samples were post fixed in 1% Osmium tetroxide in phosphate buffer (PH 7.2, 300 mom), for 30 minutes. They were washed several times with phosphate buffer solution. The samples

were then embedded in Epon which can preserve in structure from distortion during processing then ultra-thin sections were cut by an Ultra microtome and examined by JEOL, 100 CXII operating at 80 KV (TEM).

SEM

For scanning electron microscope of blood; few drops were fixed in 3% Glutaraldehyde in buffer for 24 hours. Specimens were washed three times in Phosphate buffer and post fixed in 1% Osmium tetroxide for 2 hours and then washed in the same buffer. They were Dehydrated in different grades of ethyl alcohol and then mounted on special holders and coated with gold. Then they were examined in a JSM-T 200 L.V. 5400 Scanning Electron Microscopy (SEM).

Experimental infection

One group of laboratory animals representing in five white rates were injected with freshly infected blood camels by doses 3 ml blood which was infected with the new parasite of trypanosomes to examine the zoonotic importance for this parasites. Blood examination was performed daily for determine the infection of these laboratory animals.

Results

Out of 195 *Camelus dromedarius* examined only 19 were infected (9.7%) with this parasite. Most of stages of *T. dromedarius* (n.sp.) which were appeared in the blood of *Camelus dromedarius* are amastigotes stages and were measured ($5-7.14 \times 4.8-7 \mu\text{m}$) in diameter (Figure 1). At the same time spheromastigots also were appeared (Figure 2). This parasite was seen for the first time in *Camelus dromedarius*. The body was slightly slender, small in size and with appearing for the amastigote stages in a heavy in the blood cells. The cytoplasm was granular and the kinetoplast nearly was a half size of the nucleus. The nucleus was oval or rounded in shape and measured ($1.68-2.76 \mu\text{m}$) in length and ($1.23-2 \mu\text{m}$) in width.

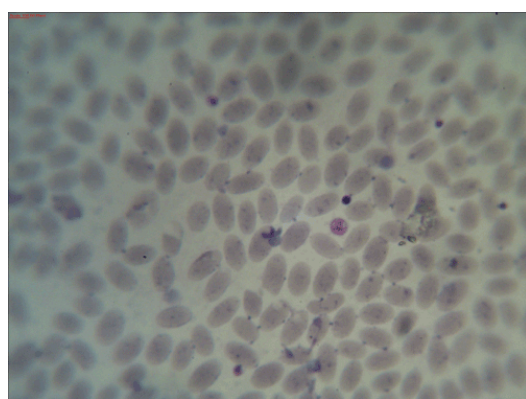


Figure 1: Photomicrograph showing amastigote stage of *Trypanosoma dromedarius* (n.sp) in the blood of *Camelus dromedarius* stained with Geimsa stain.

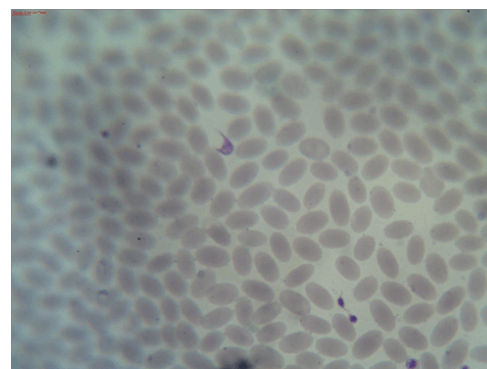


Figure 2: Photomicrograph showing spheromastigote stage of *Trypanosoma dromedarius* (n.sp) in the blood of *Camelus dromedarius* stained with Geimsa stain.

The free flagellum was fairly long. The undulating membrane was well developed, tightly surrounding the body and had only 2-3 shallow undulation as shown in Figures 3 and 4.

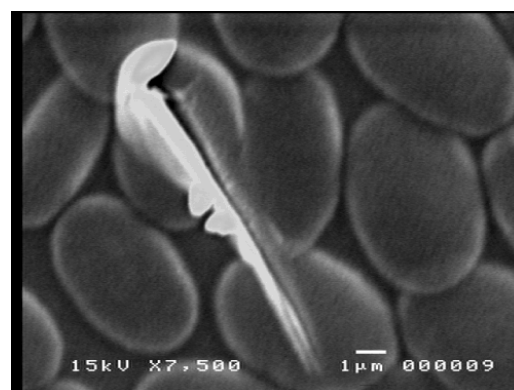


Figure 3: Scanning electron micrograph of slender trypomastigote form of *Trypanosoma dromedarius* (n.sp) showing the undulations in the blood of *Camelus dromedarius*.

Scanning electron microscopy was revealed most of the life cycle stages of *Trypanosoma dromedarius* (n. sp.) and was showed diversity of forms including the epimastigote stages which measured ($13 \times 4.2 \mu\text{m}$) in diameter (Figure 5) at the same time intermediate stages were seen and measured ($11.25-16.6 \mu\text{m}$) in length and ($4.25-6.25 \mu\text{m}$) in width (Figure 6). Also trypomastigote stages were measured ($16-18 \mu\text{m}$) in length and ($1.28-3.15 \mu\text{m}$) in width (Figure 7). In addition that, the unequal division in the amastigote and trypomastigote stages was seen in Figures 8 and 9 respectively.

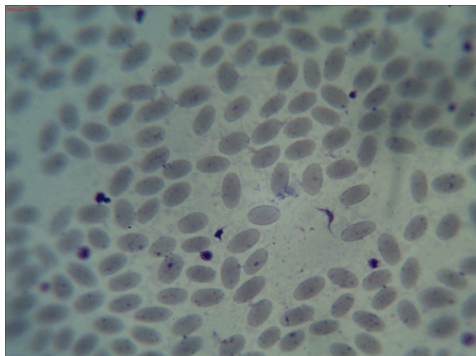


Figure 4: Photomicrograph showing trypomastigote (adult) stage of *Trypanosoma dromedarius* (n.sp.) in the blood of *Camelus dromedarius* stained with Geimsa stain.




Figure 5: Scanning electron micrograph showing epimastigote stage of *Trypanosoma dromedarius* (n.sp.) in the blood of *Camelus dromedarius*.

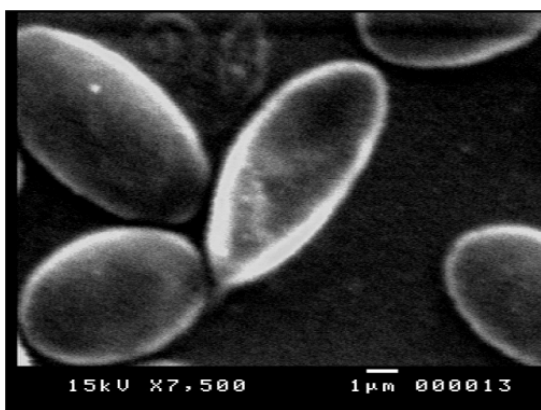


Figure 6: Scanning electron micrograph showing intermediate form of *Trypanosoma dromedarius* (n.sp.) in the blood of *Camelus dromedarius*.

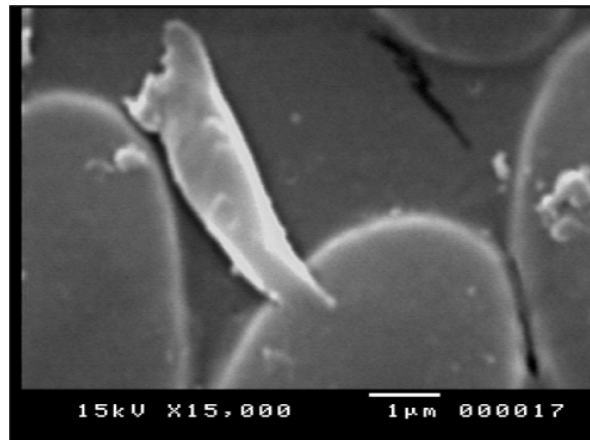


Figure 7: Scanning electron micrograph showing trypomastigote form of *Trypanosoma dromedarius* (n.sp.) in the blood of *Camelus dromedarius*.

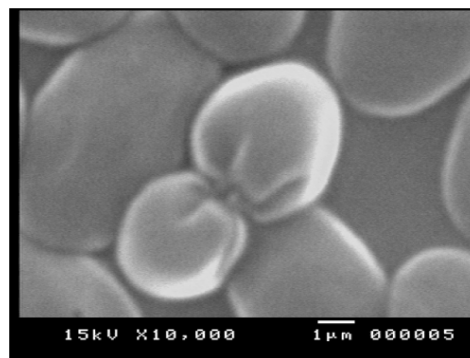


Figure 8: Scanning electron micrograph showing division in amastigote form of *Trypanosoma dromedarius* (n.sp.) in the blood of *Camelus dromedarius*.

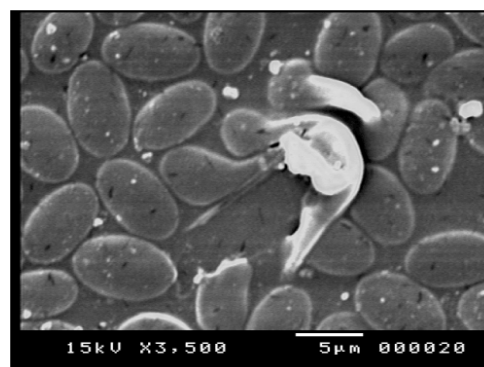


Figure 9: Scanning electron micrograph showing division in trypomastigote form of *Trypanosoma dromedarius* (n.sp.) in the blood of *Camelus dromedarius*.

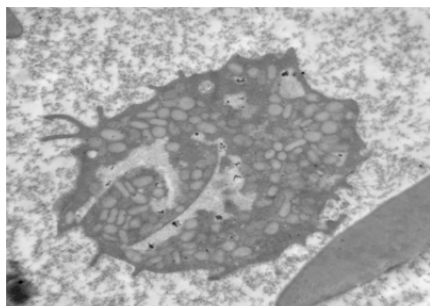


Figure 10: Transmission electron micrograph showing the flagellar pocket (Fp) in spheromastigote stage of *Trypanosoma dromedarius* (n.sp) in the blood of *Camelus dromedarius*.

The ultrastructural organization of *Tr. dromedarius* revealed also all common organelles of trypanosomatids. However, some features as, the cytostome which forms together with the flagellar pocket the main structure involved in the endocytic process (Figure 10), large number of reservosomes (Figure 11), which are compartments that accumulate endocytosed macromolecules found at the posterior region of epimastigotes and the compacted disk shaped kinetoplast structure and the division in stage as in Figure 12.

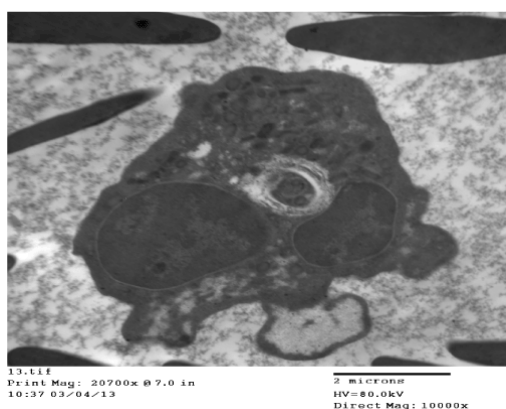

Figure 11: Transmission electron micrograph showing reservosomes (R) and nucleus (N) in amastigote stage of *Trypanosoma dromedarius* (n.sp) in the blood of *Camelus dromedarius*.

In wet preparation, living trypanosomes were moving actively among the red blood cells. In experimental infection, the trypanosome was found to be transmissible to laboratory white rats, metacyclic trypomastigote and amastigote stages were appeared in the tissue and blood of the rat respectively as in Figures 13 and 14. The life cycle stages for this parasite was showing in Figure 15.

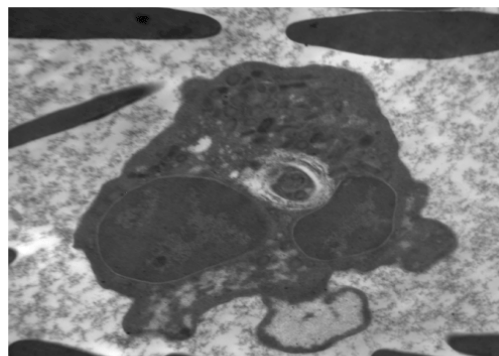


Figure 12: Transmission electron micrograph showing division in amastigote stage with two nuclei (N) and kinetoplast (K) in its way to division of *Trypanosoma dromedarius* (n.sp) in the blood of *Camelus dromedarius*.

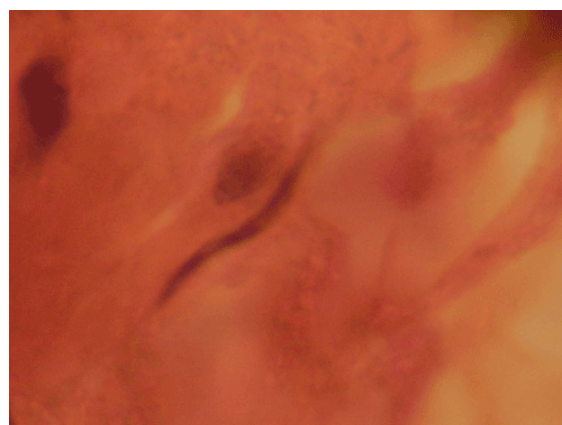


Figure 13: Enlarged photomicrograph showing *Tr. dromedarius* in the liver of white rat after 74 day of infection stained with H & E.

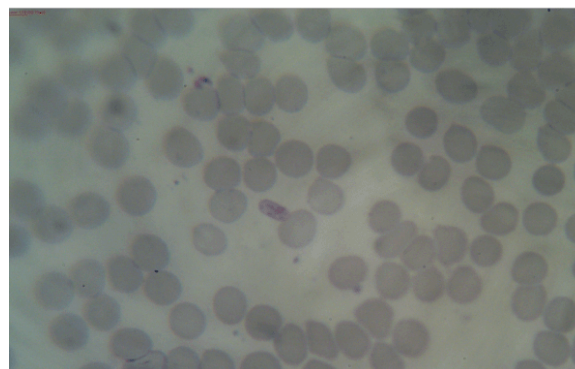


Figure 14: Photomicrograph showing amastigote stage (Am) of *T. dromedarius* (n. sp) in the blood of white rat stained with Geimsa.

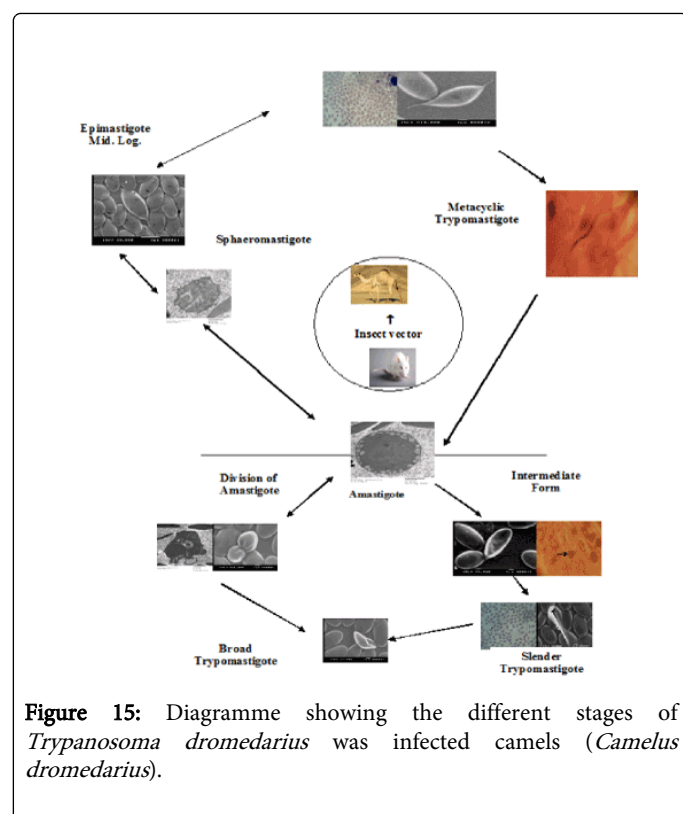


Figure 15: Diagramme showing the different stages of *Trypanosoma dromedarius* was infected camels (*Camelus dromedarius*).

Discussion

By comparison this species with other trypanosomes in mammals. It was found that *T. cruzi* like trypanosomes [2], which the name trypanosome (schizotrypanum) *assiutis* sp. nov. was measured 19.4 µm in maximum body length, one nucleus was measured 1.16 µm and was encountered of local Egyptian bat *Vesperugo kuhli* and it was non-transmissible for white rat but in the present study this *T. sp.* was measured 18 µm in maximum body length, it was encountered *Camelus dromedarius* and the nucleus of the new trypanosome was measured 1.68-2.7 µm and it was transmissible for white rat.

All trypanosome *evansi* isolates described by [10], the maximum of body length was 34 µm. Also the mean length for *T. vivax* ranged between 18.73-25.4 µm [7,10]. But the present parasite was measured 18 µm in maximum length which differs from the mentioned species.

Another tropical trypanosome that can affect domestic animals is *Trypanosoma congolensis* (Subgenus: *Nanomonas*) but morphologically it is distinguishable because of its small size mean (12.2-17.6 µm) and the absence of a free flagellum [10] but in the presence species there was a free flagellum and undulating membrane with 2-3 undulation.

From the previous comparison, the present species differs from the previous trypanosomes in some respects, so that the present trypanosome could be identified as a new species called *T. dromedarius* according to its host *Camelus dromedarius*.

Host: *Camelus dromedarius*.

Locality: Manflout – Assiut, Egypt.

Parasite: *Trypanosoma dromedarius* (n.sp.).

Conclusion

Trypanosoma dromedarius (n.sp.) is new species trypanosomes and was appeared for the first time in *Camelus dromedarius*. This parasite was had a zoonotic importance for its transmissible to the experimental animals (white rats).

References

1. Cottontail VM, Wellinghausen N, Kalko EK (2009) Habitat fragmentation and haemoparasites in the common fruit bat, *Artibeus jamaicensis* (Phyllostomidae) in a tropical lowland forest in Panamá. *Parasitology* 136: 1133-1145.
2. Hamilton PB, Adams ER, Njiokou F, Gibson WC, Cuny G, et al. (2009) Phylogenetic analysis reveals the presence of the *Trypanosoma cruzi* clade in African terrestrial mammals. *Infect Genet Evol* 9: 81-86.
3. Hoare CA (1964) Morphological and Taxonomic Studies on Mammalian Trypanosomes. X. Revision of the Systematics. *J Protozool* 11: 200-207.
4. Hoare CA (1972) The Trypanosomes of Mammals. *Internat Med Parasitol* 1: 749.
5. García L, Ortiz S, Osorio G, Torrico MC, Torrico F, et al. (2012) Phylogenetic analysis of Bolivian bat trypanosomes of the subgenus *schizotrypanum* based on cytochrome B sequence and minicircle analyses. *PLoS One* 7: e36578.
6. Guerra RM, Santos HP, Abreu-Silva AL, Santos AC (2008) Biometry of *Trypanosoma vivax* found in a calf in the state of Maranhão. *Brazil Cien Rur* 38: 833-835.
7. Faundez M, Pino L, Letelier P, Ortiz C, López R et al. (2005) Buthionine sulfoximine increases the toxicity of nifurtimox and benznidazole to *Trypanosoma cruzi*. *Antimicrob Agents Chemother* 49: 126-130.
8. Gardner RA, Molyneux DH (1988) *Trypanosoma* (Megatrypanum) *incertum* from *Pipistrellus pipistrellus*: development and transmission by cimicid bugs. *Parasitology* 96: 433-447.
9. Morello A (1988) The biochemistry of the mode of action of drugs and the detoxication mechanisms in *Trypanosoma cruzi*. *Comp Biochem Physiol C* 90: 1-12.
10. Pinto CM, Kalko EK, Cottontail I, Wellinghausen N, Cottontail VM (2012) TcBat a bat-exclusive lineage of *Trypanosoma cruzi* in the Panama Canal Zone, with comments on its classification and the use of the 18S rRNA gene for lineage identification. *Infect Genet Evol* 12: 1328-1332.
11. Prata A (2001) Clinical and epidemiological aspects of Chagas disease. *Lancet Infect Dis* 1: 92-100.
12. Lisboa CV, Pinho AP, Herrera HM, Gerhardt M, Cupolillo E, et al. (2008) *Trypanosoma cruzi* (Kinetoplastida, Trypanosomatidae) genotypes in neotropical bats in Brazil. *Vet Parasitol* 156: 314-318.
13. Fahmy MAM, Abedl-Rahman AM, Khalifa R (1978) *Trypanosoma* (Schizotrypanum) *assiutis* sp. nov. from the house mouse *Mus musculus*, with a comparative study on *Trypanosoma* (Schizotrypanum) *vespertilionis* of the Egyptian bat *Vesperugo kuhli*. *Parasit* 77: 249-254.