

Dental Management in an Encephalotrigeminal Angiomatosis Patient: A Case Report

Prashanthi C, Sujatha S. Reddy, Kuhu Majumdar

Department of Oral medicine, Diagnosis and Radiology, M.S.Ramaiah Dental College & Hospital, MSRIT Post, New BEL Road, Bangalore-560054. Karnataka, India.

Abstract

Sturge - Weber Syndrome (SWS) is a rare, non-hereditary, congenital neuro cutaneous disorder characterized by vascular hamartomatous proliferations affecting classically, the leptomeninges and the skin of the face and may be associated with glaucoma, seizures and mental retardation. Intraoral findings are variable. A case of Roach type II Sturge Weber syndrome is reported here that did not show any neurological disorder but revealed a prominent angiomatous enlargement of the ipsilateral maxillary gingiva. SWS is a condition where dental management and surgical procedures of the patient can be risky, thus a sound knowledge of the disease and its management protocols better equips the clinician to avoid serious complications.

Key Words: Sturge-weber syndrome, Encephalotrigeminal angiomatosis, Port wine stain, Intra oral haemangioma

Introduction

Sturge - Weber syndrome (SWS) also known as encephalo trigeminal angiomatosis is a rare, non-hereditary, congenital neuro-cutaneous disorder. It is characterized by vascular hamartomatous proliferations affecting classically, the leptomeninges and the skin of the face. Other common features of this syndrome include glaucoma and mental retardation [1,2].

Its estimated frequency is 1 in 50,000 live births [3]. It affects both sexes equally and has no proven racial predilection [2,4]. Although the exact pathogenesis of SWS is still unclear, it is believed to be a consequence of the persistence of a primitive embryonal vascular plexus around the cephalic portion of the neural tube, which normally regresses during the ninth week of intra-uterine life [1].

Leptomeningeal angiomas are usually present unilaterally, more commonly involving the parietal and occipital lobes. Altered vascular dynamics may lead to calcium deposition in the cerebral cortex underlying the angioma subsequently causing seizures, contralateral hemiparesis and neurological deficits. The facial Port Wine Stain (PWS) also usually occurs unilaterally along the dermatomes supplied by the ophthalmic and maxillary divisions of the trigeminal nerve. Bilateral presentation and cases where PWS extend to involve the neck, chest other areas of the body, however, have also been reported [5,6].

Intraoral findings are variable but the most common feature is a hemangiomatous gingival enlargement of the ipsilateral maxilla/mandible. SWS is a condition where dental management and surgical procedures of the patient can be risky, thus a sound knowledge of the disease better equips the clinician to avoid serious complications.

Case Report

A 36 year old female patient reported to our department with a complaint of pain in the maxillary anterior region since 3 months. She also complained of a red coloured patch over the

right side of the face since birth (*Figure 1*). The lesion had progressively enlarged and darkened in colour from the time of birth. Family history did not reveal any similar complaints among immediate and distant relatives of the patient.

Extra-oral examination revealed gross facial asymmetry and incompetent lips with a purple-red unilateral facial vascular malformation in the distribution of V₁ and V₂ divisions of the trigeminal nerve on the right side. The right eye appeared to be displaced slightly superiorly and revealed prominent dilated ocular vessels (*Figure 2*).

Intra-orally, Ellis class III fracture of 21 was noted which was identified as the cause of pain. Prominent angiomatous enlargement of the ipsilateral maxillary gingiva was observed along with hyper-vascular changes in the labial mucosa and palate of the same side ending abruptly at the midline (*Figures 3 and 4*). Gingival growth in the region of the posterior maxillary teeth appeared to extend up to the cervical third region of the crowns of molars and the gingival margins on the affected side appeared to be intact. Generalized dental fluorosis, attrition and wear facets were the other dental findings along with malocclusion. Diascopy confirmed the vascularity of the

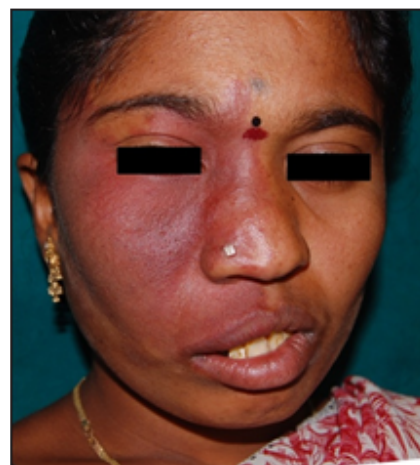

Figure 1. Unilateral port wine stain on the right side of the face.

Corresponding author: Dr. Kuhu Majumdar BDS (MDS), Post graduate student, Department of Oral medicine, Diagnosis and Radiology, M.S.Ramaiah Dental College & Hospital, MSRIT Post, New BEL Road, Bangalore-560054, Karnataka, India; e-mail: kuhu_majumdar31@yahoo.com

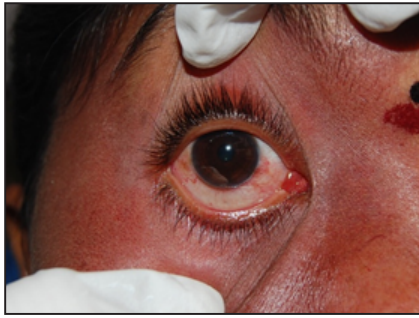


Figure 2. Dilated ocular blood vessels.

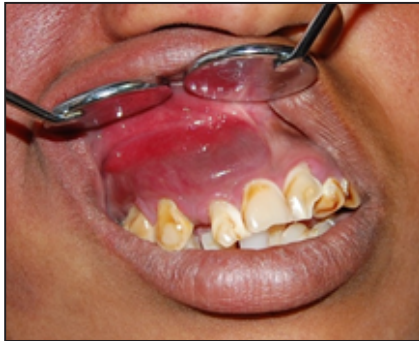

Figure 3. Angiomatous enlargement of maxillary gingiva.

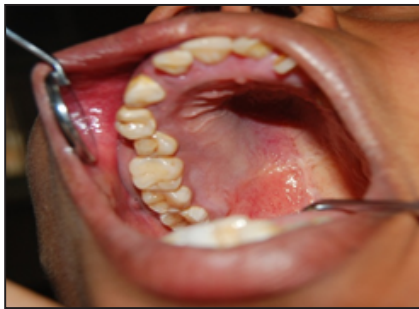

Figure 4. Hypervascular lesion of the palate, buccal mucosa and labial mucosa with hypertrophy of the maxillary bone seen buccally.

facial and oral lesions. Radiological investigations however did not reveal any significant finding. Panoramic radiograph revealed that the fracture of 21 had involved pulp and also showed spacing between 12 and 13 and displacement of the crowns in opposite directions (*Figures 5 and 6*). An incidental finding of a right maxillary sinus polyp was revealed on an MRI scan of brain which had been performed to rule out any intracranial calcifications and did not reveal any such findings (*Figure 7*). After a consultation with the ear-nose-throat surgeon, surgical intervention for the maxillary sinus polyp was precluded to avoid unnecessary complications. Consultation with an ophthalmologist, who performed a thorough examination and fundoscopy, helped to rule out glaucoma. A dermatologist was also consulted for aesthetic concerns who advised pulsed dye laser therapy to reduce the size of the lesion.

Dental management for our patient included Scaling and Root Planning (SRP), endodontic treatment of 21, elaborate oral hygiene instructions, following which she was relieved of pain, and is being followed up regularly.

Discussion

Port wine stains represent hamartomatous capillary

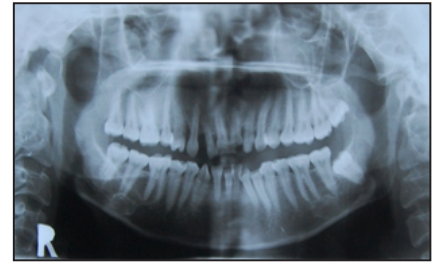


Figure 5. Panoramic radiograph showing fractured 21 and spacing between 12 and 13.

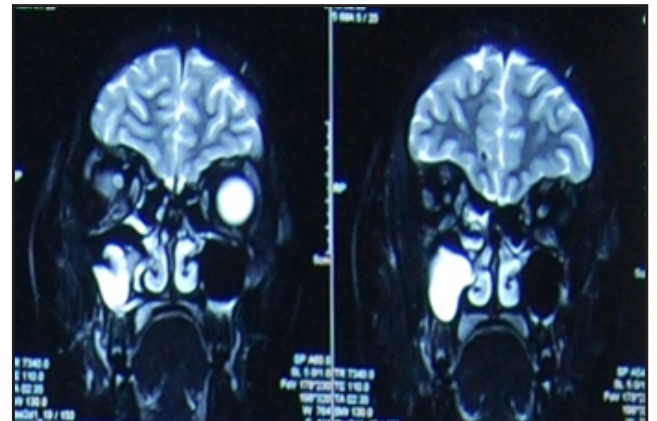


Figure 6. Coronal section of an MRI showing right maxillary sinus polyp/retention cyst (arrow).

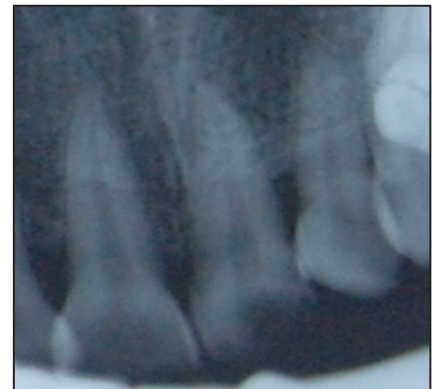

Figure 7. Intra-oral radiograph showing pulpal involvement of coronal radiolucency in relation to 21 with widening of apical periodontal ligament space.

malformations and are named so due to the deep red hue that they leave on the skin or mucosa [7]. Such lesions tend to bleed profusely when traumatized.

All patients with facial port wine stains may not have Sturge-Weber angiomatosis. According to Enjolras et al. patients with involvement along the distribution of the ophthalmic branch of the trigeminal nerve are at risk for developing associated neuro-ocular symptoms that are characteristically associated with this disease [8].

The Roach scale [9] is used for classification of SWS -

Type I- Both facial and leptomeningeal angiomatosis; may have glaucoma

Type II – Facial angiomatosis alone; may have glaucoma

Type III – Isolated leptomeningeal angiomatosis; usually no glaucoma

According to the above classification, the case reported here will belong to the Type II category as she neither gave a history of epilepsy nor showed any signs of mental retardation.

Leptomeningeal angiomas typically occur as lesions unilaterally affecting the pia- arachnoid membrane over the posterior temporal, parietal and occipital areas. It is often associated with an abnormal blood flow pattern such as venous occlusion, thrombosis, vasomotor phenomenon and vascular steal phenomenon resulting in cortical ischemia. This in turn gives rise to prominent neurological effects such as epileptic convulsions, contralateral hemiparesis, gliosis and progressive deposition of calcium salts in the cortex. These calcifications produce a characteristic double contoured “tram-line” appearance following the convolutions of cerebral cortex which if noted radiographically are pathognomonic of SWS [6]. In the present case, however, these were not observed.

Intraoral involvement is common and the most common manifestation is an angiomatous lesion of gingiva which can vary from slight vascular hyperplasia to massive hemangiomatous proliferation attributed to an increase in the vascular component [5]. The oral manifestations are generally unilateral and finish abruptly in the midline. Some cases have reported macroglossia and maxillary bone hypertrophy which may be the cause of malocclusion and facial asymmetry [6].

Majority of the cases of SWS are not life threatening. SWS are considered to be associated with progressive neurological deterioration [10]. However, a systematic approach to treat symptoms such as seizures and visual disturbances using appropriate medication, and considerations regarding the port wine stain, associated mental disorder and paralysis may help in preserving the quality of life. Heller et al. [11] stated that the classic port wine stain had a significantly negative effect on the psychological development of such patients and thus some clinicians advocate its removal/ lightening. Several methods to achieve this include dermabrasion, tattooing and lash lamp pulse tunable dye laser therapy. Cryosurgery may be considered for treatment of lip and other soft tissue lesions [12]. Some investigators believe that despite stringent oral hygiene

measures, sometimes gingivectomy may be necessary to treat gingival enlargement. This could be due to superimposition of drug induced gingival enlargement, secondary to anti-epileptic drugs prescribed to many of the patients, on an existing angiomatous gingival lesion. Manivannan et al. performed gingivectomy using electrosurgery in a patient and confirmed its utility in minimising haemorrhage [13]. Use of Nd: Yag laser has also been advocated by some to achieve similar results [14-16]. Kalakonda et al. have reported a series of cases managed using diode laser for gingivectomy and electrocautery to manage the bleeding points [17].

Our patient was particularly concerned about the appearance of the facial PWS but could not afford the pulsed dye laser treatment advised to her. She was counselled, however, following which endodontic therapy and SRP was performed. Thus, being sensitive to the patient’s psychological condition and including counselling as part of the treatment plan not only boosts the patient’s confidence levels, but also evokes a more desirable patient compliance and response to dental treatment.

Conclusion

Treatment of patients with SWS poses a challenge to dental health professionals and they must always be mindful of the possible risks associated with each clinical procedure. Suitable hemostatic agents and emergency equipment must always be within reach when treating these patients and special attention must be given to behavioural management of these patients. Routine procedures must be performed as atraumatically as possible while surgical procedures, if necessary, must preferably be performed in a hospital setting.

Acknowledgement

We would like to thank our Principal, Dr. Sreenivasa Murthy BV, Dr. Yashoda Devi B.K. for their support and guidance.

References

1. Neville BW, Damn DD, Alen Cm, Boquot JE (Editors) Oral and Maxillofacial Pathology (2nd edn.) Philadelphia: Elsevier; 2002, pp. 471-473.
2. Dorothy A, Kamboj M, Reddy BS, Mahajan S, Boaz K. Sturge Weber syndrome. *Indian Journal of Dental Research*. 2004; **15**: 152-154.
3. Welty LD. Sturge-Weber Syndrome: A case study. *Neonatal Network*. 2006; **25**: 89-98.
4. Di Rocco C, Tamburrini G. Sturge-Weber syndrome. *Childs Nervous System*. 2002; **22**: 909-921.
5. Feller L, Lemmer J. Encephalotrigeminal angiomatosis. *Journal of the South African Dental Association*. 2003; **58**: 370-373.
6. Khambete N, Risbud M, Kshar A. Sturge- Weber syndrome: A case report. *International Journal of Dental Clinics*. 2011; **3**: 79-81.
7. Fishman SJ, Mulliken JB. Hemangiomas and vascular malformations of infancy and childhood. *Pediatric Clinics of North America*. 1993; **40**: 1177-1200.
8. Enjolras O, Riche´ MC, Merland JJ. Facial port-wine stains and Sturge-Weber syndrome. *Pediatrics* . 1985; **76**: 48-51.
9. Roach ES. Neurocutaneous syndromes. *Pediatric Clinics of North America*. 1992; **39**: 591-620.
10. Rochkind S, Hoffman HJ, Hendrick EB. Sturge Weber Syndrome: natural history and prognosis. *Journal of Epilepsy*. 1990; **3**: 293-304.
11. Heller A, Rafman S, Zvagulis I, Pless IB. Birth defects and psychosocial adjustment. *The American Journal of Diseases of Children*. 1985; **139**: 257-263.
12. Laskin MD. Oral and maxillofacial surgery (2nd edn.) St Louis: CV Mosby Co., 1985; pp. 528-529.
13. Manivannan N, Gokulanathan S, Ahathya RS, Gubernath, Daniel R, Shanmugasundaram. Sturge-Weber syndrome. *Journal of Pharmacy and Bioallied Sciences*. 2012; **4**: 349-352.
14. De Benedittis M, Petrucci M, Pastore L, Inchingolo F, Serpico R. Nd: YAG laser for gingivectomy in Sturge-Weber syndrome. *Journal of Oral and Maxillofacial Surgery*. 2007; **65**: 314-316.
15. Gill NC, Bhaskar N. Sturge-Weber syndrome: A case report. *Contemporary Clinical Dentistry*. 2010; **1**: 183-185.
16. De Benedittis M, Petrucci M, Pastore L, Inchingolo F, Serpico R. Nd: YAG laser for gingivectomy in Sturge-Weber syndrome. *Journal of Oral and Maxillofacial Surgery*. 2007; **65**: 314-316.
17. Kalakonda B, Pradeep K, Mishra A, Reddy K, Muralikrishna T, Lakshmi V, et al. Periodontal Management of Sturge-Weber Syndrome. *Case Reports in Dentistry*. 2013; **2013**: 517145.