

Deciding on retention in Ist and IInd class Kennedy edentulousism

Oana-Cella Andrei¹, Mihaela Pauna²

Department of Removable Prosthodontics, Faculty of Dental Medicine,
"Carol Davila" University of Bucharest

Summary

The clinician must plan to ensure that the prosthesis resists movement away from the tissues that support it, irrespective of whether it is to be fixed or removable. Removable prosthesis achieves its retention in a variety of ways (clasps, precision attachments, planned use of undercuts and guide planes) and using neuromuscular control. The use of resilient snap attachments in IInd and Ist class Kennedy edentulous situations is an esthetic and functional solution, but we need to be aware of the potential for bulk and to plan common path of insertion and withdrawal.

Objectives. The study intended to establish the protocol that is to apply in designing the prosthesis with a view to securing the best results in retention using snap resilient attachments and the way the direct retainers' action is increasing with the presence of the indirect retainers on the R.P.D. (removable partial denture) design.

Material and methods. We treated and observed a group of 30 patients aged between 45-60 years old in different situations of IInd and Ist class Kennedy edentulous arches, which had snap R.P.D. with or without indirect retainers.

Results. Using snap resilient attachments in Ist and IInd class Kennedy edentulous patients proved to be an inspired long term solution considering that mobility measurements on the abutment teeth made with dentoperiodontal mobile meter device registered no variations during this period of time if the denture had indirect retainers.

Conclusions. The indirect retainers are protecting the edentulous ridge to accelerate resorption; they are increasing the retention of the R.P.D. with snap attachments and they are precluding the fracture of the attachment.

Key words: R.P.D., snap spherical attachments, indirect retainers.

Introduction

Planning removable partial denture retention is an integral part of the treatment plan that concerns both the fixed parts (retained through parallelism, friction and cement materials) and the mobile prosthesis itself for which the clinician is designing direct and indirect retainers. The direct retainers are the snap spherical resilient attachments while the indirect retainers are

the guide plans, the opposing arms (milled support for stress distribution arm) and the interlocks (proximal connecting elements) milled on the parallelometer in the insertion-withdrawal path.

Material and methods

According to The Glossary of Prosthodontic terms (Academy of Prosthodontics 1999) a precision attachment is "a device

¹ Assist. Prof., Department of Removable Prosthodontics, Faculty of Dental Medicine, "Carol Davila" University of Bucharest

² Professor, Department of Removable Prosthodontics, Faculty of Dental Medicine, "Carol Davila" University of Bucharest

which comprises of two or more components which is machined or fabricated for the purposes of providing retention to prosthesis". The snap-type precision attachments may be resilient or non-resilient. The vertical space necessary for the use of snap attachments is generally of about 5 mm but the system is available in various dimensions.

To ensure comfort and functionality to the patient the prosthesis must be as stable as possible during its current use. Irrespective of whether the prosthesis is fixed or removable the clinician must plan

the way it would withstand the tendency of moving away from the support tissues. The fixed prosthesis gains its retention through parallelism, friction and cement materials. The mobile prosthesis gains its retention in many more ways. The mobile prosthesis with snap attachments uses this type of extracoronal matrix-patrix precision attachments as main mean of retention (*Figures 1, 2, 3, 4.*). This kind of precision attachments may be fabricated totally metallic or having polymer components. Using polymer components has at least two advantages:




Figure 1. Prefabricated castable (patterns) plastic matrix



Figure 2. Polymer changeable matrixes: green for reduced retention, yellow for medium retention, red for increased retention




Figure 3. Accessories for the parallelometer




Figure 4. Matrix insertion sprue used for placing the matrix into the prosthesis (www.bredent.com)

- increased resilience therefore protection against overloading the abutment teeth;
- can be replaced when they are loose and the system (and also the prosthesis) regains its initial retention.

We treated and observed a group of 30 patients aged between 45-60 years old in different situations of IInd and Ist class Kennedy edentulous arches, which had snap R.P.D. with or without indirect retainers. The prosthesis has an efficient retention if it does not move away involuntarily from the support structures when the patient is chewing sticky aliments (e.g. white bread). The passage from clasps to precision attach-

ments is being determined by esthetic criteria considering the excessive visibility of the clasps and not the retention's efficiency that is sufficient in their case. Precision attachments are more esthetic, but tend to achieve a stronger than needed retention, to the detriment of the sustaining system of the principal abutment tooth. If the R.P.D.'s design is correct (in the sense of the maxim functional extension of the free-end saddles) and if the indirect retainers have been included in the design, it will not require for retention more than two snaps attachments bilaterally distributed [1].

If these design conditions are not accomplished, some inconvenience occurs, such as rapid deactivation of the system through premature usage of plastic components, exaggerate rotational movement of free-end saddles with fracture of some of the prosthesis components and also decompensate functional stress on principal abutment teeth. Normally, a correctly designed prosthesis on a stabilized subjacent bony tissue does not require the change of the plastic components and the relining of saddles earlier than two years since application.

It appears that the resilient spherical snap attachments are the less soliciting simple precision attachments due to the spherical form of the patrix allowing an insensitive movement of the free-end saddles without soliciting the abutment teeth, therefore functioning as stress breakers. Generally, the use of these retainers requires two abut-

ment teeth limiting the edentulous space. The abutment teeth should be free of inflammation, capable of bearing loads and have sufficient length. In the Ist class Kennedy edentulism these teeth are medially located (*Figure 5*). In the IInd class Kennedy edentulism the most advantageous for the long-term periodontal resistance is the placement of the snap on a bar that would function as a bridge between the medial and distal abutment teeth (*Figure 6*).

There are various clinical situations of edentulism and the number of designed abutment teeth can be higher or lower. When in the case of the terminal edentulism we have only the frontal group as remaining teeth, for periodontal and biomechanical reasons it is strongly necessary to take all these teeth as abutments in a functional block (*Figures 7, 8*).

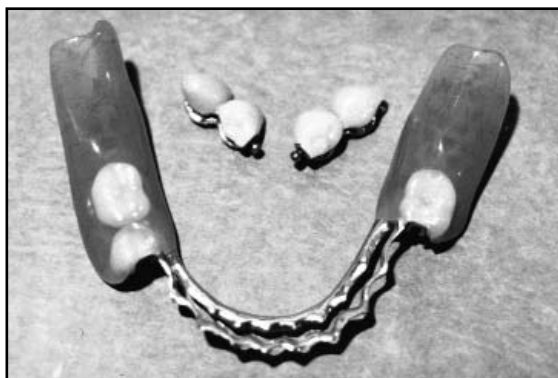

Figure 5. RPD for the Ist class Kennedy edentulism; unified crowns on the medial abutments

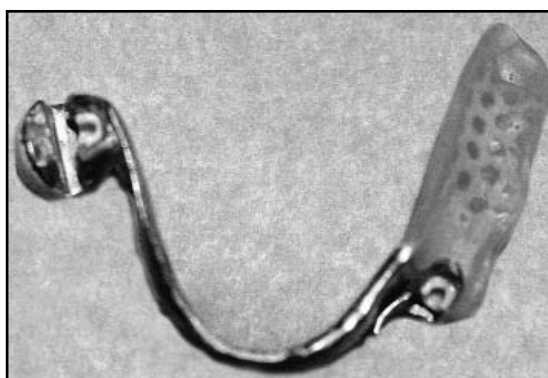


Figure 6. RPD for the IInd class Kennedy edentulism; the snap is placed on a bar

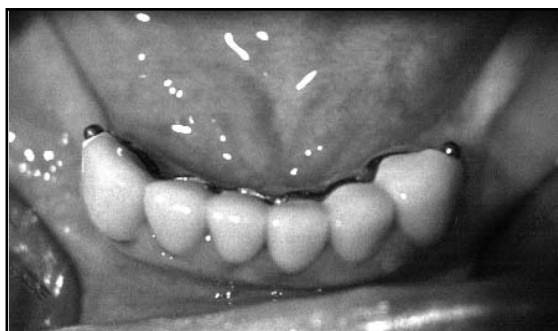

Figure 7. The remaining frontal teeth unified in a functional block in a large Ist class Kennedy edentulism situation

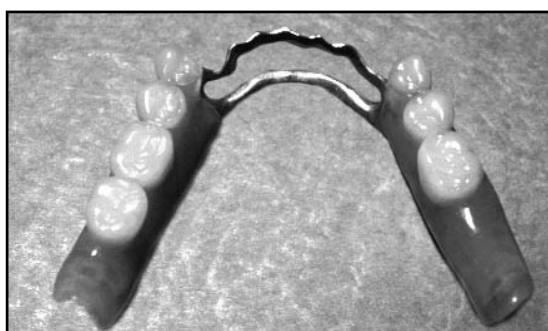


Figure 8. The RPD appearance in a large Ist class Kennedy edentulism situation

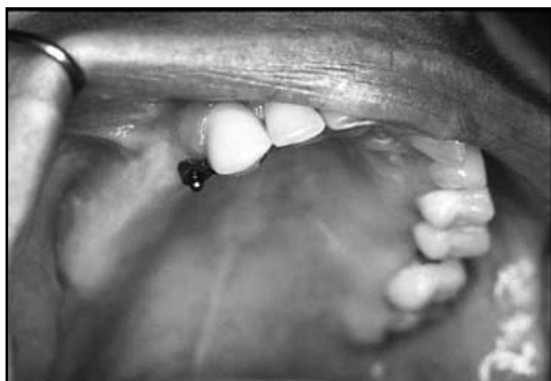

Figure 9. The canine used as medial abutment

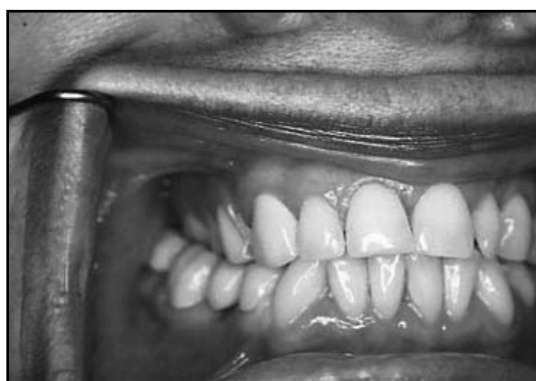

Figure 10. The free-end saddle - final situation

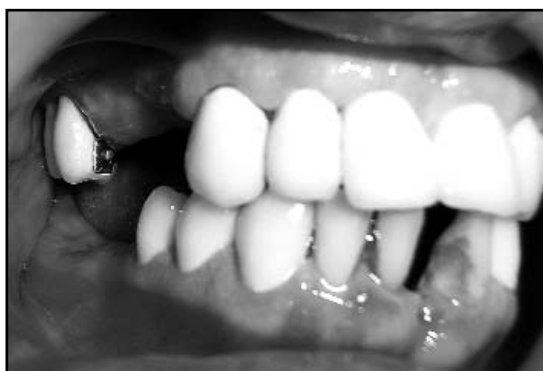

Figure 11. The last molar and the position of the attachment

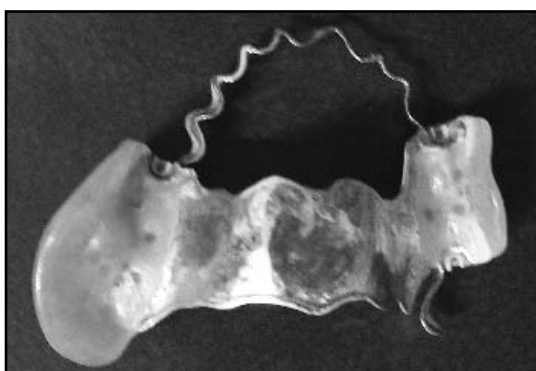


Figure 12. The lateral bounded saddle can be transformed in a free-end saddle

If we have to take the canine as abutment tooth in IInd class Kennedy edentulism, while the lateral incisor has a rotated position on the arch or has reduced dimensions it is inappropriate to use it as abutment tooth. The dentist can use the canine as unique abutment if on the opposing part of the arch there is a sufficient number of remaining teeth (*Figures 9, 10*).

A R.P.D. with resilient snap attachment must be simple in design, using the minimum number of precision attachments needed for direct retainers and the minimum number of saddles. It is obvious that the use of a lateral bar functioning like a bridge between the limiting teeth of a lateral edentulous space is a much more advantageous solution, inclusively from the point of view of the periodontal system of these teeth, than the placement of a snap on each tooth and

planning a saddle with two matrixes. This solution also complicates achieving of the guide plans and selecting the common path of insertion and withdrawal. Though having said that, when the distal abutment tooth of a lateral edentulous space has a more reserved prognostic compared to the medial teeth, but not to the extent of requiring the extraction, two medial teeth can be held together while a separate snap can be placed distally on the molar. Though usually losing a principal abutment tooth leads to the loss of mobile prosthesis itself, in this situation the extraction of the molar would not affect the retention as the resilient snap attachment medially positioned is sufficient and the lateral bounded saddle can be prolonged so that it transforms to a free-end saddle (*Figures 11, 12*).

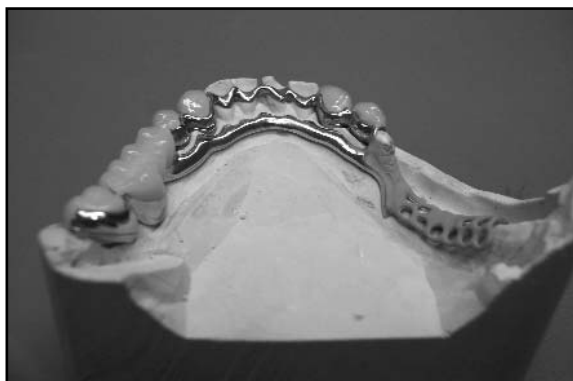

Figure 13. The major mandible double bar connector on the working cast

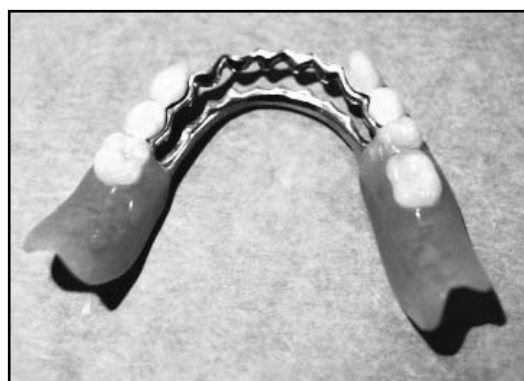

Figure 14. Mandibular RPD with double bar connector

These examples of apparent exceptions are not recommendations to refrain from applying classic principles of prosthesis design. On the contrary, these are coming to stress once again that the design of a resilient snap attachment is mandatory to be adapted to each clinical situation by the clinician, and the cooperation with the dental technician is of course only in the sense of the precise execution of the established design.

Beside snaps, that are responsible with the direct retention, the following elements are also interfering in achieving the indirect retention [2]:

- anterior or posterior bony undercuts;

- the major mandible double bar connector (designed as a lingual bar plus a continuous clasp) (*Figures 13, 14*);

- the neuromuscular control (difficult to be quantified and also difficult to be obtained in some patients);

- use of guide plans, of the opposing arms and the interlocks milled on the parallelometer in the insertion-withdrawal path (*Figure 15*);

- in the case of a partial denture it is, for sure, impossible to obtain a peripheral seal like the one obtained with a total prosthesis, though in some cases and on certain areas we can obtain it if we are extending the free-end saddles to the maximum limits of the supporting tissues.

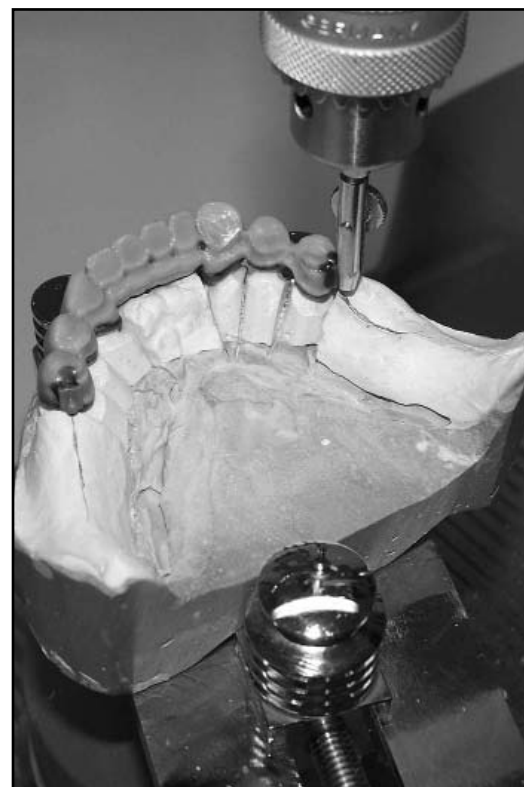

Figure 15. Milling and positioning the attachments on the parallelometer in the insertion path

The indirect retainers are the components of the partial denture helping the direct retainers to foresee and prevent the lift of the distal area of the saddles. These are also working as a stop point of the lever on the opposite side of the fulcrum line when the saddle rotates around this line [3].



Figure 16. Milling of the opposing arms and interlocks on the milling base

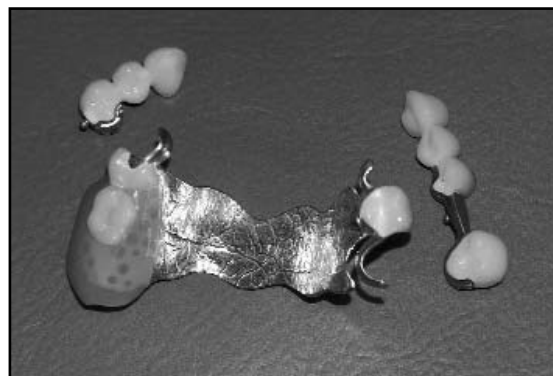


Figure 17. The RPD with the elements of tooth support

The milled crown offers the potential for good support down the long axis of the supporting tooth and, if planned well, prevents coverage of the gingival mucosa by the major connector. A part of the indirect retainers are represented by some of the tooth-support elements (the opposing arms on the stress distributors and the interlocks) also serving to obtain an increased stability of the denture (*Figures 16, 17*).

The absence of the indirect retainers from the denture design shall have at least two major disadvantages as regards the retention:

1. we would not have a stopper opposing the rotation of the free-end saddle, movement that cannot be avoided due to the difference between the two support types (the saddle is tooth-supported medially and

the mucosa and bone supported distally);

2. due to this movement, the prosthesis shall traumatize the tissues.

The use of guide plans for the resilient snap attachment supposes realization and milling of the crowns on the abutment teeth in the insertion-withdrawal path, therefore the modification of the coronary preparation to include the guide plan at a certain path and the stress distributors for the opposing arms. Obviously, we have to accentuate the reducing of the abutment tooth in these areas. This maneuver shall improve both the retention and the aspect of the denture, as we know that its esthetic limit is between the last abutment tooth and the first artificial tooth. The use of guide plans shall shrink to the maximum this less esthetic space (*Figures 18, 19*).

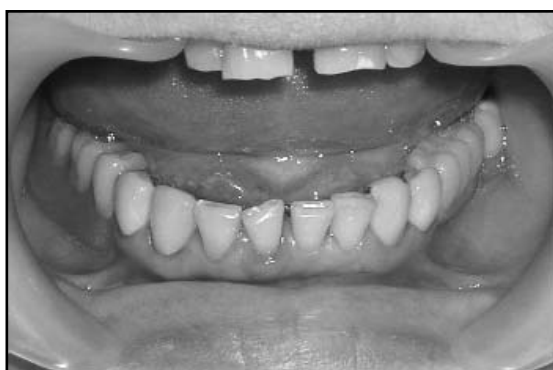

Figure 18. The esthetic appearance of the saddles when the guide plans are used in the design

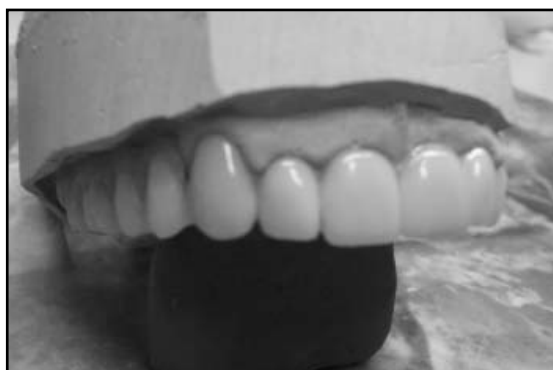

Figure 19. When we use the guide plans we can put the first artificial tooth in the closest position

It is necessary to analyze the bone undercuts on the study and diagnosis casts using the parallelometer and to harmonize them with the insert-withdrawal path of the future denture [4]. Obtaining the retention of the partial denture with resilient attachments in the Ist and IInd class Kennedy of edentulism is of course complicated by the different type of support of the saddles in the absence of the distal abutment tooth. Obtaining a retention that besides being efficient is to also be esthetic is even more difficult as the dimension of the free-end saddle is increasing in anterior direction (*Figure 20*).

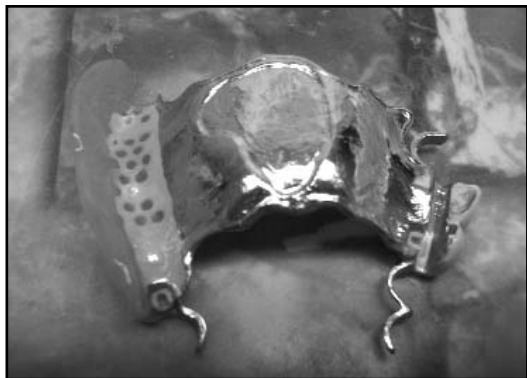

Figure 20. Long free-end saddle

If retention and stability are not sufficient, the patient shall use prosthesis adhesives, this leading to accumulation of bacterial plaque, thus to the increase of the cavities and periodontal disease risks on the remaining teeth as well a poor prosthesis hygiene.

If the patient is selecting a mobile prosthesis with resilient snap attachment as treatment plan, he has to have good oral hygiene and mobility within the physiological limits of the abutment teeth [5]. Oral cavity draining is surely necessary. If the patient already wears a partial prosthesis, examining the old prosthesis proves its utility, offering valuable information regarding the retaining, support and esthetics. Preparation of study and diagnosis casts is

also mandatory, as well as examination both individually and mounted in correct inter-maxillary relationship. This allows the examination of the occlusion and occlusion plan, usually unlevelled due to vertical and horizontal migrations consecutive to incorrect fixed treatments or long time untreated partial edentulism.

The dentist cannot design a functional, correct and esthetic prosthesis with resilient snap attachment unless he first achieves an occlusion plan level. We have to analyze completely the study casts on the parallelometer where the insertion-withdrawal path is established. All components of the mobile prosthesis with resilient snap attachment shall be prepared having into account the established insertion-withdrawal path, both the fixed elements cemented on abutment teeth and the mobile elements themselves. In this manner, we will obtain functionality and esthetics, as well as superior biological integration.

The abutment teeth on which retaining elements are prepared (unified crowns) has to have a sufficient coronal height to allow obtaining the vertical space necessary both on the occlusive area and approximately distal on the patrix placement area. The radiological exam is mandatory for the teeth and also a vitality test eventually. When there are doubts on the vitality of an abutment tooth, it is preferably to make the endodontic treatment, prior to preparation of the prosthesis. Provisory restorations are useful in the mandatory occlusive plan leveling, on which we can make adjustments and interventions to obtain the desired levels. The crowns covering the abutment teeth are poured together with a prefabricated castable component (matrix or patrix, depending on the producer) mandatorily being provided with stress distributors for the opposing arms and the interlocks and guide plans to optimize prosthetics stability, retaining and esthetics.

The clinician must establish the insertion-withdrawal path at parallelometer, and must not leave this task to the dental technician (*Figure 21*). With the help of the parallelometer, the dentist is referring and dimensioning all the dental or bony undercuts. If the denture is gaining its retention by using spherical snaps attachments, to cover the abutment teeth with micro-prosthesis shall be mandatory (*Figure 22*). The dental technician must prepare these crowns by parallelometer milling the wax in the insertion-withdrawal path, this solving the dental interferences with the abutment teeth undercuts. Conventionally, the dentist should select the insertion-withdrawal path as vertically as possible due to the increase commodity offered to the patient.

In the absence of the guide plan, the insertion path should be like or coincide with the withdrawal path. Patients tend to apply and extract the prosthesis vertically, and choosing an insertion path largely deviated from the vertical plan can cause difficulties, specifically to the disabled patients having decreased dexterity. Exaggerate linings of study casts on parallelometer also create false retaining areas, lowering in fact the action of the retaining elements. In exchange, including the guide plans in the design of the prosthesis ease the sliding of the denture on the mouth in the insertion path along those oral milled areas, and only

in this position. Preparation of the guide plans on the crowns placed on the abutment teeth allows only one insertion-withdrawal path. In this way, the retainers (the snap) shall resist to the detachment movements that may appear only on one direction, namely on the range of the withdrawal path.

Preparation of the crowns should ensure sufficient occlusal space, reason for which the occlusal table of the abutment teeth shall be anatofomally reduced. The clinician must bevel the occlusoapproximal edges to secure a better adaptation of the crown on the abutment tooth. The form of the preparation should be cylinder-conical to ensure friction. The lingual or palatal surface of the crown shall have preparations for stress breakers (for the opposing arms) prolonged to the approximal area (for the interlocks) to secure tooth support, stability and indirect retention.

The crowns shall have guide plans to increase retention and to limit the withdrawal path to only one. The guide plans prevents the rotational movements and increase snap efficiency. Due to preparation of the guide plans, the tooth shall need a supplementary reduction in this area. Being an extra-coronary system, the snap does not transmit forces along the long axis of the tooth. For physiological transmission of occlusal and chewing pressures in the long ax of the abutment tooth, it is necessary to prolong the



Figure 21. Milling the crowns and bridges on the parallelometer




Figure 22. Transfer of the precise abutment position using the spider key

preparation of lingual or palatal stress distributors up to the approximal area. Supplementary reduction of crown's dimension on the lingual or palatal face (in order to prepare the milled stress distributors) is preventing the over contouring of the abutment teeth crown, thus the appearance of an undesired undercut area. The patient's tongue is sensing this area as a discomfort. Between the R.P.D. and these guide plans, opposing arms and interlocks also appears a certain friction degree, this contributing to the retention of the denture.

Both the snap and the stress distributors prevent the exaggerate clogging of the prosthesis. The clogging is generating undesired effects on the subjacent tissues (hard and soft) well known from the interim partial denture that loses quickly its tooth support. This way the design of the denture is preventing both trauma of the mucosa and rapid resorption of the alveolar bone, as well as torsion and other disorthodontic effects in the remaining teeth. Due to use of the milled crowns, the depth of stress distributors' preparations may be so that they would be functionally efficient, protecting at the same time the abutment tooth. The angle between the denture and the abutment teeth crowns during the functional load is very important to be of 90° or less.

Results

If the prosthesis is designed with guide plans, the path of insertion will be the same with the path of withdrawal, and the retainers should resist to voluntary and involuntary detachment and dislodgement only along this path, thus in a single direction. If the prosthesis does not have a unique path of insertion-withdrawal, the patient would insert and withdraw it in different positions that would finally distort and destroy the precision attachments. The R.P.D.'s incorrect design can lead, under the functional load, even to snap's metallic matrix fracture.

Discussion

Use of the parallelometer in a treatment plan allows the consideration of guide plans, undercuts and insertion path. In order to obtain a maximum functionality and an optimum esthetics, it is necessary to design the denture using the parallelometer this allowing the increase of retention, support and stability.

The snap partial denture is a versatile method of treatment, with a correct cost-efficiency rate and recommended for patients of all ages. The trends in modern dentistry have changed over the last 20-30 years in favor of maintaining as long as possible the natural teeth on the arch and thus of decreasing the total denture rate. The goals of partial denture as a method of treatment are of course the recovery of the functionality, the improvement of esthetics and, most importantly, keeping the health of the tooth, mucosa and bone structures on a long-term basis.

Conclusions

The indirect retainers are increasing the retention of the R.P.D. with snap attachments and are precluding the fracture of the attachment. If the clinician is designing the denture without indirect retainers, it will quickly lose part of the tooth support and the plastic components will be prone to change frequently. The indirect retainers design is protecting the edentulous ridge to accelerate resorption. Treating the edentulous patients with different clinical situations (IIInd and Ist class Kennedy) with a snap resilient partial denture (R.P.D. with spherical attachments) is at the same time a functional and versatile method of design that also offers long-term stability. It is necessary for the patient to return to the dental office on a regular basis to change the used resilient component of the system and to reline the saddles in order to regain the initial functional characteristics.

References

1. Andrei OC. Restaurari protetice cu caracter fizionomic in edentatiile partiale intinse. Editura Cartea Universitara, Bucuresti, 2005; pp. 122-165.
2. McGivney GP, Carr AB. McCracken's, Removable Partial Prosthodontics. Tenth Edition, The C.V. Mosby Company, ST. Louis, Toronto, Princeton, 2000; pp. 143-151.
3. The glossary of Prosthodontic terms, Academy of Prosthodontics, 1999.
4. Ionescu A. Tratatamentul edentatiei partiale cu proteze mobile. Editura National, 1999; pp. 58-77.
5. Davenport JC, Basker RM, Heath JR, Ralph JP, Glantz OP. A Clinical Guide To Removable Partial Dentures. British Dental Association, London, 2000; pp. 3-14.

Correspondence to: Dr. Oana-Cella Andrei, DMD, Assist. Prof., Department of Removable Prosthodontics, Faculty of Dental Medicine, "Carol Davila" University of Bucharest. Address: Brândusilor str., no. 7, bloc G3, sc. 1, ap. 1, sector 3, Bucuresti, Romania. E-mail: cellaan-drei@yahoo.com