

Clinical Outcomes of Conversion Surgery from an External Fixator to an Iodine-Supported Titanium Alloy Plate

Hidegori Matsubara, Toshiharu Shirai, Koji Watanabe, Issei Nomura and Hiroyuki Tsuchiya*

Department of Orthopaedic Surgery, Graduate School of Medical Science, Kanazawa University, Japan

Abstract

Background: External fixators brought a revolution in orthopaedic surgical treatment after the invention of distraction osteogenesis, which enabled treatment of various difficult diseases. However, they had some drawbacks, such as pin-site infections, psychological pain, and refracture after removal. To overcome these problems, many efforts have been made by shortening of the period of wearing them. One of those methods is conversion to locking plate, which had high risk of infection. To reduce the risk of infection, we performed conversion surgery using iodine-supported titanium plate (We named it iPlates, developed at our department).

Questions/purposes: We therefore evaluated (1) Operation time, (2) whether bone union was achieved, (3) blood biochemistry, including thyroid hormone levels, (4) post-surgical complications.

Patients and Methods: We assessed 28 legs. There were 13 legs after deformity correction and limb lengthening, three legs with pseudarthrosis after bone fracture, two legs after bone transport, one leg after shortening distraction, and one leg after open fracture. The mean follow-up period was 24.5 months.

Results: Average operation time was 197 minutes. Bone union was achieved in all cases. Blood examinations did not find any abnormalities due to implant implantation, such as with thyroid hormones. One patient had superficial soft tissue infection treated with re-operation without removal of plate.

Conclusions: An iPlate can reduce complications compare to previous studies. Conversion surgery with iPlate could be a new path for the future of external fixation.

Keywords: Iodine-supported; Titanium plate; Conversion surgery; External fixator; Nonunion; Limb lengthening

Introduction

External fixators brought a revolution in orthopedic surgical treatment after the invention of distraction osteogenesis by Ilizarov GA in the 1950s [1]. Devices of external fixator continued to be developed thereafter, enabling treatment of various diseases which had been difficult to treat. These devices have been used for various conditions such as trauma, infection, limb lengthening, deformity correction, joint mobilization, and bone defect reconstruction [2-4]. In this way, external fixators are highly useful treatment devices which are indispensable in orthopedic surgical treatment at present. Recently, however, locking plate has been developing remarkably, and replacing treatment of external fixator.

What is the future of external fixation? When addressing this question, it is necessary to consider current issues with external fixators and treatment in which they are used. Issues include inconveniences such as pin-site infections, bulky external fixators, patients' psychological pain, and re-fracture after removal [5,6]. In order to overcome these disadvantages, devices such as antibacterial pins and wires [7], extendable implants [8], and simpler software have been developed, and they are currently being applied in some clinical situations. Meanwhile, efforts have been made with the aim of indirectly overcoming such disadvantages, not by the above direct means, but by shortening the period of wearing external fixators as much as possible. One such indirect measure is a method which aims to shorten the period of wearing external fixators by stimulating bone formation through cells, proteins, scaffolds, and mechanical stimulation. Another method is shortening of the period of wearing external fixators through parallel use of internal fixation materials and conversion to internal fixation materials [9]. There have been several reports on

surgery for conversion to intramedullary nails [10,11]; however, this method is difficult to be applied in cases with complex bone formation, such as in a condition after deformity correction, and issues in such cases have been reported in that intramedullary infection was caused, making treatment difficult [6]. Since locking plates started being used at the beginning of the 21st century, there have been several reports on surgery for conversion to plates with a concept of external fixation in the body. However, an external fixator removal site is connected to outside the body, and inserting internal fixation materials into the site raises concerns over infection risks; therefore, this method still has not been generally accepted as a therapy [12-14].

We were successful in creating an iodine-supported titanium alloy implant (iImplant), which has antibacterial action. Our department uses iImplants, and has been achieving good outcomes in clinical studies in patients with a high risk of infection and in those with a history of infection [15]. We have started using iImplants in performing surgery for converting external fixation materials, which have a high risk of

***Corresponding author:** Hiroyuki Tsuchiya, MD, Ph.D., Department of Orthopaedic Surgery, Graduate School of Medical Science, Kanazawa University, 13-1 Takara-machi, Kanazawa 920-8641, Japan, Tel: +81 762652374; Fax: +81 762344261; E-mail: tsuchi@med.kanazawa-u.ac.jp

Received December 09, 2013; **Accepted** January 07, 2014; **Published** January 10, 2014

Citation: Matsubara H, Shirai T, Watanabe K, Nomura I, Tsuchiya H (2014) Clinical Outcomes of Conversion Surgery from an External Fixator to an Iodine-Supported Titanium Alloy Plate. J Microb Biochem Technol 6: 049-053. doi:10.4172/1948-5948.1000121

Copyright: © 2014 Matsubara H, et al. This is an open-access article distributed under the terms of the Creative Commons Attribution License, which permits unrestricted use, distribution, and reproduction in any medium, provided the original author and source are credited

infection, to internal fixation ones. The present report is on treatment outcomes of surgery converting from external fixators to iodine-supported titanium alloy plates.

We therefore evaluated (1) Operation time, (2) whether bone union was achieved, (3) blood biochemistry, including thyroid hormone levels at postoperative 1, 2, 4 week, 3 month, and 6 month, (4) post-surgical complications.

Patients and Methods

We retrospectively reviewed 27 cases with 28 limbs that underwent surgery at our hospital in the period from February 2009 to May 2012. There were eight femurs, 19 tibiae, and one ankle. The mean age was 35 years (11-82 years). Thirteen limbs were in cases where surgery was planned following deformity correction/ bone lengthening, seven limbs had pseudarthrosis following deformity correction/ bone lengthening, three limbs had pseudarthrosis following fracture, two legs after bone transport, 1 leg after shortening distraction, and one leg after open fracture. The external fixator used in all cases was a Taylor Spatial Frame (TSF). The period for wearing the external fixator before conversion surgery was a mean of 175 days (8-1175 days). Autologous bone graft was also performed in 11 limbs with pseudarthrosis and in one limb with a bone transport docking site. The mean follow-up period was 24.5 months (13 - 54 months).

Iodine support

Iodine support is a technology of forming an approximately 8 μ m-thick oxidized film on a titanium implant surface, on which multiple micropores with diameters of approximately 10 to 30 nm are created, and filled with iodine [14] (Figure 1). Iodine exists in the human body in an ionic form, and is non-toxic; it has a broad antibacterial spectrum, and does not give rise to resistant bacteria [16]. The sizes and lengths of plate and screws are obtained by the presurgical planning, and pre-manufactured implants are covered with iodine by iodine support technique prior to surgery.

Surgical method

Sufficient presurgical disinfection is carried out on devices, including external fixators. Spraying is used to disinfect external fixators. Subsequently, external fixators are separated from the surgical field as much as possible (Figure 2). Plates are fixed through the minimum invasive plate osteosynthesis (MIPO) method in cases in which surgery is performed as a plan after deformity correction and limb lengthening; therefore, skin incisions are made proximally and distally at a site between bone lengthening/ deformity correction site. In the case of pseudarthrosis, since it is necessary to refresh the pseudarthrosis site and to perform bone graft, skin incision is performed along the total length of the site where the plate is to be fixed. When at least two locking screws are inserted proximally and distally, an external fixator is removed. At the time of the removal, the wound part is sufficiently isolated. Thereafter, the necessary number of screws is added to each of the proximal and distal sites. It is checked whether the alignment has changed or not under image intensifier; and at the end of the procedure, sufficient washing using saline is performed, a drainage tube is placed and left indwelling, and the wound is closed.

Blood chemistry examination

The levels of thyroid hormones in the blood, thyroid-stimulating hormone (TSH), free triiodothyronine (FT3) and free thyroxine (FT4) were examined to determine if iodine from the implant influenced

physiological activities. Both examinations were conducted regularly for 1 year.

Results

Average operation time was 197 minutes (85- 345 minutes). Bone union was achieved in all cases. Blood examinations did not find any abnormalities due to iImplant implantation, such as with thyroid hormones. No change in alignment was observed due to conversion. One patient had superficial soft tissue infection treated with re-operation without removal of plate.

Representative Cases

Case 1: A case of conversion following tibial lengthening

The patient was a 62-year-old male with diabetic. He suffered from left tibial/ fibular proximal open fracture (Gustilo Type 3b) by agricultural tilling machine (Figure 3). Emergency surgery was performed on the same day; irrigation and debridement, K-wire pinning, shortening, fixation with a Hoffman external fixator and artificial dermal transplantation were performed. Thereafter, irrigation and debridement was performed two times due to infection. The patient was referred to our department three months after injury, when the infection was somewhat reduced. An approximately 6cm limb length discrepancy when the patient visited our hospital and a skin defect were observed on the lateral side at proximal tibia (Figure 4). In the first surgery, a TSF was employed from Hoffman external fixator, and osteotomy was performed on the diaphysis part for postsurgical limb lengthening. 6cm of post-operative limb lengthening was performed gradually to even length of the legs (Figure 5). Since the patient had strong discomfort due to external fixation, iPlate conversion surgery was performed five months after the first operation. The operation involved conversion to a locking plate with the abovementioned

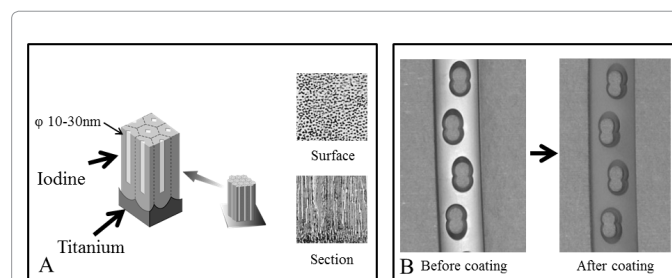


Figure 1: (A) Surface structure of implant. Oxidized film on a titanium implant surface was formed, on which multiple micropores are created, and filled with iodine. (B) Surface color changes to gray after iodine supporting. Before coating (Left), after coating (Right).

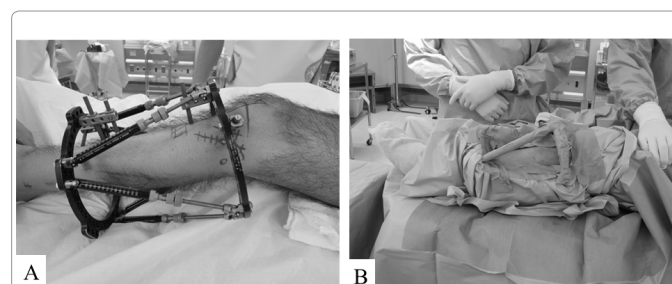


Figure 2: (A) Outside appearance with an external fixator before operation. (B) Outside appearance after isolation of external fixator with draping.

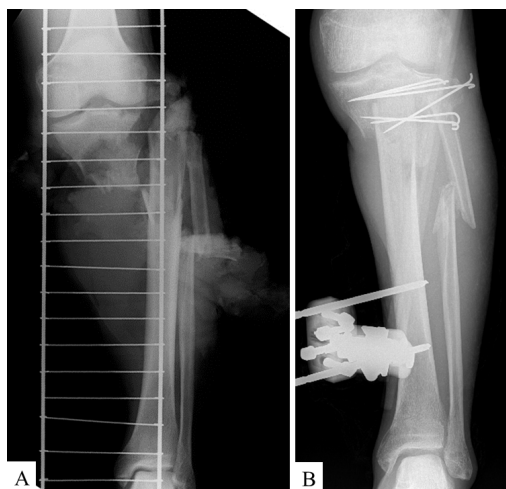

Figure 3: Case 1. (A) Proximal tibial fracture was observed on X-ray at the accident. (B) Emergency operation was performed with shortening, K-wire pinning, and fixation with Hoffmann external fixator at the same day as the accident

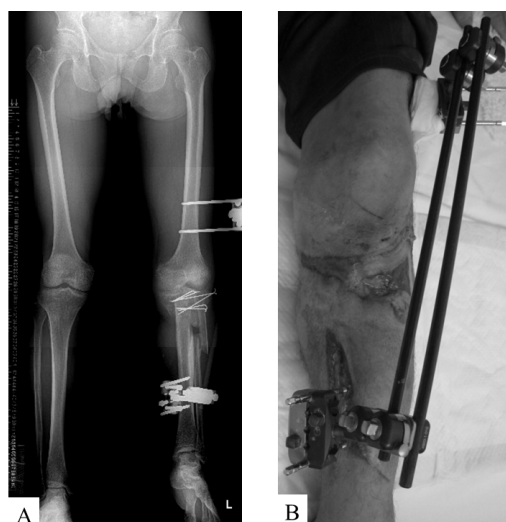

Figure 4: Case 1. (A) Approximately 6cm limb length discrepancy was observed at the first visit of our hospital. (B) Skin defect was observed on the lateral side of proximal tibia at the first visit of our hospital.

method. No signs of infection were observed post-operatively, bone union was observed on X-ray approximately two months after the conversion, and at present, eight months after conversion surgery, the patient can walk on his own (Figure 6).

Case 2: A case of tibial pseudarthrosis

The patient was an 18 year-old male who underwent chemotherapy and surgery (marginal excision + bone transport + allograft) for an osteosarcoma in the right proximal tibia at the age of 13 years. In postoperative 9 month, docking site pseudarthrosis was observed, and autologous bone transplantation was performed. It was determined that bone union was achieved one year and four months following the operation, and external fixator was removed (Figure 7). However, since bone union was not achieved at the pseudarthrosis site, and as gradually increasing instability was observed, plate conversion and

autologous iliac bone graft was performed two years following the operation. Bone union at the pseudarthrosis site was still not observed, the plate became exposed, there was tibial anteversion, and the lower limbs were shortened. In addition, fracture was observed in distal to the plate; therefore, plate was removed, and a TSF was installed. Deformity

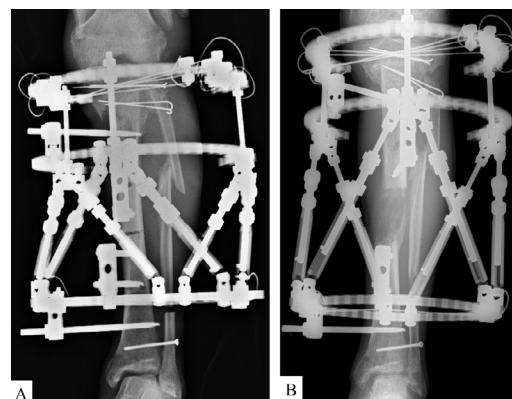


Figure 5: Case 1. (A) TSF was applied and osteotomy was performed at the diaphysis of left tibia at the first operation. (B) 6cm limb lengthening was done and good lengthening callus formation was observed.

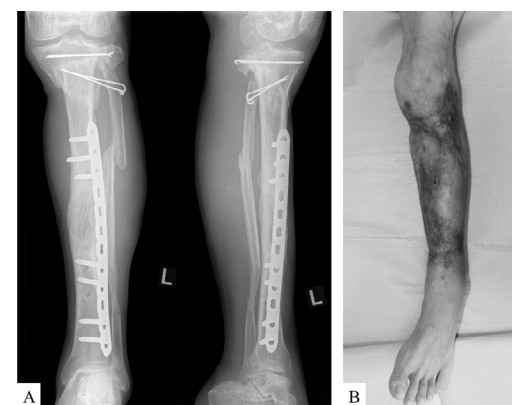

Figure 6: Case 1. (A) Consolidation of lengthening callus was observed eight months after iPlate conversion. (B) There was no infectious sign on clinical photograph.

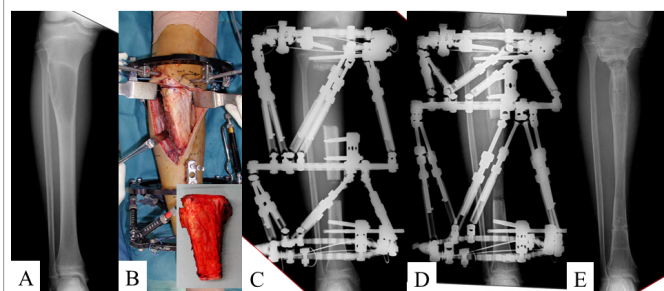


Figure 7: Case 2. (A) Bone absorption was detected on X-ray and revealed osteosarcoma by open biopsy. (B) Marginal excision was done and TSF was applied for bone transport. (C) Callus formation was found at the bone transport site. (D) Docking of bone transport segment was completed. (E) External fixator was removed by the judgment that enough bone union was achieved.

correction and limb lengthening were gradually performed post-operatively (Figure 8), the abovementioned methods were performed at the time when good alignment was achieved, and iPlate conversion and autologous iliac bone graft were performed (Figure 9). At present, two years and two months after iPlate conversion, good bone union has now been achieved, and the patient can now run (Figure 10).

Discussion

An external fixator is a highly useful medical device in orthopedic treatment; however, surgeons and patients may avoid and dislike them due to disadvantages and complications specific to them. However, there are some cases in which only an external fixator can be used for treatment, or in which an external fixator can make treatment easier. In order for external fixators to further develop, taking into account their future possibilities, it would be favorable to have a technology which could decrease various complications in relation to such devices, and which can shorten the period during which the patient has to wear one. The longer the period during which a patient has to wear an external fixator, the higher the risk of them suffering from complications

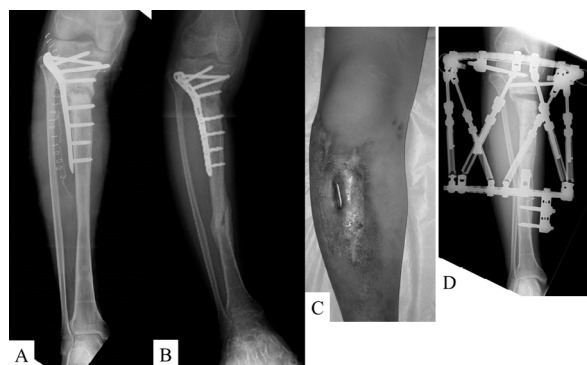


Figure 8: Case 2. (A) Plate conversion with conventional locking plate was performed with iliac bone grafting. (B) Varus deformity was gradually deteriorated at the nonunion site and the fracture was occurred at distal site of plate. (C) Exposure of plate was observed. (D) TSF was applied, deformity correction and limb lengthening was performed postoperatively. Good alignment was achieved.

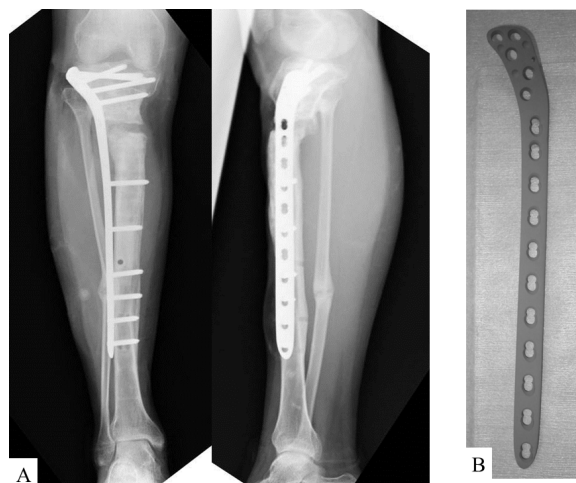


Figure 9: Case 2. (A) TSF was removed after iPlate conversion with iliac bone grafting. (B) Appearance of iPlate for lateral proximal tibia.

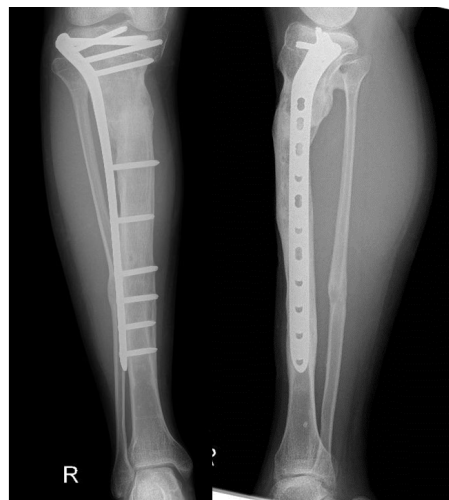

Figure 10: Case 2. X-ray at 2 years and 2 months after the operation. Bone union was completely achieved and good alignment

accompanying it. In other words, if it is possible to shorten the period during which the patient has to wear an external fixator, it will be possible to reduce the psychological and physical burden on the patient, and also to reduce complications. Conversion to internal fixation materials is one of the solutions for reducing complications. Also, re-fracture following external fixator removal, which is a major complication with external fixators [6], can be prevented through plate conversion. Meanwhile, there is a report that states that this conversion operation has a high risk of infection because of the pin insertion site communicating with the outside the body [12].

There are some limitations to our study. First, it is a retrospective study. Second, the study has small number of patients. Third, it is not comparative study. Four, there is no functional and psychological assessment.

In the present study, we used iImplants and performed conversion to internal fixation materials from external fixators, which have a high risk of infection, and bone union and good outcomes were achieved without any cases of severe infection observed. It was considered that the reason for such good outcomes being achieved was because the iImplant, which has an antibacterial action, prevented bacterial adhesion and growth, stopping a biofilm from being created, allowing antibiotics to permeate into target sites. We considered that this antibacterial effect is the same as that which can be achieved through fixation using an external fixator, and that the iImplant fulfilled its role as internal fixator.

At present, we considered the indication of this iPlate conversion operation to be femoral cases, cases which are expected to wear external fixators for a long period of time, and cases in which the patient strongly wishes to remove an external fixator at an early stage. In femoral cases, there is an extremely great impairment of ADL due to wearing an external fixator on the femur. Moreover, in cases with limb lengthening of long distance and those which are expected to wear an external fixator for a long period of time due to prolonged healing time, conversion operation together with bone graft is extremely useful.

Meanwhile, the most significant disadvantage of conversion operations is considered to be the risk of infection. Further, the fact

that at least two operations are necessary, and the change in alignment accompanying conversion are also considered to be disadvantages [12,17-19]. Naturally, this type of operation should be indicated for cases where the potential advantages are a favorable trade-off relative to the requirement for multiple surgeries. Moreover, in regard to changes in alignment, we removed an external fixator after plate fixation, and it is less likely that an alignment change will occur intraoperatively. There is a report on an alignment change occurring post-operatively during follow-up observation [12]. Since a plate does not have equivalent fixation to that of ring-type external fixators, we provide careful post-operative instructions until the time when a certain degree of callus formation is observed at the limb lengthening part, deformity correction part, or the pseudarthrosis part, in order to prevent alignment change post-operatively.

There have been some reports on conversion operations after fracture damage control; however, the infection rate varies between 5% and 17% amongst reports. There are several cases which progressed to osteomyelitis [17-19]. Moreover, there are some reports on conversion operations following limb lengthening, in the same way as in the present case [9,12-14]; however, it is difficult to evaluate them due to their small number of cases. A report by Harbacheuski, with the largest number of cases, had seven limbs with alignment changes, two limbs with infections, and two limbs with plate breakage, with extremely high complication rates [12]. From amongst our 28 limb cases, one limb was observed to suffer from superficial soft tissue infection; however, no alignment change was observed, and it is considered that good outcomes were achieved. Also, considering the avoidance of complications which could have occurred if external fixators had been continuously worn without conversion, we believe that this operation has advantages which cannot be expressed with data.

When looking at the future of external fixators, one of the issues is reducing complications. In order to resolve this issue, a solution can be to use external fixators for dynamic treatment such as gradual mobilization operations and limb lengthening, followed by static fixation and maintenance with internal fixation materials. The iPlate which we used enables safe conversion operation to be performed, and we consider that it can show a new path for the future of external fixation.

We concluded that iodine-supported titanium alloy plates are extremely useful for conversion operations from external fixators with a high risk of infection, and we believe that their indication will expand going forwards.

References

- Ilizarov GA (1987) The principles of the Ilizarov method. *Bull Hosp Joint Dis* 48: 1-11.
- Paley D, Herzenberg JE, Tetsworth K, McKie J, Bhav A (1994) Deformity planning for frontal and sagittal plane corrective osteotomies. *Orthop Clin North Am* 25: 425-465.
- Tsuchiya H, Sakurakichi K, Uehara K, Yamashiro T, Tomita K (2003) Gradual closed correction of equinus contracture using the Ilizarov apparatus. *J Orthop Sci* 8: 802-806.
- Tsuchiya H, Uehara K, Abdel-Wanis ME, Sakurakichi K, Kabata T, et al. (2002) Deformity correction followed by lengthening with the Ilizarov method. *Clin Orthop Relat Res* 402: 176-183.
- Dahl MT, Gulli B, Berg T (1994) Complications of limb lengthening: a learning curve. *Clin Orthop Relat Res* 301: 10-18.
- Paley D (1990) Problems, obstacles, and complications of limb lengthening by the Ilizarov technique. *Clin Orthop Relat Res* 250: 81-104.
- Holt J, Hertzberg B, Weinhold P, Storm W, Schoenfish M, et al. (2011) Decreasing bacterial colonization of external fixation pins through nitric oxide release coatings. *J Orthop Trauma* 25: 432-437.
- Wang K, Edwards E (2012) Intramedullary Skeletal Kinetic Distractor in the Treatment of Leg Length Discrepancy-A Review of 16 Cases and Analysis of Complications. *J Orthop Trauma* 26: 138-144.
- Kulkarni R, Singh N, Kulkarni GS, Kulkarni M, Kulkarni S, et al. (2012) Limb lengthening over plate. *Indian J Orthop* 46: 339-345.
- Paley D, Herzenberg JE, Parnian G, Bhav A (1997) Femoral lengthening over an intramedullary nail. A matched-case comparison with Ilizarov femoral lengthening. *J Bone Joint Surg Am* 79: 1464-1480.
- Tsuchiya H, Tomita K, Minematsu K, Mori Y, Asada N, et al. (1997) Limb salvage using distraction osteogenesis. A classification of the technique. *J Bone Joint Surg Br* 79: 403-411.
- Harbacheuski R, Fragomen AT, Rozbruch SR (2012) Does lengthening and then plating (LAP) shorten duration of external fixation? *Clin Orthop Relat Res* 470: 1771-1781.
- Oh CW, Shetty GM, Song HR, Kyung HS, Oh JK, et al. (2008) Submuscular plating after distraction osteogenesis in children. *J Pediatr Orthop B* 17:265-269.
- Uysal M, Akpinar S, Cesur N, Hersekli MA, Tandoğan RN (2007) Plating after lengthening (PAL): technical notes and preliminary clinical experiences. *Arch Orthop Trauma Surg* 127: 889-893.
- Tsuchiya H, Shirai T, Nishida H, Murakami H, Kabata T, et al. (2012) Innovative antimicrobial coating of titanium implants with iodine. *J Orthop Sci* 17: 595-604.
- Shirai T, Shimizu T, Ohtani K, Zen Y, Takaya M, et al. (2011) Antibacterial iodine-supported titanium implants. *Acta Biomater* 7: 1928-1933.
- Egol KA, Tejwani NC, Capla EL, Wolinsky PL, Koval KJ (2005) Staged management of high-energy proximal tibia fractures (OTA types 41): the results of a prospective, standardized protocol. *J Orthop Trauma* 19: 448-455.
- Parekh AA, Smith WR, Silva S, Agudelo JF, Williams AE, et al. (2008) Treatment of distal femur and proximal tibia fractures with external fixation followed by planned conversion to internal fixation. *J Trauma* 64: 736-739.
- Yokoyama K, Uchino M, Nakamura K, Ohtsuka H, Suzuki T, et al. (2006) Risk factors for deep infection in secondary intramedullary nailing after external fixation for open tibial fractures. *Injury* 37: 554-560.