

Children frontal teeth rehabilitation without pulp penetration fractures

B. Gheorghita¹, Daniela Gheorghita¹

Suceava, Romania

Summary

Rising frequency of traumatized teeth give us the reason to investigate, diagnose, treat and prevent the effects of trauma. The aim of this study is to establish causes of traumas, clinical aspects in statistic, and modalities of treatment in this kind of injuries. Used material was voluntary subjects, consist in 528 patients with age between 4 and 18 years old, X-Rays, usual rehabilitation materials. Methods consist in clinical examination, with assessment of type of dental lesions, classification of lesions by depth, illustrated methods of rehabilitation. Results and discussions: there are many cases of teeth fractures in a population group, we found a percent 43,75% in our study lot, even the patient doesn't declare a traumatically episode before. A treatment possibility includes odontal methods, prosthetic methods, as well as collage of broken fragment.

Key-words: accidental trauma, dental loss classification, clinical examination, posttraumatic dental rehabilitation.

Introduction

Traumatized teeth treatment and the oral health of children suppose an emergency treatment of traumatized area and continuous supervising of patient. The treatment is a cumuli of clinic and para-clinic dates achieved after clinic and paraclinic exam in loco-regional and general context.

Frontal teeth are strictly related not only with aesthetics but also with child personality and individual character and so the risks of long term injury are important.

Aim of study

Purpose of study was to establish treatment needs for treatment of fractured frontal teeth with no pulp penetration and management steps for rehabilitation with minimum invasive techniques in a selected population group.

Methods

The observational study was made on 528 patients with age between 4 and 18 years old, split in four specific groups due to provenience. 231 patients had been discovered without pulp exposure fractured teeth associated or not with other oral lesion. For all patients we indicate radiological exam to observe amplitude of the tooth fracture (fig.1) [1, 6, 7,12].

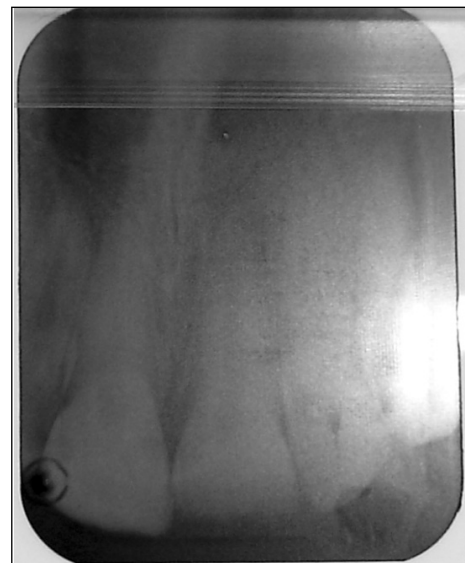

Figure no.1

The age and sex distribution of the four groups was:

4-7 years old - 23 children (13 boys and 10 girls);

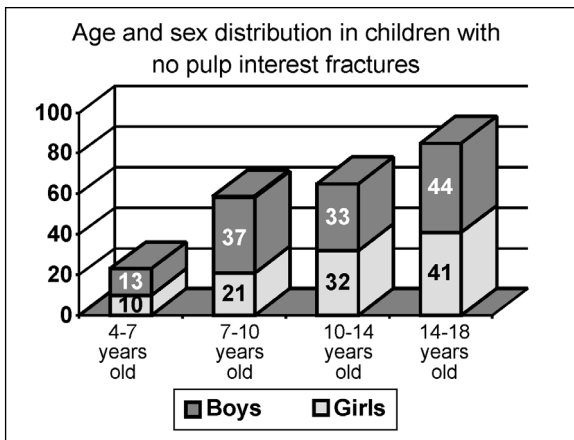
7- 10 years old - 58 children (37 boys and 21 girls);

10- 14 years old - 65 children (33 boys and 32 girls);

14- 18 years old- 85 children (44 boys and 41 girls), *graphic 1*.

¹ DMD, student PhD, Faculty of Dental Medicine, University "Gr.T.Popa" Iasi

We observe that boys are more exposed to traumatic agents:



Graphic no. 1

Clinical exam algorithm is the same as for any oral disease and was corroborating with paraclinic exam. We gave a special attention to anatomical predisposing factors for traumatic lesion like: severe dental crowding in frontal area, short upper lip, overjet deficiency, oral breathing, atypical swallow, things interposition. Diagnostic decision was followed by emergency dental treatment and then individualized definitive treatment. [13, 16, 17, 27, 29]

Inclusion criteria were presence of signs and symptoms of traumatic lesion of frontal teeth and oro-facial dysfunction and exclusion criteria were absence of traumatic signs or symptoms or other area affected not frontal which were our aimed study.

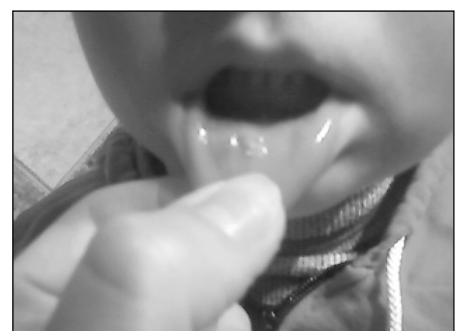
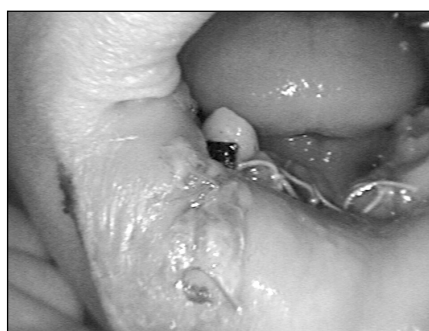
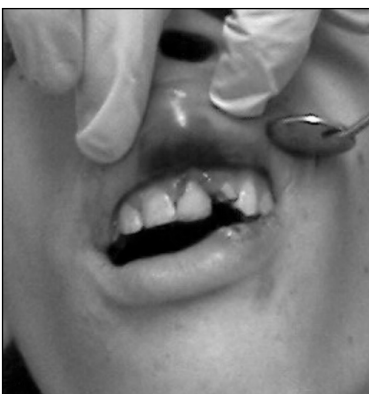
Figure no. 2

Table no. 1. Frequency in lot of study

	Total		Girls		Boys	
	No.	%	Nr.	%	No.	%
4- 7 years old	23	9,95%	10	4,32%	13	5,6%
7- 10 years old	58	25%	21	9%	37	16%
10- 14 years old	65	28%	32	13,8%	33	14,3%
14- 18 years old	85	36,8%	41	17,7%	44	19%

Results and discussions

Posttraumatic rehabilitation of frontal teeth became a problem because of insufficient approach in specialty literature and we consider systematization and therapy as necessary. Most of facial lesions interest not only the teeth but also the cheek, lips or tongue. Tumefaction, ecchymosed tissues and wound with substance lose are usually correlated with traumatism (fig. 2) [34, 30].

The treatment was related with severity of lesion and strict rules are applied.

I. In case of fracture class I Eliss (fissure), observed by transillumination (figure 3) which are very frequent (table no. 1) [2, 4, 8, 21, 25].

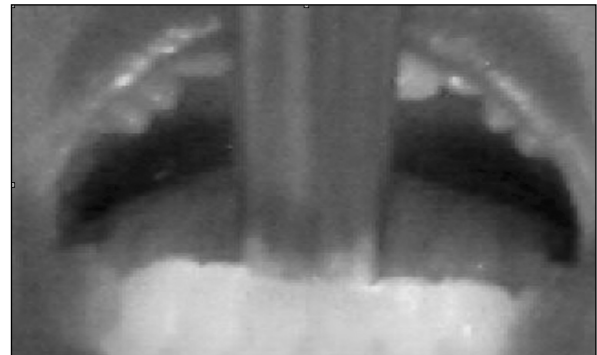


Figure no. 3

➤ Treatment for this class of teeth fractures was similar for temporal or definitive dentition:

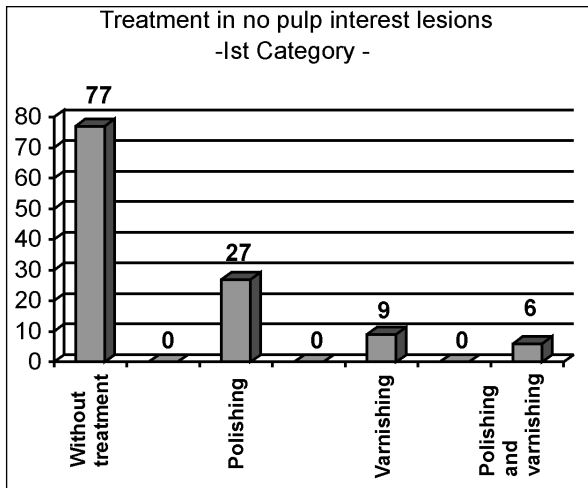
- Removing the irritative post injury area from teeth by polishing the angle or unsustainable enamel prismatic area [2, 14, 22].

• Fluorides appliance (Duraflor, Duraphat, FluorProtector, Alphadent, Cervitec, Seal and Protect Detrey, Smart Fluorid Detax,) or varnish for desensitization and reducing cavity risk (figure 4) [31, 32, 33].

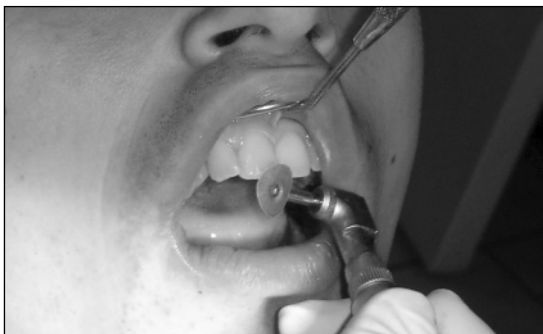
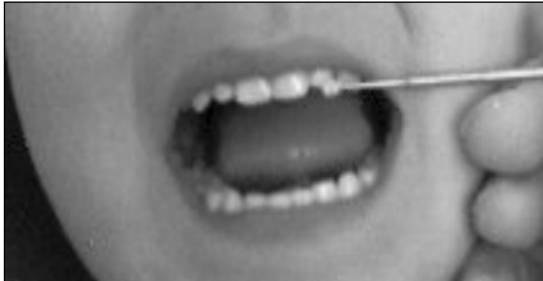
Figure no 4

➤ *Applied treatment.* Treatment was applied only to 42 children because of difficulty to prove to the child or even parents necessity of dental treatment (graphic 2).



Graphic no.2

II. Traumatized teeth in class II Eliss were find in 31% cases of children who suffer an accident. Also parents can relate tooth fracture with the minor injury while playing, walking or performing a sport. We discover an important increased percent of traumatized teeth to 10-18 years old.

➤ *Frequency in lot of sudy (Table no. 2)*

➤ *Treatment protocol was:*

- Enamel polishing
- Fluorides appliance
- Rehabilitate the tooth aesthetics with composite or glass ionomer (fig.5)
- Desensitization of dentine
- Rehabilitation of incision and phonetic function [15, 23, 24]

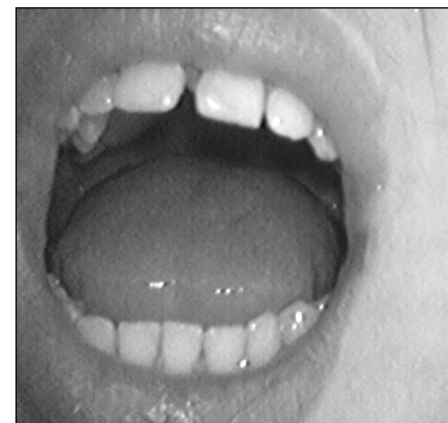
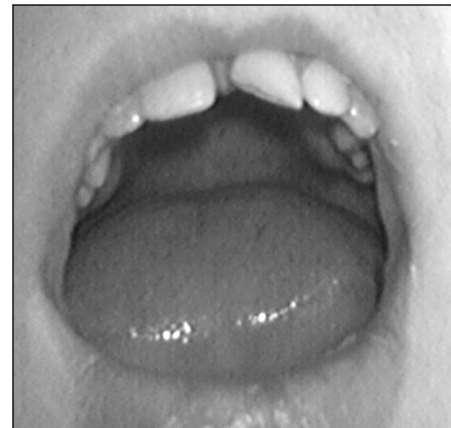

Figure no. 5

➤ *Applied treatment.* Treatment for this type of lesion is predominating reconstructive but 25 children refuse to accept treatment.

Table no. 2. Frequency in lot of sudy

	Total		Girls		Boys	
	No.	%	Nr.	%	No.	%
4- 7 years old	7	3%	4	1,73%	3	1,3%
7- 10 years old	15	6,5%	3	1,3%	12	5,2%
10- 14 years old	23	9,95%	12	5,2%	11	4,76%
14- 18 years old	27	11,7%	12	5,2%	15	6,5%

III. Class III Ellis fracture with no pulp penetration interest dentin but frequency is more reduce with increased incidence to 14-18 years old girls, (table 3)

➤ Frequency in lot of sudy (Table no. 3):

➤ Treatment. Treatment is either prosthetic, either with filling but is necessary a specials attention to pulp chamber (which is bigger less mineralized and with larger channels than adult tooth) [3, 18, 26].

Treatment protocol is more complex than previous because of pulp protection.

The dental fillings ensure aesthetics but not resistance especially when the fracture line destroyed tooth angles. In such case we used celluloid cape or para pulp screw and a special methods which include the fractured fragment like in figure 6, 7, 8.

Prosthetic treatment is more complex and is applied to psychological equilibrated child. We used a large area of techniques from inlay, edge-up crown, veneers to crown (fig 9, 10, 11).

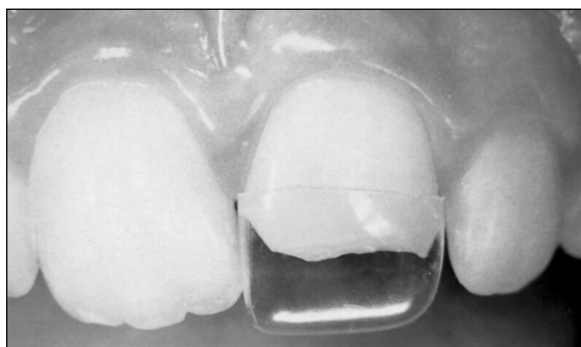

Figure no. 6

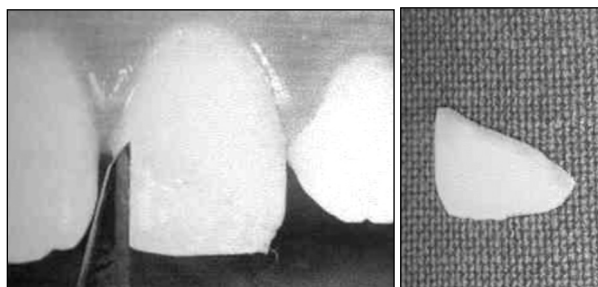


Figure no. 8

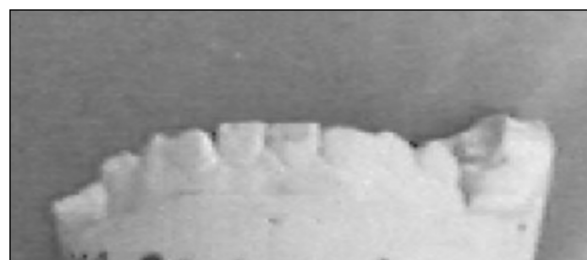
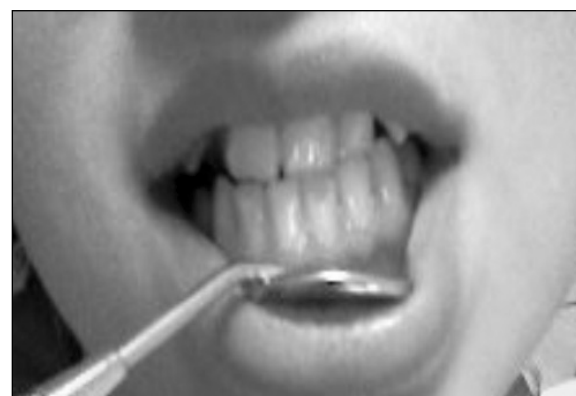
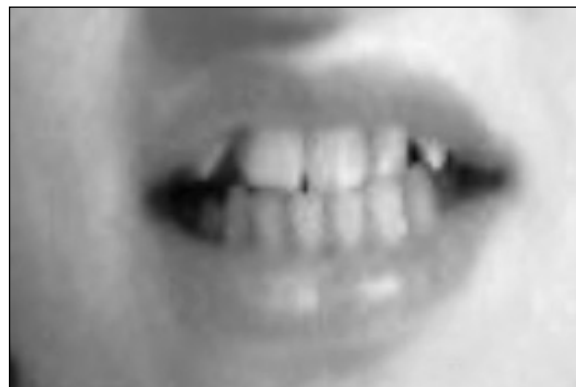
Figure no. 9

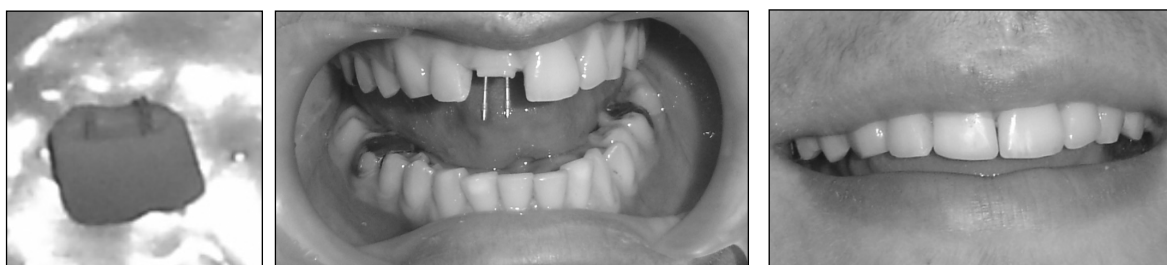


Figure no. 7

Table no. 3 Frequency in lot of sudy

	Total		Girls		Boys	
	No.	%	Nr.	%	No.	%
4- 7 years old	3	1,29%	1	0,4%	2	0,86%
7- 10 years old	9	3,9%	3	1,29%	6	2,6%
10- 14 years old	6	2,6%	3	1,29%	3	1,29%
14- 18 years old	7	3%	5	2,16%	2	0,86%

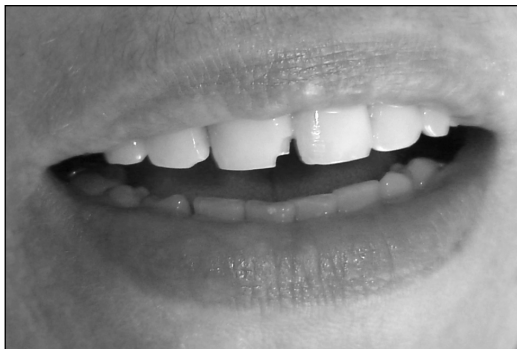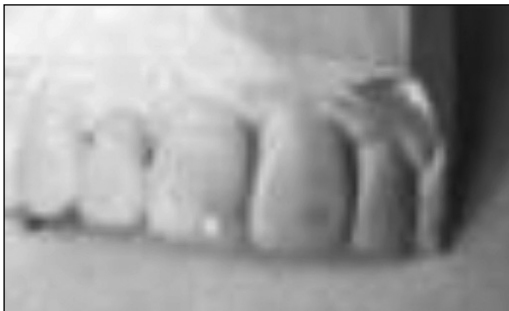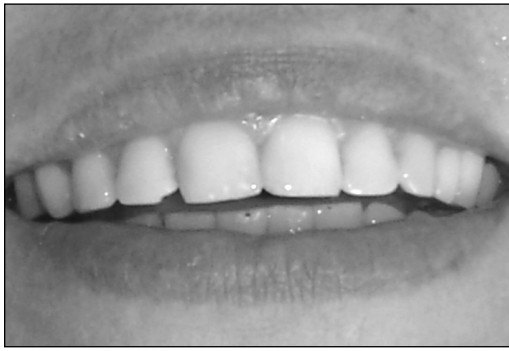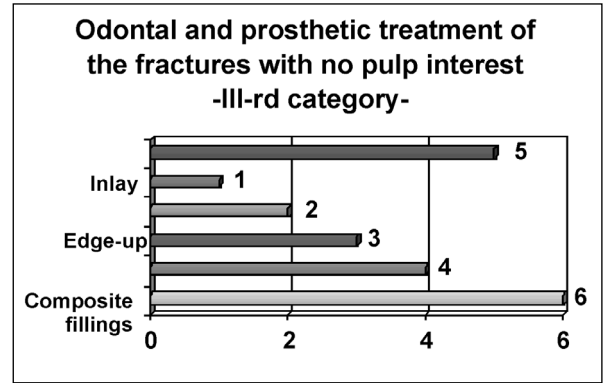


Figure no. 10

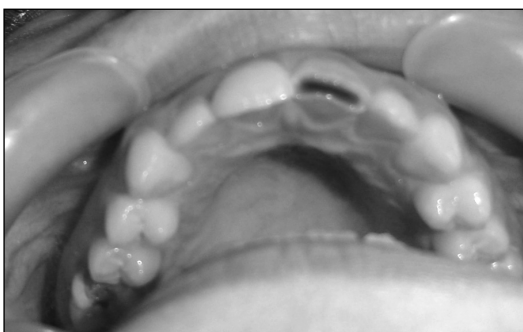
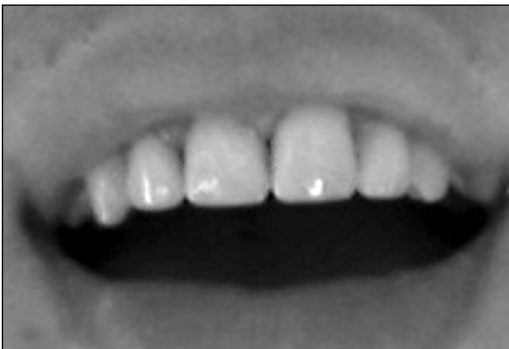
Figure no 11

➤ *Applied treatment.* These methods were applied to children on permanent dentition and were mainly with fillings and crowns because the other methods were rejected by parents or children due to less knowledge or social reason (*graphic 3*) [9, 10, 19].



Graphic no 3

IV. Treatment algorithm for class IV Ellis when lesion is extended in enamel and dentin with no interest of pulp chamber is more complex and not always conservative with tooth structures. A particular situation is class IV traumatism that interests also tooth root. (fig 12).

➤ *Frequency in lot of sudy:*

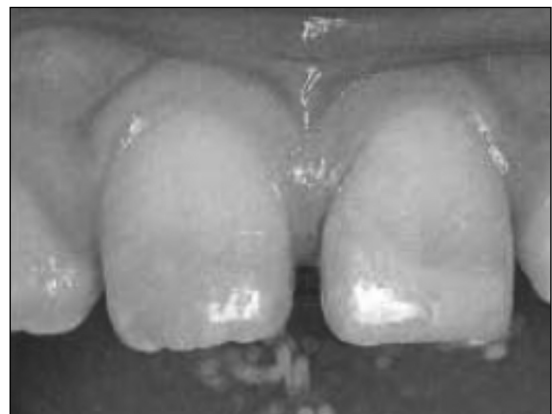
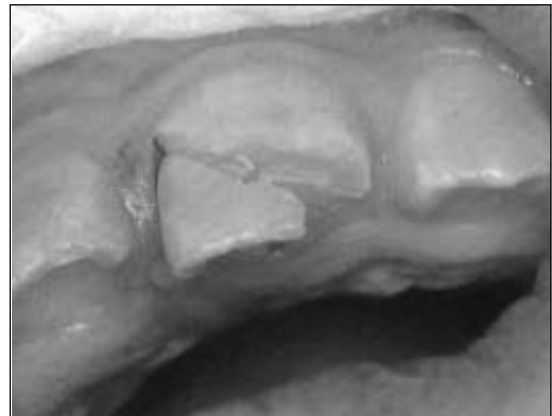
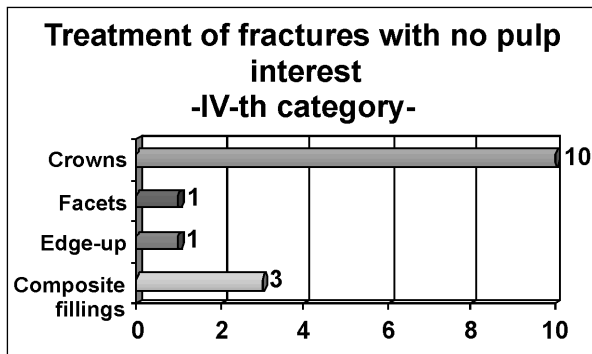


Figure no 12

Table no. 4 Frequency in lot of study

	Total		Girls		Boys	
	No.	%	Nr.	%	No.	%
4- 7 years old	2	0,86%	2	0,86%	0	0
7- 10 years old	7	3%	3	1,29%	4	1,73%
10- 14 years old	3	1,29%	1	0,43%	2	0,86%
14- 18 years old	3	1,29%	1	0,43%	2	0,86%

➤ *Applied treatment.* Treatment was made with celluloid cape and fillings but only for a short period of time. Also as a temporary solution we used screws placed near the pulp chamber, veneers, edge up preparation and for definitive treatment crowns (graphics no. 4).



Graphic no.4

Because of excessive loss of substance and poor retention the tooth vitality is often lost either due to pulp infection either pulp retention with pulp screw.

Teeth traumatism is an emergency, no matter of volume of substance lost. In our study we observe that central incisors are more affected (maxilla 78 %, mandible 8 %) than lateral incisors (maxilla 1,2 %, mandible 9 %) and less than canine (0,3 %) [34, 35]

Also we observe a direct correlation between teeth morphology and fracture line, and teeth

integrity and substance loss. Tooth vitality is also a factor than can contribute to fracture direction. Aspects of tooth apex are also implicated in treatment choice and treatments are selected due to psychological factor and child development.

We appreciate treatment efficiency due to aesthetic and functional criteria after treatment and after a period of time (table 5) [11].

We consider as ideal the score 8, acceptable 8-11 and unfavorable more than 11.

Higher risk was given by marginal imperfect closing, deficient interdental contact point reconstruction higher abrasion degree and time instability color for dental fillings and periodontal retraction and shoulder closing for crowns. Maximum score was obtained by patients with class I fracture and minimum score by those with class III fracture which refuse treatment [5, 26, 36].

Conclusions

- High frequency of dental injury at children and forms variety don't allow us to apply a global therapy but a individualized technique due to age, eruption stage and lesion gravity
- Priority for trauma of teeth with pulp integrity maintained is keeping pulp vitality, especially for tooth in develop with growing roots.
- Atypical preparations for tooth with fracture with no pulp penetration offer us the possibility to maintain tooth vitality and to offer maximum function.

Table no. 5

Criteria	Aspects	Odontal treatment		Prosthetic treatment	
		Initial	After	Initial	After
Aesthetic criteria	1. alveolar arch integrity	1	1	1	1
	2. harmony	1	1	1	1
	3. morphology	1	1-2	1	1
	4. color	1	2-3	1	1-2
Functional criteria	1. aesthetic function	1	2	1	1
	2. phonetic function	1	1	1	1
	3. anterior guidance	1	2	1	1
	4. incision	1	2	1	2

• Treatment plan is strictly related with clinic and paraclinic exam and in most cases was established in common with children tutor due to lack of experience of children and in some cases not related with treatment needs.

References

1. Aldescu C.: Radiologie pentru studenți și medici stomatologi; Editura Polirom-Iași 1998.
2. Andreescu C., Iliescu A.: Compoziția și structura țesuturilor dure dentare; Editura Cerma, București 1995.
3. Andreasen F.M, Andreasen J.O., Bayer T.: Prognosis of root-fractured permanent incisors-prediction of healing modalities. *Endod. Dent. Traumatol.*, 1989, vol 5.
4. Andreasen Jens, Frances Andreasen, Leif Bakland and Marie Therese Flores, *Traumatic Dental Injuries, A Manual*, april, 2003.
5. Andreasen JO, Andreasen FM, Skeie A, Hjorting - Hansen E, Schwartz O. Effect of treatment delay upon pulp and periodontal healing of traumatic dental injuries. A review article. *Dental Traumatol.* 2002; **18**: 116 - 128.
6. Andreasen J.O, Andreasen F.M: Dental Traumatology: Quo vadis? *Endod. Dent. Traumatol.*, 1990, vol 6.
7. Andreasen J.O, Andreasen F.M: Lesiones dentarias traumaticas, Madrid, editura Medica Panamericana, 1990
8. Andreasen J.O, Andreasen F.M: Luxation injuries; Essentials of traumatic injuries of the teeth, 4-ed, Ed Munksgaard International Publishers, Copenhagen, 1994
9. Andreasen F.M, Daugaard J., Munksgaard E.C.: Reinforcement of bonded crown- fractures with porcelain laminate veneers. *Endod. Dent. Traumatol.*, 1991, vol 7.
10. Andreasen F.M, Flugge F., Daugaard J., Munksgaard E.C: Treatment of crown fractures incisors with laminate veneer restorations. An experimental study. *Endod. Dent. Traumatol.*, 1992, vol 8.
11. Andreasen F.M, Noren I.G.,Andreasen J.O.: Long term survival of fragment bonding in the treatment of fractured crowns. A multicenter clinical study. *Quintessence Int.*, 1995, vol 26/10.
12. Andreasen J.O, Andreasen F.M: Root fractures; Textbook and color atlas of traumatic injuries of the teeth, 3-rd ed., Ed Munksgaard International Publishers, Copenhagen, 1994
13. Andreasen J.O: Etiology and pathogenesis of traumatic dental injuries. A clinical study of 1298 cases. *Scand. J. Dent. Res.*, 1970, vol 78.
14. Bakland L.K., Milledge T., Nation W.: Treatment of crown fractures. *J. of Calif. Dent. Assoc.* vol 21/2, 1996.
15. Bello, R. Jarvis, A review of esthetic alternatives for the restoration of anterior teeth. *The Journal of Prosthetic Dentistry*, vol.78, nr. 5, november, 1997.
16. Boboc, Anomaliile dento-maxilare, Bucuresti, 1999.

Acknowledgements. *This paper was written as part of ours doctorates, referents: prof. dr. Vasile Burlui, Prof. Dr. Mircea Rusu*

17. Boboc, Aparatul dento-maxilar, Bucuresti, 1999.
18. Bratu E., Grivu O.,Voinea C., Eruptia dentara normala și patologica. Editura Helicon, Timișoara 1995
19. Burlui Vasile, Norina Forna, Gabriela Ifteni: Clinica și Terapia Edentației Parțiale Intercalate Reduse. Editura Apollonia, Iași-2001
20. Caprioglio D., Falconi P., Vernole B.: Perte par traumatismes des incisives temporaires et permanents: Remplacement et resultants a distance; Les traumatismes des dents anterieures en pedodontie, Ed. Masson, Paris, 1990
21. Caprioglio D., Falconi P., Vernole B.: Traumatismes dentaire; Les traumatismes des dents anterieures en pedodontie, Ed. Masson, Paris, 1990
22. Cocârla E.: Traumatisme dento-parodontale în perioada copilariei; Pedodontie, Litografia UMF Cluj, 1992
23. Flores MT. Traumatic injuries in the primary dentition. *Dent Traumatol.* 2002; **18**: 287 - 298.
24. Flores Marie Therese, Traumatic injuries in the primary dentition, *Dental Traumatology*, Volume 18, Issue 6, Page 287-298, Dec 2002
25. Lechien P.; Traumatismes dentaire; *Act.od. Stom*, vol. 178, 1992.
26. Makie I.C.: Waren W.N.; Dental Trauma: 3. Splinting, displacement injuries and root fractures of immature permanent incisors teeth. *Dental Update*, vol. 15, 1988.
27. Matasaru Silvia: Pediatrie-ghid practic; Editura 'GH. Asachi' Iași 1994
28. Milot P., Stein Rs: Root fracture in endodontically treated teeth related to post selection and crown design. *Journal of Prosthetic Dentistry*, vol 62, 1992.
29. Meadov D., Lidner G., Needleman H.: Oral trauma in children. *Ped. Dent.*, 1984.
30. Medford HM, Curtis JW. Acute care of severe tooth fractures. *Ann Emerg Med* 1983; **12**: 364-366.
31. Mugnier A.: Traumatologie dentaire en stomatologie infantile, *Actualites odonto-stomat*, vol 77, 1989.
32. Rusu & colab., Ortodontie, Iasi, 1980.
33. Rusu & colab., Pedodontie, Iasi, 1981.
34. Timosca, Chirurgie buco-maxilo-faciala, Bucuresti, 1983.
35. Zarnea Livia, Ganescu V., Dragunea M.: Unele aspecte legate de frecvența fracturilor dentare la copii de vârsta școlara; *Rev. Stomatologie*, vol. 3, iul-sep., 1989
36. Balan, A, Maxim A., Pedodontie, Traumatismele dento-parodontale, Iasi, 2002

Correspondence to: Dr. Gheorghita Bogdan- specialist in dentistry, student PhD, Suceava, str. Tipografiei nr.4, bl. A5, sc. A, ap2, , 0744/382364