

Cardinal Ligament and Transverse Cervical Ligament are not Synonymous

Yoshihiko Yabuki* and Hiroaki Takagi

Department of Obstetrics and Gynecology, Kanazawa Medical University, Japan

*Corresponding author: Yoshihiko Yabuki, Department of Obstetrics and Gynecology, Kanazawa Medical University, Japan, Tel: 81-76-286-2211; E-mail: yabuk@nifty.com

Received date: February 27, 2018; Accepted date: March 22, 2018; Published date: March 27, 2018

Copyright: © 2018 Yabuki Y, et al. This is an open-access article distributed under the terms of the Creative Commons Attribution License, which permits unrestricted use, distribution, and reproduction in any medium, provided the original author and source are credited.

Abstract

The cardinal ligament and transverse cervical ligament are not distinguished as separate entities in Terminologia Anatomica. This interpretation of the cardinal ligament as being synonymous with the transverse cervical ligament has had a profound influence on clinical anatomy and, consequently, on the operative procedures for cervical cancer. This prompted the author to investigate and analyze the differences between the two lateral parametria. This was carried out through research on the history of clinical anatomy and surgery for cervical cancer, together with data from the author's surgical procedures for radical hysterectomy and cadaver dissections. An analysis by the author of Savage's theory (1875), Clark's surgery and Wertheim's surgery yielded evidence of the cardinal ligament being referred to as the medial parametrium of the ureter. Moreover, from analysis of Mackenrodt's theory, Latzko's surgery and Okabayashi's surgery, the transverse cervical ligament was found to be the lateral parametrium extending the cardinal ligament to the pelvic sidewall. However, in actual clinical practice the transverse cervical ligament is an artifact that can be excavated perpendicularly toward the sacral aspect and isolated between the paravesical and pararectal spaces. Therefore, a large discrepancy became apparent between theory and clinical anatomical evidence. Because of these contradictions, no consistency could be found for gross and clinical anatomical terms to coexist in one anatomical glossary. However, from morphological findings on the retroperitoneal space it allowed the author to find a common ground between the two anatomies. From a number of findings on the subserous layer, the author came to the following conclusion that the cardinal ligament was a bundle parallel to the uterus on the medial aspect of the ureter, and the transverse cervical ligament a bundle perpendicular to the uterus and connected to the pelvic sidewall.

Keywords: Cardinal ligament; Clinical anatomists; Genital organs; Connective tissue; Cervical cancer

Introduction

The cardinal ligament and transverse cervical ligament are regarded as synonymous in Terminologia Anatomica [1]. From the author's point of view, this is a concept derived from the aspect of gross anatomy alone in which the history of clinical anatomy of the lateral parametrium is disregarded. The derivation for this concept may have been strongly influenced by "the cardinal ligament of Mackenrodt" advocated by Uhlenhuth and Reiffenstahl [2,3].

Inclusion of clinical terms into gross anatomical text is an expectation long awaited from clinical anatomists and surgeons. Clinical anatomy provides a context in which to describe artifacts created clinically. This, especially, is true for the intrapelvic ligaments that can be compared to a sculpture engraved on the subserous layer. As a consequence, the clinical surgical approach appears to differ from time to time, from country to country or from school to school. If clinical anatomical terms are to be truly accepted into a gross anatomical glossary, it is necessary to acquire a precise definition and description of them. If these requirements are not met, any attempt to democratize the terminology by the Federative Committee on Anatomical Terminology (FCAT) will be in vain [4].

Literature Review

The author initially attempted a precise definition for the lateral parametrium based on a study of its historical development in pelvic clinical anatomy and through investigation into surgical procedures for radical hysterectomy. This was accompanied with an analysis of the data obtained from the author's own surgical procedures and cadaveric dissections, in addition to a morphological comparison between the two ligaments. The results presented the author with a theory that would enable the amalgamation of the terms for both anatomies.

Study Design

The material for this study consisted of the clinical anatomy presented by Savage [5,6] and Mackenrodt et al. [7,8] as well as an extensive literature review of articles published in the late 19th century through to the 20th century on surgery for uterine cervical cancer by Clark [9] Wertheim, [10] Latzko [11,12] Okabayashi [13,14] and Meigs et al. [15]. In addition, a review was carried out by the author of his published works on surgery from seven articles and one textbook. The data collected from this latter source was from 209 Japanese women who underwent surgery for uterine cancer and also on 26 dissections of female cadavers [16-22].

The cardinal ligament

The initial concept for the lateral parametrium was believed to be the condensation in the base of the broad ligament advocated by Savage [5].

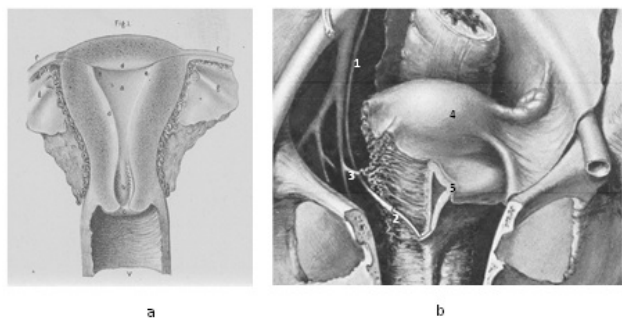


Figure 1: 1a is frontal view of a median section of the uterus taken from the textbook written by Savage (Savage H. *The Surgery, Surgical Pathology, and Surgical Anatomy of the Female Pelvic Organ, Commentaries, Notes, and Cases. Plate XVII, Figure 1*, New York: William Wood & Company, 1880.). Figure 1b demonstrates a section of a figure from an article by Clark. The peritoneum is dissected off one side of the pelvis and a bougie can be seen inserted into the ureter [9] (Clark, JG. A more radical method of performing hysterectomy for cancer of the uterus. *Figure 1, Johns Hopkins Hosp. Bull.* 1895; 6 :120-124.). 1. ureter, 2. bougie (ureteral catheter), 3. uterine artery, 4. uterus, 5. bladder.

As shown in Figure 1a the lateral parametrium of Savage was connective tissue mainly consisting of the broad ligament [6]. It was Kocks who named the above-mentioned condensation the cardinal ligament [23]. Based on the author's knowledge, it was Clark [9] who initially applied the Savage' theory to surgery for cervical cancer, and Wertheim was one of the surgeons who successfully carried out the operative procedure [9]. Figure 1b is taken from an article by Clark [9]. The author believes that Clark carried out separation of the cardinal ligament as follows: first, the vesicouterine and rectouterine septa were dissected, followed by the excavation of the vesicouterine and rectouterine spaces. This was followed by the vesicouterine and sacrouterine ligaments being individually separated, and the vesicouterine space extended to the medial aspect of the ureter together with the space created between the stumps of the severed vesicouterine ligament. Similar procedures were carried out for the rectouterine space and the stump of the sacrouterine ligament.

A number of procedures were carried out for the unroofing and rolling out of the ureter. Consequently, it became apparent that the exposed cardinal ligament was found to be a bundle that connected the medial aspect of ureter and uterus.

The transverse cervical ligament

In 1895 Mackenrodt named this lateral bundle the transverse cervical ligament, in which the embryonic parietal endopelvic fascia extended to the uterine cervix (Figure 2) [7].

The cavity, which future generations of surgeons named the pararectal space, can already be seen depicted in the figure drawn by Mackenrodt (Figure 2a). The operative procedure based on

Mackenrodt's clinical anatomy were the radical hysterectomy of Latzko-Schiffmann [11,12] and Okabayashi [13,14].

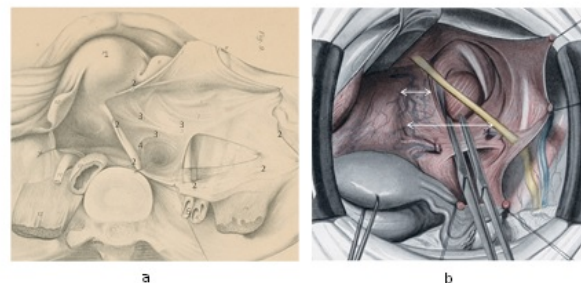


Figure 2: 2a) is a section taken from a figure in an article by Mackenrodt, showing the right operative field (Mackenrodt A. Ueber die Ursachen der normalen und pathologischen Lagen des Uterus. *Arch F Gynäk* 1895; 48: Taf. XIII. 1; uterus, 2; developed posterior leaf of the broad ligament, 3; transverse cervical ligament, 4; sacrouterine ligament, 5; ureter. Figure 2b is a figure taken from *Operative Gynecology* written by Peham-Amreich (Peham HV, Amreich J. *Operative Gynecology* translated by Ferguson LK. P348, Fig. 208, Philadelphia: JB Lippincott, 1934). The Mackenrodt ligament is drawn parallel to the lateral border of uterus and can be seen isolated and doubly clamped. The short double-headed arrow indicates the cardinal ligament and the long double-headed arrow the transverse cervical ligament (Mackenrodt ligament).

The characteristic of their operative procedure was that, after the transverse cervical ligament was separated from the paravesical and pararectal spaces on the lateral aspect of the ureter, it was severed at the pelvic sidewall (Figure 2b). Although Meigs called his operative procedure "the so-called Wertheim operation", it was, in fact, not, because he also intentionally excavated the paravesical and pararectal spaces [15].

Furthermore, Mackenrodt described the presence of an inferior continuum of the transverse cervical ligament, which he named as the short fibrous bundle [7,8]. Peham-Amreich further named this short fibrous bundle the horizontal connective tissue ground bundle, which, the author believes, is the precursor to the current paracolpium. Mackenrodt's concept perceivably led to interpretation by future generations of surgeons that the lateral parametrium was a bundle connecting the genital organs to the pelvic sidewall. Evidence for this interpretation can be seen in Peham-Amreich's pelvic connective tissue ground bundle [12] and Uhlenhuth's fascia endopelvina [2]. Moreover, the lateral parametrium defined in 21st century clinical anatomy is also interpreted as a bundle and as a continuum of the transverse cervical ligament and short fibrous bundle connecting the uterus to the pelvic side wall with this continuum extending to the pelvic floor along the lateral aspect of the genital organs [24-26].

The cardinal ligament and transverse cervical ligament

In Figure 2b drawn by Peham-Amreich the cardinal ligament and transverse cervical ligament can be seen separately depicted, probably unintentionally [12]. Furthermore, this illustration shows the transverse cervical ligament and the horizontal connective tissue ground bundle [12] or horizontal groundplate [2] connected in an L-shape on the posterior aspect of the paravesical space. This space was

created by resecting the areolar connective tissue in the retroperitoneal space expressing the potential space of the subserous layer or subperitoneal fascia.

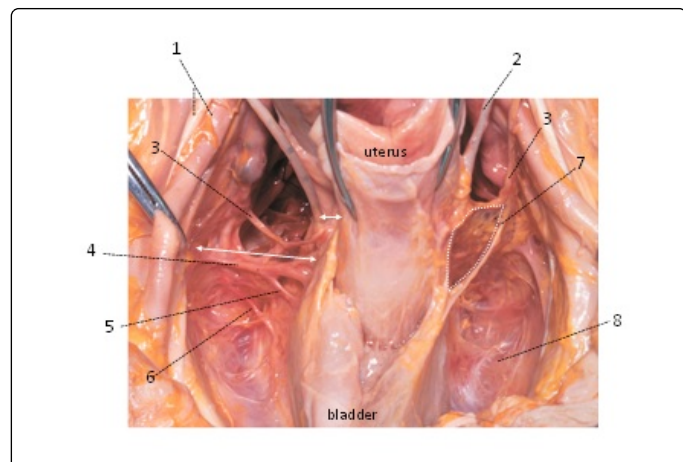


Figure 3: A photograph of a frontal view of a fresh cadaver following the dissection of the areolar connective tissue that filled the retroperitoneal space. The area surrounded by a dotted line indicates from where the vesicohypogastric fascia was denuded. The short double-headed arrow indicates the cardinal ligament and the long double-headed arrow the transverse cervical ligament.

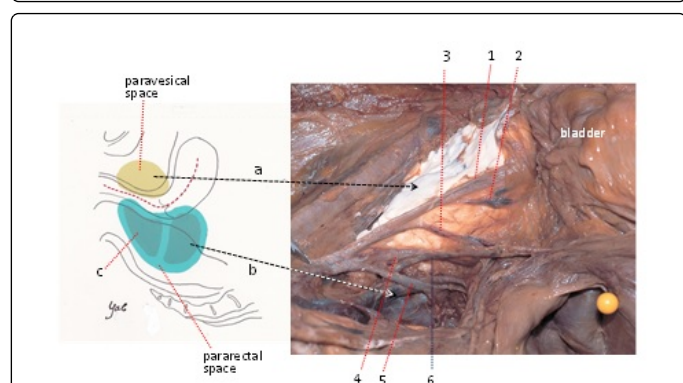


Figure 4: The visceral branches of the internal iliac vessels observed from the excavated left pararectal space. The posterior fascia of the lateral pelvic ligament has been dissected. The paravesical space is filled with paper clay. Arrow a indicates the paravesical space and Arrow b the pararectal space. 1; lateral umbilical ligament, 2; superior vesical ligament, 3; uterine artery, 4; middle rectal artery, 5; common trunk of the internal pudendal and inferior gluteal vessels, 6; deep uterine vein, c; lower chamber of the pararectal space. 1; internal iliac vessels, 2; ureter, 3; uterine artery, 4; deep uterine vein, 5; superior vesical vein, 6; middle rectal vessel, 7; lateral umbilical ligament, 8; paravesical space.

Figure 3 shows a frontal view of a mock dissection for radical hysterectomy using a fresh cadaver, followed by resection of the areolar connective tissue that filled the retroperitoneal space after the separation of the bladder, transection of the round ligaments, and removal of the anterior leaf of the broad ligament. On the right side of

the figure can be seen the visceral endopelvic fascia (transverse cervical ligament complex) and superior fascia of the levator ani and, on the left, a view of the resected fascia. The description expressed in topographical anatomy corresponds to that of the cadaver's subserous layer seen in this figure from which the areolar connective tissue is partially removed.

In comparison, Figure 4 shows the pararectal space was an artificial fascial cleft created in contrast to the paravesical space behind the transverse cervical ligament and horizontal groundplate. Figure 4 also shows Latzko's creation of an upper chamber in the pararectal space behind the transverse cervical ligament and a lower (horizontal) chamber in the pararectal space on the posterior aspect of the horizontal groundplate [11,12]. Okabayashi, conforming to the procedure by Wertheim, resected the rectouterine septum and sacrouterine ligament in sequence, consequently creating a cleft that was farther enlarged laterally, followed by the excavation of the pararectal space [13,14].

However, although the pararectal space is a true artifact, it is simply an identification point for the operative procedure, so that it cannot be categorized in gross anatomy. Moreover, illustrations of the transverse cervical ligament by Peham-Amreich [12] and Netter [27] show that it extends parallel to the pelvic floor between the two spaces and parallel to the lateral aspect of the genital organs, which can be applied to gross anatomy, but not to clinical anatomy [16-20].

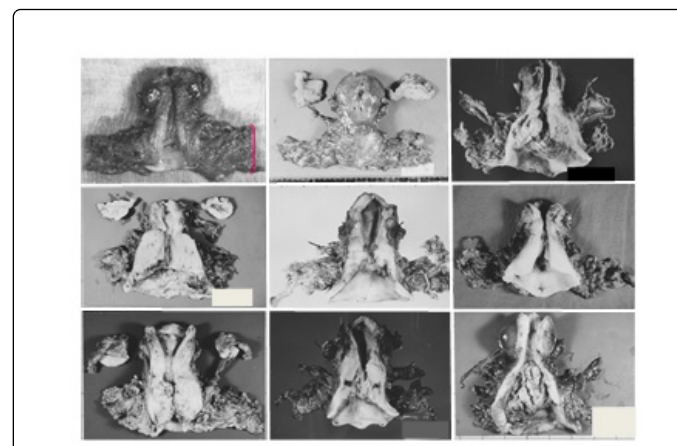


Figure 5: The tissue specimens obtained from the author's Okabayashi's radical hysterectomies from 1981 to 1982. The transverse cervical ligament can be seen extirpated as close to the pelvic floor as possible.

Figure 5 shows tissue specimens excised during radical hysterectomy carried out by the author during the early 1980s in which the Okabayashi's surgical procedure was employed. The more precisely the author followed Okabayashi's surgical procedure, the more perfuse the hemorrhaging became due to injury to the internal iliac vessels on the pelvic side wall and the venous plexus on the sacral aspect, together with resultant bladder dysfunction [16].

During these earlier surgical procedures the author discovered the following: a) the pararectal space (more precisely Latzko's upper chamber of the pararectal space [12] described in Peham-Amreich's Operative Gynecology as being excavated to the sacral aspect; and b) as a result, the lateral rectal ligament was found to be unintentionally

resected to reach the lower chamber of the pararectal space [16]. In this procedure, the pararectal space was excavated along the sagittal rectal septum of Peham-Amreich [12] (Figure 6).

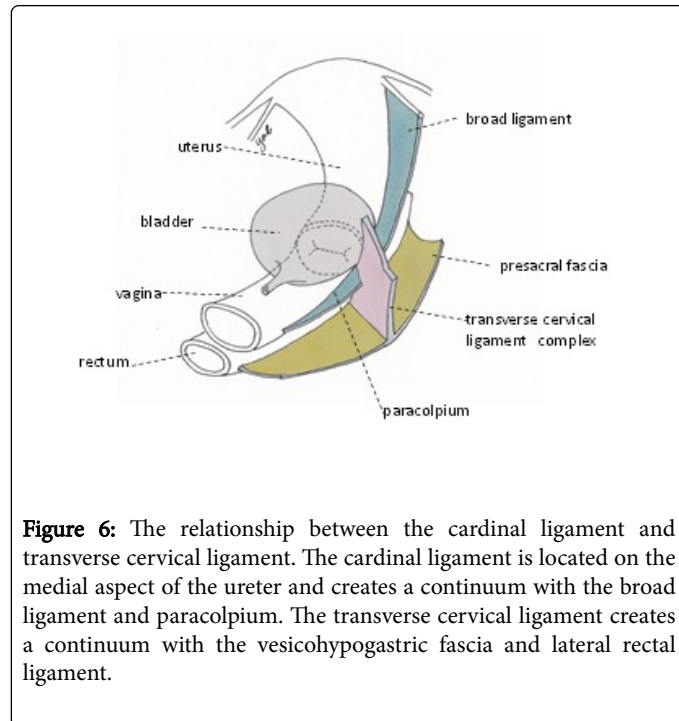


Figure 6: The relationship between the cardinal ligament and transverse cervical ligament. The cardinal ligament is located on the medial aspect of the ureter and creates a continuum with the broad ligament and paracolpium. The transverse cervical ligament creates a continuum with the vesicohypogastric fascia and lateral rectal ligament.

These facts necessitate the need for gross anatomists to distinguish between the truths and falsehoods of artifacts that vary according to the surgical times.

Since the superior vesical artery lies on the same plane with the uterine artery, the author believes that, during radical hysterectomy, the vesicohypogastric fascia (the connective tissue leaf of the lateral umbilical ligament [12], transverse cervical ligament and lateral rectal ligament are a continuum that forms one part of a plate [16].

Figure 6 shows the lateral parametrium as the author currently sees it. It is created by the broad ligament, cardinal ligament and paracolpium, all of which are parallel to the genital organs, and the transverse cervical ligament that is perpendicular to the uterus.

The author believes that the cardinal ligament should be regarded as "a condensation in the base of the broad ligament" and considered as a region lying on the medial aspect of the ureter and overlapping with the transverse cervical ligament.

Clinical anatomical morphology of ligaments

The dissection of cadavers in gross anatomy, in which the living body is clearly seen as it is depicted, is, in principle, performed sequentially tracing along the surfaces of the human body [12,27] while dissection in clinical anatomy is carried out along the shape of tissues or organs that are to be manipulated [16-23]. The transverse cervical ligament that is parallel with the laterally extended Savage's "condensation" could, therefore, be clinically recognized morphologically and, consequently, conform to gross anatomy. As a result, the transverse cervical ligament can be seen as having a parallel relationship with the genital organs [12,27]. This is, in fact, the currently recognized cardinal ligament [24-26] On the contrary, the

surgically created ligament between the two spaces, i.e. the transverse cervical ligament, has already been categorized in clinical anatomy. This ligament showed a continuum with the vesicohypogastric fascia and lateral rectal ligament and has a perpendicular relationship with the uterus [16-23].

For acceptance by Nomina Anatomica, a clinically unconflicting anatomical definition of the transverse cervical ligament is required. The terms transverse cervical ligament and lateral rectal ligament were hardly mentioned in clinical practice until the author presented them in his article published in 1991 [16]. Therefore, the use of the term transverse cervical ligament instead of cardinal ligament may, at times, cause confusion. However, the concept for the author's less radical hysterectomy [15] and nerve-sparing radical hysterectomy [17-19] was derived from the transverse cervical ligament being perpendicular to the uterus and became a basis for anatomy. Judging from viewing Figure 3, no contradiction is evident between the author's clinical 'perpendicular' theory and gross anatomy. In conclusion, the author believes that the cardinal ligament should be referred to as a bundle parallel to the uterus on the medial aspect of ureter, and the transverse cervical ligament as a perpendicular bundle to the lateral border of uterus connecting it to the pelvic sidewall (Figure 6).

Discussion

As the number of radical hysterectomy for cervical cancer has decreased due to bladder and rectal dysfunction and difficulty in technical surgical acquisition, adoption of the term the transverse cervical ligament in Gray's Anatomy seems to be a mere formality [28]. However, in the 30th American edition of Anatomy of the Human Body by Henry Gray, the term transverse cervical ligament, in view of its importance, was described in detail [29]. This is the edition the author chose to read while studying this ligament. The textbook contents opened with a description of the cardinal ligament (of Mackenrodt), which, from a clinicians' perspective, was rather difficult to comprehend and seemed only for the gross anatomists' benefit [29].

Advances in anatomy and progress in surgical procedures require an academic and cooperative relationship between the two disciplines. In 1991, the author discovered the lateral rectal ligament was a part of the transverse cervical ligament that, in traditional radical hysterectomy, was resected. Consequently, in response to this new finding, a new clinical anatomy was proposed for this ligament [16]. Then, in 1996, the author discovered a vesical branch of the inferior hypogastric plexus that ran parallel with the vein linking the deep uterine vein to the bladder within the Okabayashi's posterior layer of the vesicouterine ligament and proposed the possibility of a nerve-sparing procedure [17,18] Further, in 2000, the author perfected a surgical procedure for preservation of the vesical autonomic innervation in radical hysterectomy (the current nerve-sparing radical hysterectomy) [19]. Since then, many gynecologists including Possover [29,30], Raspagliesi [31] and Cibula [32] in the West and Sakuragi [33] and Fujii [34] in Japan have carried out this nerve-sparing surgery. It was a well-timed surgical procedure, for, at that time, new descriptive terms of the transverse cervical ligament and lateral rectal ligament were being introduced into the revised edition of Terminologia Anatomica in 1998 [1].

One of the objectives of the Federative Committee on Anatomical Terminology must be for an amalgamation of the gross anatomical and clinical anatomical terms. However, it is very difficult to find a common ground between gross anatomy in which the living body is

clearly seen as it is depicted and clinical anatomy that has a means of describing such artifacts created clinically.

Shown in Gray's Anatomy for Students for the first time in 2005 are schematic illustrations of ligaments such as the transverse cervical ligament, pubocervical ligament and uterosacral ligament [35-37] However, it is impossible for surgeons from a clinical aspect to visualize through the peritoneum what the illustration; i.e., "the condensation in the base of the broad ligament" of Savage, is trying to express.

We can find a common denominator for an intraoperative view and topographical anatomical morphology in the parametrium on the left side of Figure 3 with the pelvic visceral peritoneum denuded and excavated areolar connective tissue of the retroperitoneal space. Only because of extensive experience in surgery for radical hysterectomy and pelvic dissection, was the author able to comprehend the description for the term the cardinal ligament (of Mackenrodt) in the 30th American edition of Gray's Anatomy [29], which must have been based on observation from the retroperitoneal aspect of gross anatomists.

Conclusion

In this article the author has indicated that gross anatomists and clinical anatomists could come to a common understanding of the pelvic visceral fascia or ligaments if viewed by both disciplines from the retroperitoneum. These tissues, if observed from the retroperitoneal space, would enable an amalgamation of the two anatomies and a fresh anatomical view of the pelvic connective tissue. New precise anatomy for structures within the pelvis would enhance further advancement in surgical procedures for gynecological conditions.

Acknowledgment

Sincere thanks go to Dr. Shimpachiro Ogiwara, former Professor of Physical Therapy, University of Kanazawa, and Mrs. Sandra M. Ogiwara for editorial assistance.

References

1. Terminologia Anatomica (1998) International Anatomical Terminology/ Federative Committee on Anatomical Terminology. Stuttgart/New York: Thieme, USA.
2. Uhlenhuth E, Day DE, Smith RD, Middleton EB (1948) The visceral endopelvic fascia and the hypogastric sheath. Surg Gynecol Obstet 86: 09-28.
3. Reiffenstuhel G (1982) The clinical significance of the connective tissue planes and spaces. Clin Obstet Gynecol 25: 812-820.
4. Whitmore I (1999) Terminologia Anatomica: new terminology for the new anatomist. Anat Rec (New Anat) 257: 50-53.
5. Savage H (1876) The surgery, surgical pathology, and surgical anatomy of the female pelvic organ. (3rd edn) London: J & A Churchill.
6. Savage H (1880) The Surgery, surgical pathology, and surgical anatomy of the female pelvic organ, commentaries, Note, and Cases. New York: William Wood & Company, USA.
7. Mackenrodt A (1895) Ueber die ursachen der normalen und pathologischen lagen des uterus. Arch F Gynäk 48: 393-421.
8. Speert H (1996) Obstetrics and Gynecologic Milestones Illustrated, Parthenon, New York, USA. pp. 138-141.
9. Clark JG (1895) A more radical method of performing hysterectomy for cancer of the uterus. Johns Hopkins Hosp Bull 6: 120-124.
10. Wertheim E (1912) The extended abdominal operation for carcinoma uteri (Based on 500 operative cases). Am J Obstet Dis Women Child 66:169-232.
11. Latzko W, Schiffmann J (1919) Klinisches und anatomisches des zur radikaloperation des gebarmutterkrebses (nach einem am 24. Juni 1919 gehaltenen Vortrag). Diskussionsbemerkungen, Weibel W. und Wertheim E. Zbl Gynäk 43: 715-719.
12. Peham HV, Amreich J (1934) Operative gynecology (translated by Ferguson LK). Philadelphia: JB Lippincott pp: 333-366.
13. Okabayashi H (1921) Radical abdominal hysterectomy for cancer of the cervix uteri. Surg Gynecol Obstet 33: 335-341.
14. Okabayashi H (1952) Radical operation for cancer of uterine cervix. Tokyo: Kanehara (in Japanese).
15. Meigs JV (1950) Radical hysterectomy for cancer of the cervix with bilateral pelvic lymphadenectomy (the so-called Wertheim operation). In: Progress in Gynecology, New York: Grune Stratton pp: 540-560.
16. Yabuki Y, Asamoto A, Hoshiba T, Nishimoto H, Kitamura S (1991) Dissection of the cardinal ligament in radical hysterectomy for cervical cancer with emphasis on the lateral ligament. Am J Obstet Gynecol 164: 07-14.
17. Yabuki Y, Asamoto A, Hoshiba T, Nishimoto H, Satou N (1996) A new proposal for radical hysterectomy. Gynecol Oncol 62: 370-378.
18. Yabuki Y (1997) Cardinal ligament dissection based on a new theory. CEM J Gynecol Oncol 2: 278-287.
19. Yabuki Y, Asamoto A, Hoshiba T, Nishimoto H, Nishikawa YM, et al. (2000) Radical hysterectomy: an anatomic evaluation of parametrial dissection. Gynecol Oncol 77: 155-163.
20. Yabuki Y, Sasaki H, Hatakeyama N, Murakami G (2005) Discrepancies between classic anatomy and modern gynecologic surgery on pelvic connective tissue structure: harmonization of those concepts by collaborative cadaver dissection. Am J Obstet Gynecol 193: 07-15.
21. Yabuki Y, Murakami G, Hoshiba T, Sasaki H, Hatakeyama N, et al. (2011) Redefinition of the pelvic connective tissue: *in-situ* histologic examination. Female Pelvic Med Reconstr Surg 17: 60-66.
22. Yabuki Y (2009) New Radical Hysterectomy for Uterine Cancer, (2nd edn). Theory and Technique for Nerve-Sparing Operation. Tokyo: Medical View (in Japanese).
23. Kocks J (1880) Die Normale und pathologische lage und gestalt des uterus sowie deren mechanik. Bonn: Max Cohen & Sohn.
24. Höckel M, Kondering MA, Heuel CP (1998) Liposuction-assisted nerve-sparing extended radical hysterectomy: oncologic rationale, surgical anatomy, and feasibility study. Am J Obstet Gynecol 178: 971-976.
25. Höckel M, Horn LC, Hentschel B, Höckel S, Naumanns G (2003) Total mesorectal resection: high resolution nerve-sparing radical hysterectomy based on developmentally defined surgical anatomy. Int J Gynecol Cancer 13: 791-803.
26. Magrina JF, Pawlina W, Kho RM, Magtiby PM (2011) Robotic nerve-sparing radical hysterectomy: feasibility and technique. Gynecol Oncol 121: 605-609.
27. Netter FH (2006) Atlas of human anatomy (4th edn) 364; Saunders, an imprint of Elsevier Inc.
28. Standring S (2005) Gray's anatomy; the anatomical basis of clinical practice, (39th edn). Philadelphia, Elsevier Churchill Livingstone, USA.
29. Clemente CD (1985) Anatomy of the human body by Henry Gray, 30th American ed. Philadelphia, Lea & Febiger, USA. pp. 1574-1577.
30. Possover M, Stöber S, Plaul k, Shneider A (2000) Identification and preservation of the motoric innervation of the bladder in radical hysterectomy type. Gynecol Oncol 79: 154-157.
31. Raspagliesi F, Ditto A, Fontanelli R, Solima E, Hanozet F, et al. (2004) Nerve-sparing radical hysterectomy: a surgical technique for preserving the autonomic hypogastric nerve. Gynecol Onco 193:307-314.
32. Cibula D, Abu-Rustum NR, Benedetti PP, Köhler C, Raspagliesi F, et al. (2011) New classification system of radical hysterectomy: emphasis on a three-dimensional anatomic template for parametrial resection. Gynecol Oncol 122: 264-268.

-
33. Sakuragi N, Todo Y, Yamamoto R, Sato T (2005) A systematic nerve-sparing radical hysterectomy technique in invasive cervical cancer for preserving postsurgical bladder function. *Int Gynecol Cancer* 15: 01-09.
 34. Fujii S, Takakura K, Higuchi T, Yura S, Mandai M, et al. (2007) Anatomic identification and functional outcomes of the nerve spring Okabayashi radical hysterectomy. *Gynecol* 107: 04-13.
 35. Drake RL, Vogl W, Mitchell AWM (2005) *Gray's Anatomy for Students*. Philadelphia: Elsevier Churchill Livingstone pp. 417.
 36. Kato T, Murakami G, Yabuki Y (2002) Dose the cardinal ligament of the uterus contain a nerve that should be preserved in radical hysterectomy? *Anat Sci Int* 77: 161-168.
 37. Kato T, Murakami G, Yabuki Y (2003) A new perspective on nerve-sparing radical hysterectomy of the cardinal ligament. *Jap J Clin Oncol* 33: 589-591.