

Candida Albicans Involvement in Denture-Related Stomatitis: A Serious and Real Clinical Concern

André LS Santos^{1,2*}, Isadora S Carvalho³, Juliano M Prata³, Matheus B Martins³, Lucieri OP Souza¹, Anna Clara M Galdino^{1,2}, Lys A Braga-Silva¹, Marta H Branquinha¹, Suely Maria Rodrigues⁴ and Lourimar VNF Sousa³

¹Laboratório de Investigação de Peptidases (LIP), Departamento de Microbiologia Geral, Instituto de Microbiologia Paulo de Góes (IMPG), Universidade Federal do Rio de Janeiro (UFRJ), Rio de Janeiro, Brazil

²Programa de Pós-Graduação em Bioquímica (PPGBq), Instituto de Química (IQ), Universidade Federal do Rio de Janeiro (UFRJ), Brazil

³Laboratório de Microbiologia, Universidade Vale do Rio Doce (UNIVALE), Governador Valadares, Minas Gerais, Brazil

⁴Núcleo de Pesquisa Saúde, Individuo e Sociedade (SAIS), Universidade Vale do Rio Doce (UNIVALE), Governador Valadares, Minas Gerais, Brazil

*Corresponding author: André L.S. Santos, Laboratório de Investigação de Peptidases (LIP), Departamento de Microbiologia Geral, Instituto de Microbiologia Paulo de Góes (IMPG), Bloco E - subsolo, sala 05, Centro de Ciências da Saúde (CCS), Universidade Federal do Rio de Janeiro (UFRJ), Rio de Janeiro, RJ 21941-902, Brazil, Tel: +55 21 3938 6740; E-mail: andre@micro.ufrj.br

Received date: January 25, 2016; Accepted date: February 12, 2016; Published date: February 18, 2016

Copyright: © 2016 André LS Santos, et al. This is an open-access article distributed under the terms of the Creative Commons Attribution License, which permits unrestricted use, distribution, and reproduction in any medium, provided the original author and source are credited.

Abstract

Denture stomatitis, also known as atrophic candidiasis, remains the most frequent form of oral candidiasis, being detected in approximately 25%-65% of denture-wearing patients. Denture stomatitis is characterized by an erythematous inflammation of mucosal areas covered by prosthesis with preferential localization in the palatal mucosa. Although the clinical entity of this infectious disease is multifactorial, *Candida albicans* is the major etiological agent. The treatment of this oral infection is difficult because failures and recurrences are extremely common. In the present opinion article, we have presented a brief review on this oral pathology, summarizing the main predisposing factors, clinical diagnosis and current effective options to prevent and treat the affected population.

Keywords: Oral candidiasis; Denture stomatitis; Atrophic candidiasis; Predisposing factors; Diagnosis; Prevention; Treatment

Opinion

In the last decades, the prevalence of *Candida spp.* infections has been rising in direct proportion to the increasingly aging population and the larger population of immunocompromised and critically ill

patients, being the commonest human fungal infection reported in clinical settings around the globe [1-9]. Yeast-like microorganisms belonging to the *Candida* genus are the etiological agents of candidiasis, which are common dwellers of the oral cavity, gastrointestinal tract and vagina of normal people. However, when the conditions become appropriate, the nonpathogenic yeast forms are transformed into pathogenic invasive forms [1-9] (Figure 1).

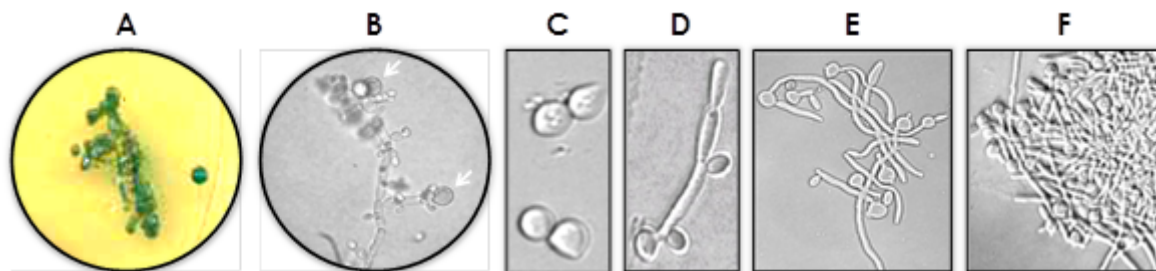

Figure 1: *Candida albicans* cells visualized under distinct methods. (A) Colonial morphology of *C. albicans* grown in CHROM Agar Candida medium, showing the typical green color that corresponds to the presumptive identification of this fungal species. (B) Spherical chlamydospores (arrows), mostly terminal, often on a slightly swollen subtending cell are formed near the edge of the cover slip. (C-F) Different morphological growth forms of *C. albicans*. (C) yeasts, (D) pseudohyphae, (E) germ-tube and (F) hyphae.

Colonization of oral surfaces by *Candida spp.* is considered a risk factor for invasive fungal infections. Oropharyngeal candidiasis manifests clinically as acute pseudomembranous, acute atrophic, chronic atrophic, chronic hypertrophic/hyperplastic and angular cheilitis [5-9]. Denture-related stomatitis (or chronic atrophic

candidiasis) is characterized by an inflammation of the mucous membrane located beneath the prosthesis, particularly under the upper denture, sometimes accompanied by hemorrhagic petechiae [10-13] (Figure 2). Denture stomatitis is the commonest form of oral candidiasis and its reported prevalence varies widely reaching up to

65% of denture wearers. Patients may complain of a burning sensation, irritation, discomfort, bad taste and disturbance of salivation, but in the majority of cases they are unaware of the problem [10-13]. *Candida albicans* (Figure 1) is the most relevant and frequent species of *Candida* recovered from lesion areas and/or prosthesis [10-13]. These virulent *C. albicans* isolates are capable of epithelial binding, disruption of epithelial integrity and invasion due to its ability to produce an arsenal of virulence factors such as adhesins, hydrolytic enzymes (e.g., proteases and phospholipases) and the ability to form filamentous forms (e.g., pseudohyphae and hyphae) [14-20] (Figure 1). Diagnosis of oral candidiasis includes characteristic clinical appearance, exfoliative cytology, imprint culture, swab culture, salivary assays and mucosal biopsy [13,21,22] (Figures 1 and 2).

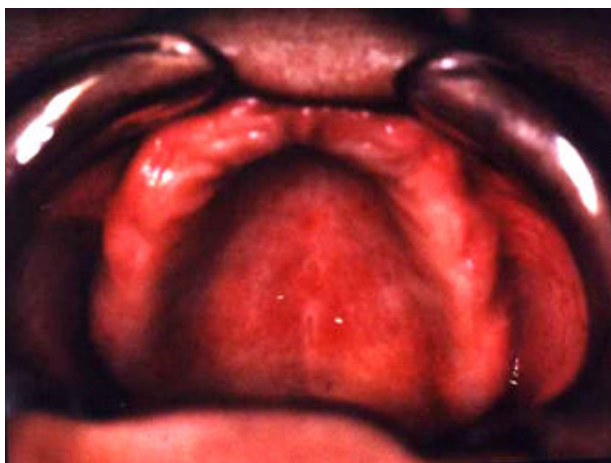


Figure 2: Denture stomatitis, an erythematous and edematous tissue on the hard palate below the dentures that is associated with candidiasis.

Many predisposing factors have been implicated in the development and severity of denture stomatitis, including: patient age and gender, trauma caused by the denture itself, poor oral and denture hygiene, continuous denture wear, age of denture, availability of sugar in the oral environment through dietary intake, malnourishment, smoking, alcohol consumption, impaired salivary flow and salivary gland function, diabetes mellitus, antibacterial drug therapy, corticosteroids, radiotherapy, malignancy and other immunocompromised conditions, especially acquired immunodeficiency syndrome [8-13]. Furthermore, the ability of *Candida* cells to adhere, colonize and, subsequently, form a mature biofilm over the surface of denture materials is an important etiologic factor for this disease as well as for the development of caries and periodontitis adjacent to the denture [13,17-20]. The fungal colonization depends on numerous factors related to the prosthesis substrate characteristics. In this way, leaching, brushing and efficient mechanical cleaning processes, along the time, may deteriorate the soft lines due to the loss of plasticizers, causing irreversible damage to the prosthesis surface that culminates in difficulty to its cleaning and, as a consequence, facilitates the colonization of microorganisms [23-25].

Denture stomatitis is often treated with antifungal suspensions based on nystatin, amphotericin B, miconazole and fluconazole, which generally produce a complete remission of symptoms within 12-14 days. However, recurrence or new episodes are common, and certain episodes can be due to the presence of resistant fungal strains [26-29].

When treating patients who have candidiasis, removable dental appliances in active use might be also effectively cleaned, since they provide a reservoir for fungal biofilm development [30], or even the replacement by a new denture should be considered [31,32]. Several protocols have been described for cleaning, treating, preventing infection or disinfecting dentures, including (i) immersion in a solution containing sodium hypochlorite, chlorhexidine, chlorine dioxide, effervescent cleansing tablets and antifungal agents (e.g., benzalkonium chloride) and (ii) irradiation with microwave, whose denture should be immersed in water, which is a quick, effective and cheap method [31-35]. All these methodologies are able to decrease the number of colony-forming units; however, complete fungal elimination is not always achieved.

For all these reasons, the correct patient orientation by the dental health professional is fundamental to the successful elimination of the pathogen from the prosthesis and, of course, to cure the infectious process. So, in order to obtain a correct prevention of this oral condition it becomes necessary to incorporate some simple educational practices that should be adopted daily by the patient. In this context, the transmission of information, the orientation and the skills development in a simple way is mandatory. Therefore, the oral health education becomes a essential mean to acquire knowledge, skills, attitudes and building values, enabling the patient to act daily for the benefit of own oral health and quality of life.

References

1. Köhler JR, Casadevall A, Perfect J (2014) The spectrum of fungi that infects humans. *Cold Spring Harb Perspect Med* 5: a019273.
2. Badiie P, Hashemizadeh Z (2014) Opportunistic invasive fungal infections: diagnosis and clinical management. *Indian J Med Res* 139: 195-204.
3. Armstrong-James D, Meintjes G, Brown GD (2014) A neglected epidemic: fungal infections in HIV/AIDS. *Trends Microbiol* 22: 120-127.
4. Andes DR, Safdar N, Baddley JW, Playford G, Reboli AC, et al. (2012) Impact of treatment strategy on outcomes in patients with candidemia and other forms of invasive candidiasis: a patient-level quantitative review of randomized trials. *Clin Infect Dis* 54: 1110-1122.
5. Garcia-Cuesta C, Sarrion-Pérez MG, Bagán JV (2014) Current treatment of oral candidiasis: a literature review. *J Clin Exp Dent* 6: 576-582.
6. Singh A, Verma R, Murari A, Agrawal A (2014) Oral candidiasis: an overview. *J Oral Maxillofac Pathol* 18: 81-85.
7. Coronado-Castellote L, Jiménez-Soriano Y (2013) Clinical and microbiological diagnosis of oral candidiasis. *J Clin Exp Dent* 5: 279-286.
8. Lalla RV, Patton LL, Dongari-Bagtzoglou A (2013) Oral candidiasis: pathogenesis, clinical presentation, diagnosis and treatment strategies. *J Calif Dent Assoc* 41: 263-268.
9. Chi AC, Neville BW, Krayner JW, Gonsalves WC (2010) Oral manifestations of systemic disease. *Am Fam Physician* 82: 1381-1388.
10. Wilson J (1998) The aetiology, diagnosis and management of denture stomatitis. *Br Dent J* 185: 380-384
11. Pereira-Cenci T, Del Bel Cury AA, Crielaard W, Ten Cate JM (2008) Development of Candida-associated denture stomatitis: new insights. *J Appl Oral Sci* 16: 86-94.
12. Salerno C, Pascale M, Contaldo M, Esposito V, Busciolano M, et al. (2011) Candida-associated denture stomatitis. *Med Oral Patol Oral Cir Bucal* 16: 139-143.
13. Gendreau L, Loewy ZG (2011) Epidemiology and etiology of denture stomatitis. *J Prosthodont* 20: 251-260.
14. Santos ALS (2011) Protease expression by microorganisms and its relevance to crucial physiological/pathological events. *World J Biol Chem* 2: 48-58.

15. Ene IV, Brunke S, Brown AJ, Hube B (2014) Metabolism in fungal pathogenesis. *Cold Spring Harb Perspect Med* 4: a019695.
16. Sheppard DC, Filler SG (2014) Host cell invasion by medically important fungi. *Cold Spring Harb Perspect Med* 5: a019687.
17. Polke M, Hube B, Jacobsen ID (2015) Candida survival strategies. *Adv Appl Microbiol* 91: 139-235.
18. Nobile CJ, Johnson AD (2015) Candida albicans biofilms and human disease. *Annu Rev Microbiol* 69: 71-92.
19. Kojic EM, Darouiche RO (2004) Candida infections of medical devices. *Clin Microbiol Rev* 17: 255-267.
20. Coulthwaite L, Verran J (2007) Potential pathogenic aspects of denture plaque. *Br J Biomed Sci* 64: 180-189.
21. Lund RG, da Silva Nascente P, Etges A, Ribeiro GA, Rosalen PL, et al. (2010) Occurrence, isolation and differentiation of Candida spp. and prevalence of variables associated to chronic atrophic candidiasis. *Mycoses* 53: 232-238.
22. Terai H, Shimahara M (2009) Usefulness of culture test and direct examination for the diagnosis of oral atrophic candidiasis. *Int J Dermatol* 48: 371-373.
23. Skupien JA, Valentini F, Boscato N, Pereira-Cenci T (2013) Prevention and treatment of Candida colonization on denture liners: a systematic review. *J Prosthet Dent* 110: 356-362.
24. Radford DR, Challacombe SJ, Walter JD (1999) Denture plaque and adherence of Candida albicans to denture-base materials in vivo and in vitro. *Crit Rev Oral Biol Med* 10: 99-116.
25. Von Fraunhofer JA, Loewy ZG (2009) Factors involved in microbial colonization of oral prostheses. *Gen Dent* 57: 136-143.
26. Milton Rocha Gusmão J, Pereira RP (2013) Treatment protocol for denture stomatitis, prior to anatomical molding. *Gerodontology* 30: 232-235.
27. Chow CK, Matear DW, Lawrence HP (1999) Efficacy of antifungal agents in tissue conditioners in treating candidiasis. *Gerodontology* 16: 110-118.
28. Anibal PC, de Cássia Orlandi Sardi J, Peixoto IT, de Carvalho Moraes JJ, Höfling JF (2010) Conventional and alternative antifungal therapies to oral candidiasis. *Braz J Microbiol* 41: 824-831.
29. Budtz-Jørgensen E, Lombardi T (1996) Antifungal therapy in the oral cavity. *Periodontol* 2000 10: 89-106.
30. Santos ALS, Mello TP, Ramos LS, Branquinha MH (2015) Biofilm: a robust and efficient barrier to antifungal chemotherapy. *J Antimicrob Agents* 1: e101.
31. Emami E, Taraf H, de Grandmont P, Gauthier G, de Koninck L, et al. (2012) The association of denture stomatitis and partial removable dental prostheses: a systematic review. *Int J Prosthodont* 25: 113-119.
32. Preshaw PM, Walls AW, Jakubovics NS, Moynihan PJ, Jepson NJ, et al. (2011) Association of removable partial denture use with oral and systemic health. *J Dent* 39: 711-719.
33. Lalla RV, Dongari-Bagtzoglou A (2014) Antifungal medications or disinfectants for denture stomatitis. *Evid Based Dent* 15: 61-62.
34. Mohammad AR, Giannini PJ, Preshaw PM, Alliger H (2004) Clinical and microbiological efficacy of chlorine dioxide in the management of chronic atrophic candidiasis: an open study. *Int Dent J* 54: 154-158.
35. Brondani MA, Samim F, Feng H (2012) A conventional microwave oven for denture cleaning: a critical review. *Gerodontology* 29: 6-15.