

Brain Abscess Caused by *Capnocytophaga* Species Associated with Anti-Tumor Necrosis Factor- α Therapy

Hou-Wen Chen^{1*}, Cheng-Siu Chang² and Shih-Ming Tsao²

¹Department of Emergency Medicine, Tao Yuan General Hospital, Ministry of Health and Welfare, Tao Yuan, Taiwan, Republic of China

²Chung Shan Medical University Hospital, Chung Shan Medical University Taiwan, Republic of China

Abstract

Capnocytophaga is a genus of Gram-negative bacteria as oral saprophytes in humans, dogs and cats. The incidence rate of *Capnocytophaga* was 0.67 infections per million population. Classical risk factor including liver disease, liver cirrhosis, asplenic, alcoholics or postsplenectomy. Most of the patients are bitten or scratched by a dog. Brain abscess due to *Capnocytophaga* only have few reports. With the advent of biological agent in recent two decades, increased infection secondary to anti-tumor necrosis factor- α was established. Herein, we reported a case of *Capnocytophaga* Species brain abscess after anti-tumor necrosis factor- α . Patient developed *Capnocytophaga* Species brain abscess after treatment course of adalimumab 40 mg twice monthly for more than one year. To the best of our knowledge, this is the first case of *Capnocytophaga* infection following adalimumab treatment.

Keywords: Anti-tumor necrosis factor-A; Brain abscess; *Capnocytophaga* species

Introduction

Capnocytophaga spp. are a rare cause of fulminant sepsis in individuals who have been bitten or scratched by a dog. Immunocompromised individuals are at high risk of *Capnocytophaga* spp. infections [1]. Anti-tumor necrosis factor- α (anti-TNF- α) drugs are a class of drugs that are used worldwide to treat patients with rheumatoid arthritis (RA) and selected other autoimmune inflammatory diseases. Over the past 15 years, an increased rate of serious infections has been reported in patients treated with anti-TNF- α drugs [2]. Herein, we report a case of a brain abscess caused *Capnocytophaga* spp. following anti-TNF- α therapy. To the best of our knowledge, this is the first such case reported in the literature.

Case Report

A 71-year-old woman reported that she had vertigo for 10 days. She lived in a suburban district of southern Taiwan with a guard dog outside the house. In the past year, she had taken subcutaneous adalimumab 40 mg twice monthly with oral celecoxib and methotrexate to control her RA. On examination, she had a temperature of 36.7°C, elevated blood pressure of 186/116 mm Hg, heart rate of 93/min, and respiratory rate of 18/min. A physical examination was unremarkable except for an unsteady gait. The peripheral leukocyte count was 16390 cells/ μ L, and the C-reactive protein level was 0.347 mg/dl. Brain computed tomography scan revealed a hypodense lesion with rim enhancement over the superior vermis and right cerebellum (Figure 1). Pre-operative brain Magnetic Resonance Imaging (MRI) Diffusion weighted imaging (DWI) showed contrast enhanced lesion over the superior vermis and right cerebellum (Figure 2). Stereotaxic aspiration of the right cerebellum area was performed with external ventricular drainage. By hospital day 7, *Capnocytophaga* spp. had been isolated from the brain abscess, and the external ventricular drainage was removed. Thereafter, patient received antibiotic treatment with intravenous amoxicillin-clavulanic acid 1.2 gm/day per 12 hours and oral form amoxicillin-clavulanic acid 1 gm twice daily sequentially for more than 4 weeks. Two months after her pre-operative brain MRI DWI showed resolution of prior enhanced lesion (Figure 3). She has uneventful course after 6 months follow up.

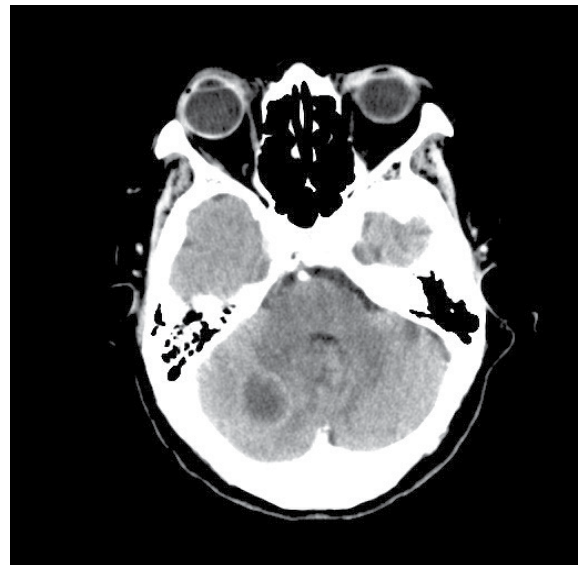


Figure 1: Contrast enhanced brain computed tomography showed a hypodense lesion with rim enhancement over the superior vermis and right cerebellum.

Discussion

Capnocytophaga spp. is anaerobic gram-negative bacilli commonly identified as oral saprophytes in humans, dogs and cats. *Capnocytophaga*

*Corresponding author: Hou-Wen Chen, Department of Emergency Medicine, Tao Yuan General Hospital, Ministry of Health and Welfare, Tao Yuan, Taiwan, Republic of China, Tel: 886-9-28058232; E-mail: tsmhw@ms24.hinet.net

Received January 04, 2016; Accepted January 29, 2016; Published February 05, 2016

Citation: Chen HW, Chang CS, Tsao SM (2016) Brain Abscess Caused by *Capnocytophaga* Species Associated with Anti-Tumor Necrosis Factor- α Therapy. J Microb Biochem Technol 8: 042-044. doi:10.4172/1948-5948.1000260

Copyright: © 2016 Chen HW, et al. This is an open-access article distributed under the terms of the Creative Commons Attribution License, which permits unrestricted use, distribution, and reproduction in any medium, provided the original author and source are credited.

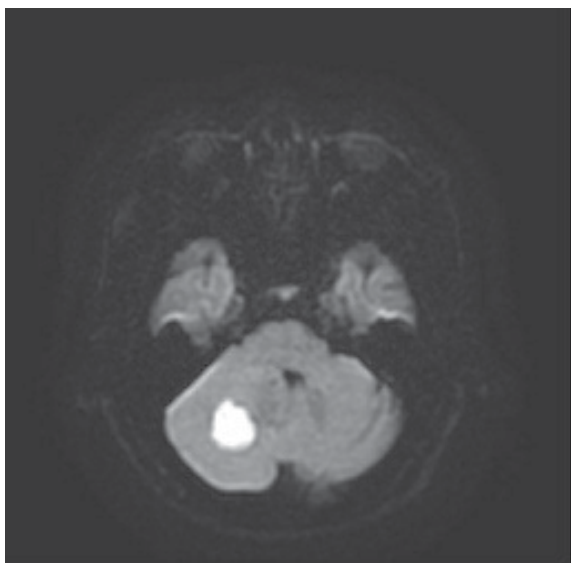


Figure 2: Pre-operative brain MRI DWI showed contrast enhanced lesion over the superior vermis and right cerebellum.

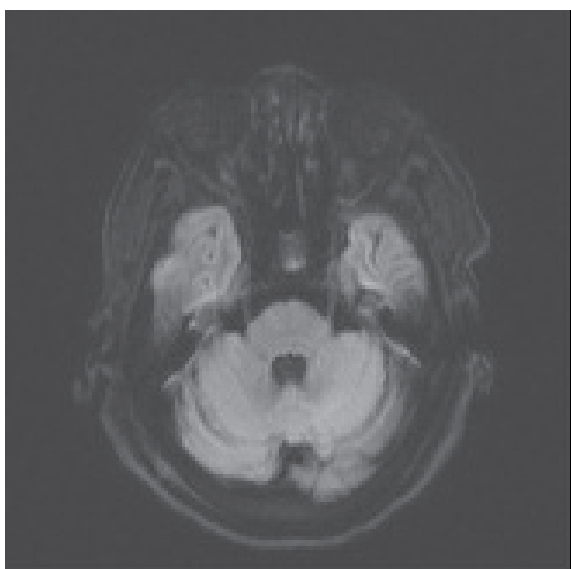


Figure 3: Post-operative brain MRI DWI showed resolution of prior enhanced lesion.

spp. infections were first described presenting as meningitis and sepsis in 1976. The genus *Capnocytophaga* consists of a variety of commensal species in the oral flora of humans, including *Capnocytophaga gingivalis*, *Capnocytophaga granulosa*, *Capnocytophaga haemolytica*, *Capnocytophaga leadbetteri*, *Capnocytophaga ochracea*, *Capnocytophaga sputigena* and *Capnocytophaga genospecies* AHN8471. *Capnocytophaga canimorsus* and *Capnocytophaga cynodegmi* are part of the oral microbiota of canines and more rarely of cats [1]. A 3-year nationwide survey in the Netherlands reported that the only proven species in *Capnocytophaga* spp. infections was *C. canimorsus* [3]. However, identification at the species level remains difficult, and molecular techniques (16S rDNA PCR and sequencing) and mass

spectrometry appear to be the most reliable methods to identify the genus [4].

The pathogenesis of *Capnocytophaga* spp. is not well understood. Most previous studies on *Capnocytophaga* spp. have focused on *C. canimorsus*, which exhibits robust growth in mammalian cells, including phagocytes. Surface-localized sialidases can initiate an extensive deglycosylation process of host cell glycoproteins. This mechanism serves as a basis for the growth and persistence of *C. canimorsus* *in vivo* [5]. In addition, *C. canimorsus* has the capacity to deglycosylate human IgGs [6]. However, further studies are needed to elucidate the pathogenesis with regards to anti-TNF- α therapy.

Capnocytophaga spp. can cause infections ranging from self-limited symptoms to fatal sepsis. Classical risk factors include asplenia, immunocompromised status, liver cirrhosis, and heavy alcohol use. A history of a dog bite, contact with dog saliva, cat scratch or contact with cat saliva is found in approximately half of cases. A fulminant course may occur in immunocompromised patients, characterized by sepsis, meningitis, endocarditis, osteomyelitis, purulent arthritis, pneumonia, peritonitis, disseminated intravascular coagulation and fulminant purpura [7]. A brain abscess caused by *Capnocytophaga* spp. has only been reported in a few studies [8]. Furthermore, only two cases of *Capnocytophaga* spp. infections following treatment with biological drugs have been reported, however neither of these cases involved a brain abscess, and no cases of a brain abscess caused by *Capnocytophaga* spp. following anti-TNF- α therapy have been reported. The first of these two cases was a 63-year-old patient with RA who had cellulitis after treatment with etanercept 25 mg twice weekly, and the other was a 20 year-old female with juvenile chronic arthritis who suffered from *Capnocytophaga* bacteremia after receiving the last course of rituximab 9 months previously [9,10]. Our patient had a history of imitate contact with a dog; however she could not recall any bites or scratches. Although steroids and methotrexate were used in this patient, anti-TNF- α therapy with adalimumab twice monthly was responsible for this opportunistic brain infection. This case should serve to remind physicians of the possibility of central nervous system infections such as *Capnocytophaga* spp. in pet owners who have been undergoing anti-TNF- α therapy.

References

1. Popiel KY, Vinh DC (2013) 'Bobo-Newton syndrome': An unwanted gift from man's best friend. *Can J Infect Dis Med Microbiol* 24: 209-214.
2. Lahiri M, Dixon WG (2015) Risk of infection with biologic antirheumatic therapies in patients with rheumatoid arthritis. *Best Pract Res Clin Rheumatol* 29: 290-305.
3. Dam AP, Jansz A (2011) *Capnocytophaga canimorsus* infections in The Netherlands: a nationwide survey. *Clin Microbiol Infect* 17: 312-315.
4. Janda JM, Graves MH, Lindquist D, Probert WS (2006) Diagnosing *Capnocytophaga canimorsus* infections. *Emerg Infect Dis* 12: 340-342.
5. Mally M, Shin H, Paroz C, Landmann R, Cornelis GR (2008) *Capnocytophaga canimorsus*: a human pathogen feeding at the surface of epithelial cells and phagocytes. *PLoS Pathog* 4:e1000164.
6. Renzi F, Manfredi P, Mally M, Moes S, Jenö P, et al. (2011) The N-glycan glycoprotein deglycosylation complex (Gpd) from *Capnocytophaga canimorsus* deglycosylates human IgG. *PLoS Pathog* 7: e1002118.
7. Gaastra W, Lipman LJ (2010) *Capnocytophaga canimorsus*. *Vet Microbiol* 140: 339-346.
8. Wang HK, Chen YC, Teng LJ, Hung CC, Chen ML, et al. (2007) Brain abscess associated with multidrug-resistant *Capnocytophaga ochracea* infection. *J Clin Microbiol* 45: 645-647.
9. Gerster JC, Dudler J (2004) Cellulitis caused by *Capnocytophaga cynodegmi*

associated with etanercept treatment in a patient with rheumatoid arthritis. *Clin Rheumatol* 23: 570-571.

10. Pokroy-Shapira E, Shiber S, Molad Y (2012) Capnocytophaga bacteraemia following rituximab treatment. *BMJ Case Reports*.