

Bilateral Sinus Lift Augmentation in Elderly Patients with Severely Atrophic Maxilla

Leiser Y^{1,2}, Rachmiel A^{1,2}

¹Departments of Oral and Maxillofacial Surgery, Rambam Health Care Campus. ²Faculty of Medicine, Technion-Israel Institute of Technology, Haifa, Israel.

Abstract

Objective: Severe atrophy (Class V, VI, according to the classification of Cawood and Howell), is a major challenge for oral rehabilitation, especially since most of the patients are edentulous and as they become older they may suffer several comorbidities that could hamper the success of the final rehabilitation, our aim in the presented study was to summarize our experience in the challenging rehabilitation of bilaterally severe atrophic maxilla's in elderly patients using simply sinus lift augmentation and dental implants.

Method and Materials: Inclusion criteria were elderly patients that presented with a fully edentulous maxilla with severe atrophy of the maxillary alveolus and severe pneumatization of the maxillary sinuses. A total of 30 sinus elevation procedures were performed, using a mixture of approximately 90% bovine bone and 10% autogenous bone. A total of 90 implants were placed in 30 sinuses of 15 patients (10 women, 5 men).

Results: In 9 cases (9/30, 30%), the maxillary sinus membrane perforated during manual elevation. Three patients suffered from a transient hypoesthesia in the area of the infra orbital nerve. There were no signs or symptoms of maxillary sinus infection. Two implants out of 90 implants (2.2%) that were placed failed to integrate.

Conclusion: implementation of a two stage bilateral sinus lift augmentation in elderly patients can be a simple and, as shown by us, reproducible method with 97.8% survival of dental implants with relatively low patients' morbidity.

Key Words: Sinus augmentation, Atrophic maxilla, Dental implants, Sinus lift, Bone graft

Introduction

Severe atrophy (Class V and VI, according to the classification of Cawood and Howell) of a totally or partially edentulous maxilla can pose a major challenge for implant-supported fixed oral rehabilitation [1,2]. Despite the overall progress in dental implantology, the placement of implants in the posterior atrophic maxilla is already considered to be a challenging procedure due to great levels of reduced bone volumes in many cases [3]. Most patients suffer from a sagittal maxillary deficiency, a wide inter-arch distance and a reversed intermaxillary relationship giving patients an older appearance [4]. The maxillary bone resorption is centripetal, combined this phenomena with the centrifugal resorption of the mandible, this can create a relatively unfavorable vertical, transverse, and sagittal intermaxillary relationship, which can further hinder maxillary implants and make implant functional rehabilitation difficult [2,5]. The Cawood and Hawell's classification [5] for edentulous jaws was developed based on a randomized cross-sectional study from a sample of 300 dried skulls. They were able to show that the changes in the shapes of the alveolar process follow a predictable pattern. The well-established classification serves to simplify description of the residual ridge and is important in implant supported reconstruction. Regarding the maxillary residual ridge, class 1 refers to a dentate ridge, class 2 is a post extraction site, class 3 is a convex ridge form with adequate height and width for implant placement, class IV refers to a knife edge ridge form with inadequate width but adequate height for implant placement, class V is a flat ridge with loss of the alveolar process and class VI is the loss of basal bone which in its turn

very hard to predict its pattern of resorption.

As maxillary bone resorption with alveolar atrophy deteriorates, it is needed to resort to advanced bone graft surgery, such as the bloc iliac crest Le Fort I osteotomy, on lay-type bone grafting techniques, or maxillary sinus lift procedures in the posterior sectors of the maxilla [6-11]. The Le Fort 1 osteotomy with autogenous interpositional bone grafting, typically using iliac bone, allows forward and/or downward repositioning of the maxilla, Various modifications of the technique include horseshoe sandwich osteotomy, or uni or bi-lateral segmental osteotomy with interpositional bone grafting [9,12,13]. Recently, the alveolar distraction has gained acceptance as a predictable pre-implant augmentation method for simultaneously regenerating bone and surrounding soft tissue [14,15]. In extremely atrophic posterior maxillary region, sinus lifting with simultaneous alveolar distraction was also suggested [16]. The disadvantages in all the different methods mentioned above is the additional procedural requirements and attendant patient morbidity; such procedures are longer, the bone graft is eventually limited, the procedure often require the use of general anesthesia, increase the likelihood of intra- and postoperative complications, and can result in considerable postoperative pain. To overcome some of the disadvantages of autogenous bone grafting, Brånemark in 1988 [17] introduced the zygomatic implants. They were designed to rehabilitate atrophic upper maxilla, or upper jaws subjected to resection for oncological reasons, or with bone loss secondary to trauma. Yet they do require general anesthesia and possible post-operative morbidity. Another major disadvantage of the zygomatic implants is the fact that

sufficient bone volume in the anterior zone of the upper jaw - with a minimum height of 10 mm and a width of 4 mm is required - to allow the placement of 2-4 conventional implants. If the bone volume in the anterior upper maxillary zone is insufficient, there must be ideal conditions for onlay-type bone grafting and Guided Bone Regeneration (GBR) techniques. Because of the disadvantages of bone grafting such as limited availability and donor site morbidity, various allografts, xenografts and alloplastic materials are being used to substitute autogenous bone [18,19]. Though bone substitutes show only few osteoinductive potential they may act as a scaffold for bone growth [20,21]. In a recent review [22], the overall implant survival rate using 100% autogenous bone grafts for sinus augmentations was lower (88.9%) compared to combined grafts (94.7%) and 100% bone substitutes (96.1%). Grafts using bone substitutes alone or in combination with autogenous bone were found as effective as those using exclusively particulate autogenous bone for supporting dental implants [22]. The aim of the present study was to summarize and characterize the severely atrophic (type VI) maxilla in elderly, otherwise healthy, patients and present an alternative method to rehabilitate those patients by using a mixture of xenograft and autograft for a two stage bilateral sinus lift augmentation.

Methods and Materials

The present study is a clinical and radiographic retrospective study. All of our patients presented with bilateral tooth loss in the entire maxilla with severe atrophy of the maxillary alveolus and severe pneumatization of the maxillary sinuses bilaterally. All the patients were edentulous for more than 5 years at the initial clinical examination. All surgical procedures were performed by Oral and Maxillofacial surgery specialists which are the authors of this article. Patients were initially visited for evaluation and for collection of baseline data. The evaluations included the general health and the oral health status and inter maxillary relationships (*Figure 1*). Inclusion criteria were elderly patients, average age was 67 years old, with severe atrophy of the alveolar process in their maxillary sinus area bilaterally, Class IV, VI, according

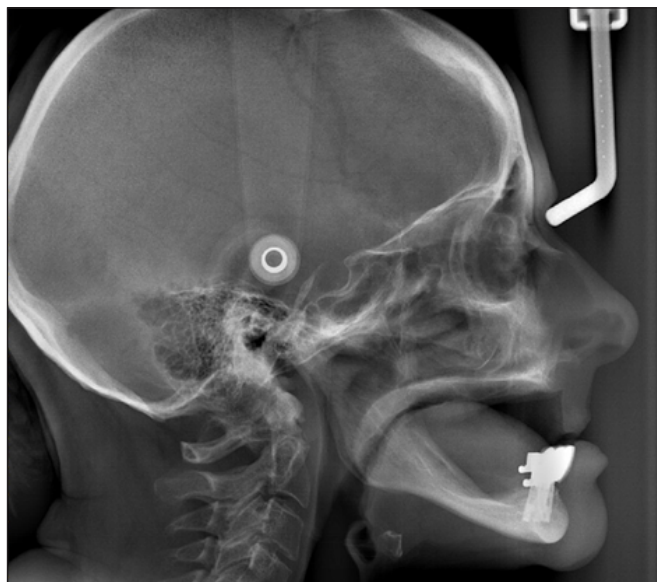

Figure 1. Cephalometric view. Radiographic view of the inter-maxillary relationships prior to the surgical procedure.

to the Cawood and Howell classification [1]. In most cases the subantral vertical bone was unusable for dental implants and practically nonexistent (*Figures 2,3*). The initial average alveolar bone height was 0-3 mm. All patients received oral hygiene instructions before the surgery. After information about the procedure they were required to sign a consent form. Furthermore, in addition to the baseline radiographs further radiographic follow-ups were available for all patients. Exclusion criteria were poor general health, e.g. severe renal/ or liver disease, history of a radiotherapy in the surgical area, active chemotherapy at the time of surgery, uncontrolled diabetes mellitus (Hemoglobin A1C>8%), symptoms of a maxillary sinus disease, untreated or not responding to treatment periodontal disease, IV bisphosphonate use, heavy smokers (>20 cigarettes a day) and poor oral hygiene. A total of 15 patients, comprising 30 maxillary sinus lift procedures, met the inclusion criteria, 10 females, 5 males; the average age was 67.6 years, range 58-83 years, (*Table 1*), average follow up was 35.3 months (*Table 1*).

The Surgical procedure

Briefly, Local anesthesia was achieved with a 2% lidocaine and epinephrine 1:100.000. Sinus augmentation was performed using the lateral lift technique according to Tatum [23]. The lateral wall was fenestrated using a scraper and a low speed diamond bur. The sinus membrane was exposed and elevated and a sub-sinus cavity created for placement of the graft

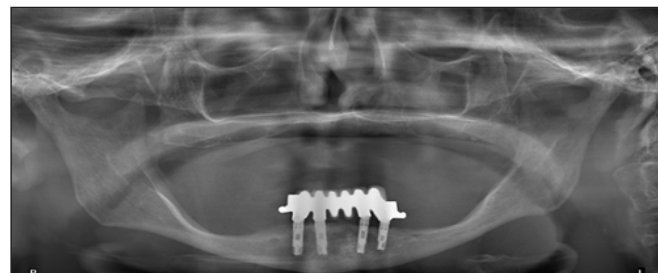


Figure 2. Panoramic radiograph. The panoramic view showing the severely atrophic (class VI) Maxilla, pre-surgical.

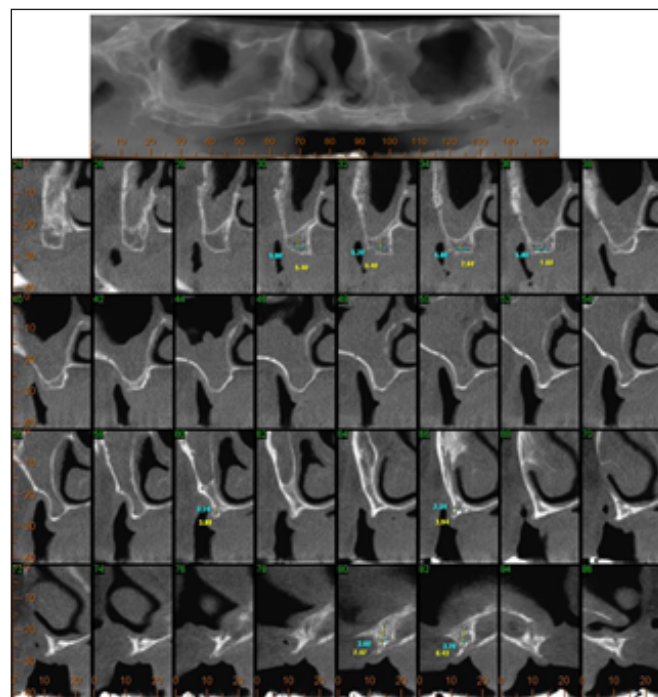


Figure 3. Cone beam computerized tomography (CBCT). The CBCT presented showing the pre surgical class VI atrophic maxilla.

Table 1. Demographic and clinical data of the patients.

Patients #	Demographics		Treatment	Failure			Follow-up (month)
	Age	Gender	# of Implants	Sinus Lift	membrane tear	Implants	
1	58	F	6	None	None	0	24
2	78	M	6	None	None	0	72
3	62	M	6	None	yes	0	24
4	63	M	6	None	yes	0	72
5	59	F	6	None	None	1	12
6	60	F	6	None	yes	0	24
7	68	F	6	None	None	0	24
8	74	M	6	None	yes	0	24
9	68	M	6	None	None	0	24
10	60	F	6	None	None	0	12
11	66	F	6	None	None	0	24
12	67	F	6	None	None	0	84
13	82	F	6	None	yes	1	72
14	67	F	6	None	yes	0	24
15	83	F	6	None	None	0	14

material. The lateral wall bone was harvested and was mixed with the bovine bone (Geistlich Bio-Oss®, Switzerland), in a ratio of approximately 1:9. Only large granules bovine bone was used (1-2mm, Geistlich Bio-Oss®, Switzerland) (*Figure 4*). Due to the severe atrophy the sinus lateral wall was an egg shell thin and friable. A resorbable collagenous membrane (BioGuide®, Geistlich Biomaterials and Switzerland) was inserted inside the sinus as well as to cover the lateral wall defect prior to suturing. Then about 1.5 to 2.5 gr of the material was gently inserted sub-membraneously with a spoon and spatula. Postoperatively, the patients received antibiotics coverage for 5 days with amoxicillin and clavulanate potassium (875 mg X 2/d) and 0.2% chlorhexidine for mouth rinsing 24hr following the surgery for 7 days. After a period of 4-6 month the patient received three screw type, tapered implants (3.7mm/13mm Screw-Vent®, Zimmer Dental, USA), that were placed in the desired positions bilaterally (*Figure 5*). Six month following the surgical procedure the implants were exposed and the final implant supported over denture was fabricated (*Figure 6*).

Results

A total of 30 sinus elevation procedures were performed, using a mixture of approximately 90% bovine bone and 10% autogenous bone. Following the sinus augmentation all patients received a minimum height (in most of the subantral areas) of 13mm. A total of 90 implants were placed in 30 sinuses of 15 patients (10 women, 5 men) (*Table 1*). Only elderly patients (>58 years) with severe atrophy (Class V, VI, according to the Cawood and Howell classification [1]) were included in this study. The patient's age at the time of surgery ranged between 58-83 years with an average of 67.6 years. All atrophic maxillary sinuses were 'egg shell' thin with extremely delicate schneiderian membrane. In 9 cases (9/30, 30%), the maxillary sinus membrane perforated during manual elevation.

Perforations were covered using resorbable membrane (BioGuide®, Geistlich Biomaterials, Switzerland). Three patients suffered from a transient hypoesthesia in the area of the infra orbital nerve, due to manual manipulation of the nerve during the augmentation procedure. There were no

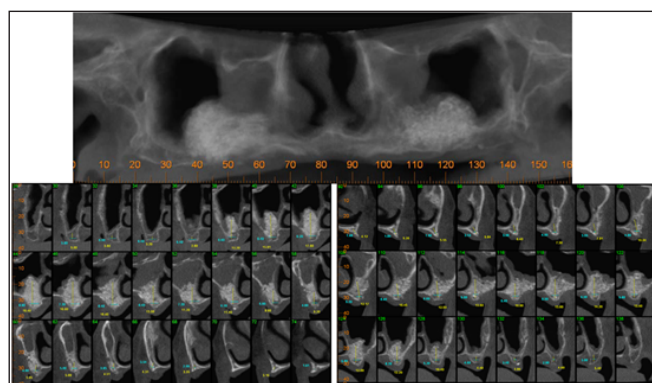


Figure 4. Cone beam computerized tomography. Following the bilateral sinus lift augmentation procedure.

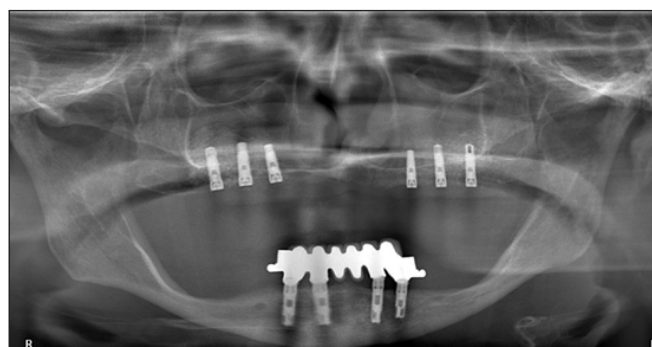


Figure 5. Panoramic view of the dental implants. This is the panoramic radiograph that was taken following the placement of 6 dental implants.

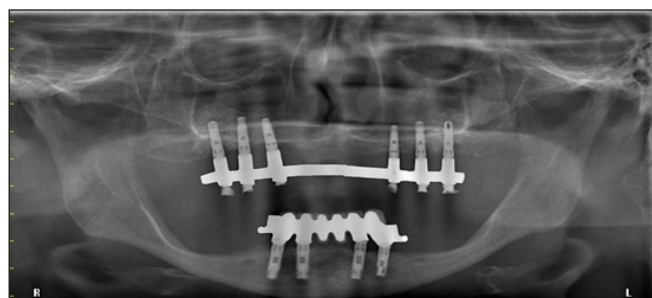


Figure 6. The final prosthetic reconstruction. Panoramic radiograph of the implant supported overdenture.

signs or symptoms of any maxillary sinus infection occurred immediately after surgical procedure or later. At the time of

implant exposure 2 implants out of 90 implants that were placed failed to integrate. The implants were removed and after 3 month of waiting new implants were placed at the same area without recurrence of failure. All implants were functionally stable. The follow-up period between baseline and final examination ranged from 12 to 84 months (mean 35.3 months) (*Table 1*). There were neither clinical signs of pain, infections, neuropathies, and paraesthesia nor radiographic signs of peri-implant radiolucency.

Discussion

There are several reconstructive options for the severely atrophic maxilla. the surgical procedures which include amongst others the bloc iliac crest Le Fort I osteotomy, onlay-type bone grafting techniques [6-11], alveolar distraction osteogenesis, which augments both bone and surrounding soft tissue [14,15], horseshoe sandwich osteotomy, segmental osteotomy with interpositional bone grafting [9,12,13], and also the zygomatic implants. All of the options mentioned above necessitate the use of general anesthesia with all of its disadvantages and post-operative morbidity, also the need for bone grafting usually necessitates a second surgical site with limited availability of bone graft and subsequent donor site morbidity, the need for hospital stay may also be harmful in older patients that could develop nosocomial opportunistic infections that can even be life threatening in some instances, such as Community-Acquired Pneumonia (CAP) [24]. Many of the older population suffer from several co-morbidities and surgical interventions are in some patients limited. The use of bilateral sinus lift augmentation can be a simple and, as shown by us, reproducible method with 97.8% survival of dental implants and relatively low patients morbidity. There is no second site morbidity, the bone graft is practically unlimited, the procedure can be done using local anesthesia alone and the cost to the patient is reduced. The procedure must be performed as a two stage procedure. To overcome the lack of cellularity a mixture of autogenous inductive bone from the sinus wall should be mixed with bovine conductive mineral. The use of bone mineral is most important in this procedure since it provides stability to the relocation of the sinus membrane and cellular and protein induction by certain inductive proteins such as BMP (Bone Morphogenic Protein - BMP) which acts at an early stage of bone induction and can promote and maintain bone formation. BMPs have a role in enhanced recruitment, proliferation, and differentiation of pluripotent mesenchymal cells at the osteotomy site and become progenitor cells with the potential to form new bone. As shown recently by de Oliveira et al. in edentulous patients the use of other techniques such as blood clot alone will lead to complete failure of the sinus lift procedure in edentulous patients [25]. BMP is located in the bone matrix and since the mass of bone matrix is greater in cortical than cancellous bone [3], an increased amount of BMP is present in cortical bone. The mineral of the cortical bone is dissolved by the host osteoclasts and the BMP proteins serve as the osteoinductive material. Special care should be given to the schneiderian membrane. The majority of our patients suffered

membrane thickening as shown in the CBCT of *Figure 3*. It was found that a negative relationship exist between residual bone height and membrane thickness, the thinner the residual bone the thicker the membrane would be and as a result of that a higher perforation rate would be found [26], in the present study as expected a high perforation rate was seen (9/30, 30%). Three patients suffered from a transient hypoesthesia in the area of the infra orbital nerve, we did not exposure the infra orbital nerve during the sinus lift procedure, yet since the alveolar process was virtually nonexistent in the majority of our patients the nerve is localized more caudally and pressure during the retraction of the flap could be the cause for the transient sensory changes, therefore, great care should be taken to avoid accidental injury of the nerve during the retraction. In the current literature most of sinus lift procedures present with minor complications. According to Moreno et al. 2014, [27] the most common intraoperative complication was damage to the Schneiderian membrane (25.7%), which was not correlated with postoperative complications. Other complications including wound infection, abscess, or dehiscence with drainage (9 cases), maxillary sinusitis of the operated area (6 cases), partial exposure of the simultaneous on lay graft (6 cases), and loss of the graft (2 cases) were evident in 14.9% of their patients (total of 202 sinus lift procedures) [27].

According to our surgical procedure we performed in all of our patients a 2 stage sinus lifting. No statistically significant differences have been found between implants placed according to 1- or 2-stage sinus lift procedures [28]. However, Felice et al. [28], in a recent article advocated that there might be a slightly higher risk for implant failures when performing a 1-stage lateral sinus lift procedure in patients having residual bone height between 1 to 3 mm below the maxillary sinus,

Conclusion

There are several surgical reconstructive options for severely atrophic maxilla, these options include amongst others the bloc iliac crest Le Fort I osteotomy, on lay-type bone grafting techniques, zygomatic implants, and many more, all of the procedures mentioned above require general anesthesia and pose a medical challenge in elderly patients. In the presented study the use of bilateral sinus lift augmentation was shown to be a simple and reproducible method with 97.8% survival of dental implants and relatively low patients' morbidity. All the pitfalls of sinus augmentation in severely atrophic maxillas should be taken into account, including thickened and friable schneiderian membrane that is prone to perforation, performing a 2-stage rather than 1-stage procedure, the need for osteoinductive material due to severe lack of cellularity and strict screening for medical comorbidities that could be the cause of failure. We, as Maxillofacial surgeons, perform all the alternative procedure that were presented in this article, yet we believe that the surgeon should implement judgment and treat each case individually, since several uncomplicated cases can stay uncomplicated and could be successful if treated simply and cautiously by sinus lifting alone.

References

1. Cawood JI, Howell RA. A classification of the edentulous jaws. *International Journal of Oral Maxillofacial Surgery*. 1988; **17**: 232-236.
2. Cawood JI, Stoelinga PJ, Blackburn TK. The evolution of preimplant surgery from preprosthetic surgery. *International Journal of Oral and Maxillofacial Surgery*. 2007; **36**: 377-385.
3. Mellonig JT. Decalcified freeze-dried bone allograft as an implant material in human periodontal defects. *The International Journal of Periodontics & Restorative Dentistry*. 1984; **4**: 40-55.
4. Yerit KC, Posch M, Guserl U, Turhani D, Schopper C, Wanschitz F, Wagner A, Watzinger F, Ewers R. Rehabilitation of the severely atrophied maxilla by Horseshoe Le Fort I Osteotomy (HLFO). *Oral Surgery, Oral Medicine, Oral Pathology, Oral Radiology and Endodontics*. 2004; **97**: 683-692.
5. Cawood JI, Howell RA. Reconstructive preprosthetic surgery. I. Anatomical considerations. *International Journal of Oral and Maxillofacial Surgery*. 1991; **20**: 75-82.
6. Astrand P, Nord PG, Branemark PI. Titanium implants and onlay bone graft to the atrophic edentulous maxilla: A 3-year longitudinal study. *International Journal of Oral and Maxillofacial Surgery*. 1996; **25**: 25-29.
7. Boyne PJ, James RA. Grafting of the maxillary sinus floor with autogenous marrow and bone. *Journal of Oral Surgery*, 1980. **38**: 613-616.
8. Sorni M, Guarinós J, García O, Peñarrocha M. Implant rehabilitation of the atrophic upper jaw: A review of the literature since 1999. *Medicina Oral, Patología Oral y Cirugía Bucal*. 2005; **10**: 45-56.
9. Van der Mark EL, Bierenbroodspot F, Baas EM, De Lange J. Reconstruction of an atrophic maxilla: Comparison of two methods. *The British Journal of Oral & Maxillofacial Surgery*. 2011; **49**: 198-202.
10. Wannfors K, Johansson B, Hallman M, Strandkvist T. A prospective randomized study of 1- and 2-stage sinus inlay bone grafts: 1-year follow-up. *The International Journal of Oral & Maxillofacial Implants*. 2000; **15**: 625-632.
11. Wiltfang J, Schultze-Mosgau S, Nkenke E, Thorwarth M, Neukam FW, Schlegel KA. Onlay augmentation versus sinuslift procedure in the treatment of the severely resorbed maxilla: A 5-year comparative longitudinal study. *International Journal of Oral and Maxillofacial Surgery*. 2005; **34**: 885-889.
12. Gossweiner S, Watzinger F, Ackerman KL, Ewers R. Horseshoe Le Fort I osteotomy: An augmentation technique for the severely atrophied maxilla--An eight-year follow-up. *Journal of long-term effects of medical implants*, 1999; **9**: 193-202.
13. Pelo S, Gasparini G, Moro A, Boniello R, Amoroso PF. Segmental Le Fort I osteotomy with bone grafting in unilateral severely atrophied maxilla. *International Journal of Oral and Maxillofacial Surgery*. 2009; **38**: 246-249.
14. Kanno T, Mitsugi M, Furuki Y, Hosoe M, Akamatsu H, Takenobu T. Overcorrection in vertical alveolar distraction osteogenesis for dental implants. *International Journal of Oral and Maxillofacial Surgery*. 2007; **36**: 398-402.
15. Kim SG, Mitsugi M, Kim BO. Simultaneous sinus lifting and alveolar distraction of the atrophic maxillary alveolus for implant placement: A preliminary report. *Implant Dentistry*. 2005; **14**: 344-346.
16. Kanno T, Masaharu M, Jun-Young P, Shintaro S, Yoshihiko F, Hiroyuki O, Yoshiki N, Hiroaki I, Hideaki Katsuyama, Joji S. Simultaneous sinus lifting and alveolar distraction of a severely atrophic posterior maxilla for oral rehabilitation with dental implants. *International Journal of Dentistry*. 2012; **2012**: 11.
17. Galan Gil S, Miguel Peñarrocha D, Jose Balaguer M, Eva Marti B. Rehabilitation of severely resorbed maxillae with zygomatic implants: An update. *Medicina Oral, Patología Oral y Cirugía Bucal*. 2007; **12**: 216-220.
18. Aghaloo TL, Moy PK. Which hard tissue augmentation techniques are the most successful in furnishing bony support for implant placement? *The International Journal of Oral & Maxillofacial Implants*. 2007; **22**: 49-70.
19. Moore WR, Graves SE, Bain GI. Synthetic bone graft substitutes. *ANZ Journal of Surgery*. 2001; **71**: 354-361.
20. Abukawa H, Papadaki M, Abulikemu M, Leaf J, Vacanti JP, Kaban LB, Troulis MJ. The engineering of craniofacial tissues in the laboratory: A review of biomaterials for scaffolds and implant coatings. *Dental Clinics of North America*. 2006; **50**: 205-216.
21. Vikram D, Nather A, Khalid KA (Editors). Role of ceramics on bone graft substitutes. In: Bone Grafts and Bone Substitutes. Basic Science and Clinical Applications. New Jersey: World Scientific. 2005: pp. 445-458.
22. Del Fabbro M, Rosano G, Taschieri S. Implant survival rates after maxillary sinus augmentation. *European Journal of Oral Sciences*. 2008; **116**: 497-506.
23. Tatum H. Maxillary and sinus implant reconstructions. *Dental Clinics of North America*. 1986; **30**: 207-229.
24. Xiao K, Su LX, Han BC, Yan P, Yuan N, Deng J, Li J, Xie LX. Analysis of the severity and prognosis assessment of aged patients with community-acquired pneumonia: A retrospective study. *Journal of Thoracic Disease*. 2013; **5**: 626-633.
25. De Oliveira GR, Olate S, Cavalieri-Pereira L, Pozzer L, Asprino L, de Moraes M, de Albergaria-Barbosa JR. Maxillary sinus floor augmentation using blood without graft material. Preliminary results in 10 patients. *Journal of Oral and Maxillofacial Surgery: Official Journal of the American Association of Oral and Maxillofacial Surgeons*. 2013; **71**: 1670-1675.
26. Wen SC, Lin YH, Yang YC, Wang HL. The influence of sinus membrane thickness upon membrane perforation during transcrestal sinus lift procedure. *Clinical Oral Implants Research*. 2014.
27. Moreno Vazquez JC, Gonzalez de Rivera AS, Gil HS, Mifsut RS. Complication rate in 200 consecutive sinus lift procedures: Guidelines for prevention and treatment. *Journal of Oral and Maxillofacial Surgery: Official Journal of the American Association of Oral and Maxillofacial Surgeons*. 2014; **72**: 892-901.
28. Felice P, Pistilli R, Piattelli M, Soardi E, Barausse C, Esposito M. 1-stage versus 2-stage lateral sinus lift procedures: 1-year post-loading results of a multicentre randomised controlled trial. *European Journal of Oral Implantology*. 2014; **7**: 65-75.