

An in vitro experiment in the early diagnosis of caries using four diagnostic methods

M. Peneva¹, Rashkova², M., Golchev Y³

Sofia, Bulgaria

Summary

The visual diagnostics of early caries is an extremely important part of the examination, but it cannot detect the changes in the enamel that take place before the occurrence of visible changes

It is the aim of this research to conduct an experiment that will allow us to compare visual observation, the radiographic method, laser fluorescence with DIAGNOdent and the verification with histological examination.

The conducted experiment in vitro aimed at validating the results obtained with DIAGNOdent in the diagnosis of the process of caries shows that this method can give us real results, corresponding to the actual picture of the process. The sensitivity of the method is considerably bigger compared to the method of visual observation, which was conducted separately. It creates possibilities both for an early diagnosis and for the specification of a diagnosis at any stage of the caries process.

Key words: early caries, DIAGNOdent, enamel lesion, diagnostics, laser fluorescence enamel cavitation, visual observation, dentine caries, Kappa statistics.

Modern knowledge about the essence of the caries process – which takes place in stages and within continuous reversible processes – brought about the emergence of a new conception concerning its diagnostics [5]. The possibility for non-operative preventive treatment requires the application of new higher criteria concerning the methods aimed at the verifiable ascertaining of the earliest changes in the enamel [6].

The visual diagnostics of early caries is an extremely important part of the examination, but it cannot detect the changes in the enamel that take place before the occurrence of visible changes [2, 3]. Radiographic examination – which has been incessantly improving its quality and is the perfect complement to visual observation – is not helpful in the diagnosis of the earliest changes of the enamel [4].

It is the aim of contemporary diagnostic methods to make possible an uninvase diagnostics of the early changes of the enamel, thus improving the quality of the diagnosis and making it more reliable.

New diagnostic methods are introduced at the moment aimed at the early ascertainment of a caries process. Such is the method using laser fluores-

cence [1, 5, 6, 10, 11]. One of the instruments employing laser fluorescence in the early diagnosis of caries is DIAGNOdent, created by KaVo, Biberach, Germany, 1998 [7, 8, 9, 14]. It is a caries monitoring equipment using blue and red light with a length of the wave of 655nm (red light), producing <1mW [11, 15, 16, 18]. The red laser light identifies the caries which has a heightened fluorescence compared to the healthy enamel. Caries exposed to the blue light has a decreased fluorescence compared to the healthy enamel [12,13]. This difference in the effect of the two kinds of light is due to the length of the wave.

The methods manifests a very good reproduction with the Kappa coefficient in the the case of internal comparison 0.88 – 0.90 and 0.65 – 0.73 in the case of comparison between the examiners [17, 18,19]. The examination aimed at validating the results from the in vitro examination showed a high sensitivity ranging from 0.17 up to 0.87, while specificity ranged from 0.72 up to 0.98 [20], the comparison with microradiographically determined depth being 0.76 – 0.79 [17, 21,22,23].

It is the aim of this research to conduct an experiment that will allow us to compare visual

¹ Associated Professor, Head of Department of Pediatric Dentistry, Faculty of Dentistry, Sofia, Bulgaria.

² Associated Professor, Department of Pediatric Dentistry, Faculty of Dentistry, Sofia, Bulgaria.

³ Assistant Professor, Department of Pediatric Dentistry, Faculty of Dentistry, Sofia, Bulgaria.

observation, the radiographic method, laser fluorescence with DIAGNOdent and the verification with histological examination.

Material and methods

The experiment was conducted on 30 teeth extracted for orthodontic reasons the structure of which was relatively preserved. The extracted teeth were premolars, third molars and incisors.

Immediately after the extraction the teeth were carefully washed with a brush so that soft tissue, blood and pigments were removed. The teeth were placed in a 1% solution of timol till the moment the observation started.

The teeth were numbered and prepared for observation. They were washed out with a physiological solution of the kind they were preserved in. During the research the teeth were not allowed to dehydrate. They were dried only when the examination had to take place.

The experiment was conducted by three examiners from the Department of Children's dental medicine – Sofia. The manager of the experiment calibrated the teeth in advance as required by the methodology applied.

The experiment took place in three parts:

1. Individually and independently diagnosing with each method separately – visual observation, laser fluorescence through DIAGNOdent and applying the radiographic method;
2. Evaluation of the histological finding and determining a “gold standard” for the lesions observed;
3. Comparison with the gold standard and determining the sensitivity and specificity of the different methods applied.

The examiners diagnosed each separate lesion visually observing it under light and independently from one another. The surface, place and size of the lesion were recorded. Specified were the size of the lesion, the colour, polish of the enamel (if preserved), the occurrence of unevenness or cavitation, proximity to a gingival edge or fissure. In accordance with these criteria each lesion was evaluated as D1, D2, D3, D4. The visual search for lesions D0 on the extracted teeth proved impossible.

The data were recorded on separate sheets of paper for each tooth.

After that the teeth were photographed with a digital camera. Each picture was numbered with the number of the tooth. In the case of teeth that had more than one lesion a separate picture was taken of each lesion.

Each tooth and lesion was X-rayed. Each radiograph was numbered with the number of the tooth examined.

At the next stage of the research each examiner separately and independently from the other two and not looking on the preliminary visually obtained diagnosis carried out a measurement of each lesion using DIAGNOdent pen. There was period of two weeks between the clinical examination and the examination by means of an apparatus. Each quantity measured was recorded on a separate sheet of paper with the number of the tooth and the localisation of the lesion.

Before taking to measuring using laser fluorescence, each tooth was dried up. Diagnodent pen was calibrated towards the production standard and after that towards the individual healthy enamel surface of the tooth examined. The calibrating was carried out independently by each of the three examiners. A sound was used for the measurement of the lesions on the fissures and the smooth enamel surfaces. The sound was placed perpendicularly towards the surface studied and the corresponding lesion. After obtaining a light contrast with the lesion the sound was very carefully shaken so that the periphery of the lesion could be scanned by the laser beam from a different angle. After such a procedure a peak quantity was registered and recorded.

So that the reproductiveness of the laser fluorescence was determined agreement between the examiners had to be achieved through repeating the research described a week later, the teeth being given a new code system, determined by the leading examiner. This new system was added to the previous one and was put in a new envelope till the end of the examination.

The next day each examiner summarised his observations from the X-rays and recorded the results on separate sheets of paper. Monitored was the degree of development of the caries process in accordance with its depth in terms of a five-stage scale:

- 0 – no caries process;
- 1 – caries process that has reached the midline of the enamel;
- 2 – caries process that has reached the enamel-dental border;
- 3 – caries process in the first half of the dentine;
- 4 – caries process that has engaged the inner half of the dentine.

Diagnostic scale of the producer

Values, obtained through DIAGNOdent	Types of caries lesions
0 – 14	Enamel lesion, situated on the inner half of the enamel
15 – 20	Enamel lesion, situated on the inner half of the enamel but not affecting the enamel-dental border
Over 21	Caries lesion affecting the dentine

After being through with all the observations and measurements, the experiment comes to an end with the stuffing of the teeth through the lesions observed so that histological examination could be conducted, thus a gold standard being used so that the depth of the process was be validated. Each tooth was cut with a diamond perpendicularly to the lesion observed and cooled with water. The cuts in the case of occlusal lesions were made perpendicularly to the surface occluded, while in the case of the vestibular and approximal lesions – perpendicularly to the smooth surface. The surfaces cut were polished by hand with polishing paper thus a smooth surface being obtained.

A five-degree histological scale was used:

- 0 – healthy enamel;
- 1 – enamel caries, restricted to the outer 1/2 of the enamel;
- 2 – enamel caries on the inner 1/2 of the enamel, the enamel-dental border not being affected;
- 3 – dentine caries affecting the outer one third of the dentine;
- 4 – dentine caries affecting the bigger part of the dentine.

Each lesion examined was evaluated histologically by each examiner separately and independently, the classification being carried out along the above scale. This evaluation was used as a gold standard that was later employed in evaluating the efficiency of the other methods.

The statistical processing of the results was carried out through the application of intra and inter-examiner agreement, obtained by means of the Kappa statistics of Cohen. Sensitivity, specificity, value, positive results expected and negative results expected were determined.

On the 30 extracted teeth each examiner registered a total of 89 lesions. Only one of the examiners had only found 88 lesions. The preliminary coefficient of agreement was 0,98. This result is seen as an excellent starting agreement between the examiners and guarantees the reliability of the results.

The analysis of the results started with the creation of a gold standard for the histological examination. Thus a common basis for comparisons with the other methods was obtained. Determined was the degree of agreement between the examiners, the inner reproducibility with the help of the first and the second results from the measurement of the lesions in the case of each examiner separately, as well as the sensitivity, specificity, exactness of the method and the capacity that the method provides for predicting positive and negative results.

Results and discussion

Out of the 89 lesions monitored only 64 were studied histologically. The other were harmed during the procedures and could no longer be used for further examination.

The 58 lesions monitored were divided into categories in the following way:

- D1a – 8 lesions situated on the outer one third of the enamel;
- D1b – 14 lesions situated to the midth of the depth of the enamel;
- D2 – 25 lesions comprising almost the whole enamel and reaching near the enamel-dental border, not affecting it, though;
- D3a – 10 lesions covering the outer half of the dentine;
- D3b – 9 lesions covering the whole dentine.

The classification of the lesions by histological examination was carried out by the three examiners separately and independently, the Kappa coefficient arrived at showing a degree of 0,96, which we saw as excellent.

Each next comparison of the results was objectivised by means of a histological classification of the corresponding lesion.

It is seen from the above results that the visual method does not show very good sensitivity. The general sensitivity is 0,62. Lowest is the sensitivity concerning distinguishing lesions D1a and D2. The visual diagnosis of D1a is unreliable. Lesions D2 were usually perceived either as D1b, when situated on the smooth surfaces, or as D3, when situated on fissure or in dents. Relatively low is the sensitiv-

Table 1. Results from the visual examination

	Sensitivity	Specificity	PPV	NPV	Exactness	Kappa (inter)	Kappa (intra)
Total	0,62 (0,21)	0,72 (0,12)	0,44 (0,09)	0,78 (0,05)	0,63 (0,08)	0,79 (0,11)	0,82 (0,10)
D1a	0,14 (0,18)	0,72 (0,13)	0,12 (0,28)	0,76 (0,12)	0,12 (0,19)	0,43 (0,22)	0,84 (0,11)
D1b	0,68 (0,19)	0,78 (0,16)	0,48 (0,21)	0,82 (0,11)	0,62 (0,14)	0,70 (0,12)	0,87 (0,09)
D2	0,59 (0,19)	0,72 (0,14)	0,42 (0,18)	0,76 (0,15)	0,63 (0,13)	0,68 (0,17)	0,84 (0,08)
D3a	0,61 (0,14)	0,74 (0,12)	0,52 (0,19)	0,70 (0,18)	0,68 (0,12)	0,68 (0,16)	0,80 (0,11)
D3b	0,68 (0,13)	0,78 (0,12)	0,58 (0,09)	0,84 (0,08)	0,78 (0,17)	0,67 (0,08)	0,84 (0,10)

* PPV – Positive predictive value;

* NPV – Negative predictive value;

* Presented are the values of the indexes and the standard deviations.

ity concerning the diagnosis of the dentine caries situated in the outer part of the dentine. Mistakes were made there with D2. Specificity, on the whole, is higher when it comes to the visual method of monitoring. This means that the corresponding diagnoses can be rejected with a much bigger degree of certainty. The capacity for predicting positive results with specific types of lesions is pretty low. Lowest is the value of the index concerning the enamel caries situated on the whole enamel, and highest is the one concerning the dentine caries situated in the whole dentine layer or concerning the deep caries. These case can be very easily ascertained by means of visual observation. Much bigger is the power of the visual method in determining negative results. The values here are higher, the highest being the values concerning

deep dentine caries. The index showing the proportion of positive results compared to all other results shows the same correlation. Lowest is the exactness concerning the enamel caries. Kappa statistics shows that the agreement between the examiners is somewhere between good and very good. The reproductiveness of the results from the visual observation are very good, which is seen from the high values of the intra-comparison between the examiners.

Diagnostics with laser fluorescence shows very good results. The sensitivity of the method when applied within the in vitro examination proved to be pretty high, regardless of the fact that the teeth were out of their normal oral environment. The methods creates possibilities for the obtaining of a pretty exact diagnosis, a diagnosis that does not

Table 2. Results from the researches with DIAGNOdent

	Sensitivity	Specificity	PPV	NPV	Exactness	Kappa (inter)	Kappa (intra)
Total	0,88 (0,12)	0,79 (0,13)	0,88 (0,10)	0,82 (0,14)	0,87 (0,10)	0,88 (0,10)	0,89 (0,10)
D1a	0,87 (0,11)	0,76 (0,16)	0,89 (0,14)	0,81 (0,13)	0,85 (0,12)	0,86 (0,12)	0,87 (0,09)
D1b	0,84 (0,13)	0,74 (0,15)	0,90 (0,09)	0,73 (0,11)	0,84 (0,12)	0,90 (0,09)	0,91 (0,09)
D2	0,93 (0,10)	0,76 (0,15)	0,92 (0,11)	0,76 (0,14)	0,86 (0,09)	0,84 (0,11)	0,90 (0,09)
D3a	0,89 (0,11)	0,90 (0,1)	0,78 (0,15)	0,83 (0,12)	0,88 (0,09)	0,86 (0,11)	0,86 (0,11)
D3b	0,87 (0,12)	0,8 (0,11)	0,88 (0,12)	0,86 (0,10)	0,89 (0,11)	0,84 (0,09)	0,84 (0,13)

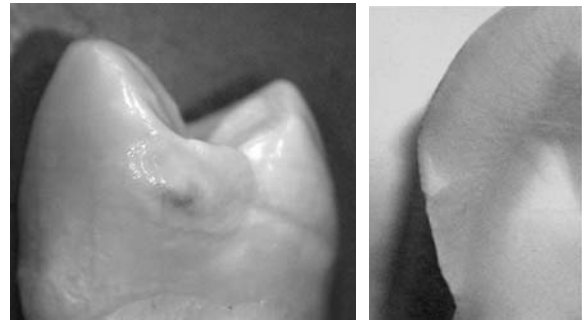
differ much from the real one arrived at by means of the gold standard. On the whole, the sensitivity of the method with regard to all lesions monitored is 0,88, which is a pretty high result. This shows that the method can detect pretty reliably lesions on the occlusal and smooth surfaces situated in the enamel and the dentine. Biggest is the sensitivity with regard to lesions D2. The sensitivity of the method is considerably better compared to the visual method of diagnostic and improves the possibilities for arriving at more precise diagnoses. More reliably are also detected the early lesions. The specificity of the method proved higher than its sensitivity or the possibility for detecting negative cases proved smaller. The values of the indexes for predicting positive or negative results are reliably higher compared to those in the case of the visual diagnostic method.

The exactness of the method show reliably higher values too. This is to show that the method of diagnostication of the early caries lesions through laser fluorescence really creates a better possibility for diagnostication compared to the mere visual method.

The reproducibility between the first and second measurement shows pretty high values, which reassures us about the validity of the results obtained. Of course, in a real oral environment there are much bigger possibilities for a change in the conditions within the research, which can diminish these values. Such are differences in the angle of the ray as it falls upon the corresponding surface, differences in the degree of cleaning up or drying up the teeth, etc.

The agreement between the different examiners shows good results too. Regardless of the fact that two of the examiners had no big experience working with the instrument in clinical conditions, they easily adapted themselves to the work and proved very precise in accomplishing the scanning. The values of this index too proved higher compared to agreement achieved within the visual method. This makes us believe that the instrument is reliable in work. The good results are partly due to the easy work with it.

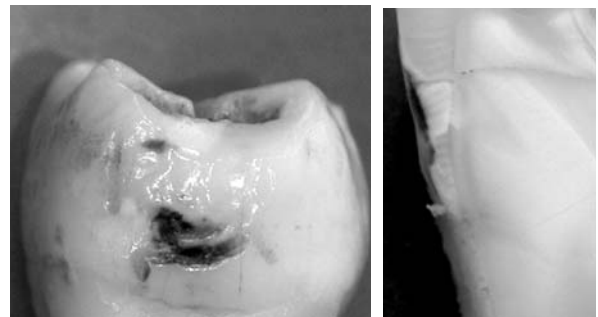
The research with DIAGNOdent show results which correspond to the standards embraced. After the preliminary calibrating of the instrument according to the standard given by the producer and after calibrating the instrument in accordance with the individual value of each concrete tooth, the measurement was carried out and the results recorded according to the method described.



Pictures 1 and 2 Approximal surface of a premolar

A lesion with a yellow-brown centre can be observed, round which whitening is seen. The enamel surface is smooth and shiny. The visual diagnosis was D2. The lesion was defined as stationary. The laser diagnosis showed in the centre value 7, and around – in the white zone of the lesion – value 4. The value of the brown part corresponds to D1b, and the value of the white part – to D1a. We were interested to cut the tooth through the part around the brown zone, which had minimum whitening. The aim was to look for earlier changes in the enamel. In this part the laser diagnostic showed a value of 4, while visually almost no difference was discovered.

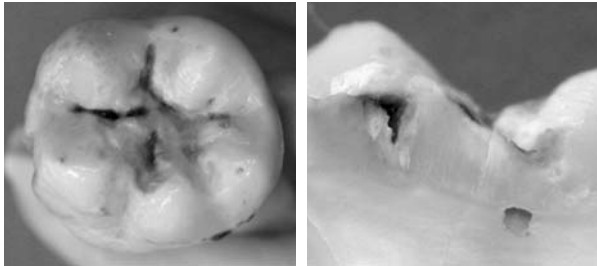
A white lesion was discovered histologically, situated on the outer one third of the enamel. On the zone of the progressing front of the spot is a bit deeper. The lesion is with preserved enamel surface. The laser diagnostic is indicative of D1a. Histologically, the process is in the outer part of the enamel and should be corresponding to a bit higher value. This lesion, observed visually, is stationed and this explains the lower value of the laser diagnostic.



Pictures 3 and 4 Macroscopic and microscopic picture of a dark brown cavitated approximal lesion

The visual diagnosis of two of the examiners is D3 and of the third one – D2. The laser diagnostic

shows a value of 27. Histologically, a cavitated enamel caries is observed with an engagement of the enamel-dentine border and the periphery of the dentine. The laser diagnostics specifies the diagnosis and is closest to the histological one.



Pictures 5 and 6 Visual picture of the occlusal surface of a molar

The photo presents coloured fissures, in the deep part of which was found a caries process. The lesions are black in colour, inactive with shiny enamel along the fissures. The diagnosis determined by the examiner is D2.

The examination with DIAGNOdent shows a medium value from the three examiners 12. This value indicates that the lesion, which visually looks like being in a more advanced stage, should rather be determined as D1b.

The histological finding shows that half of the enamel surface is harmed in the zone of the fissure. The inner half of the enamel has no changes, which corresponds to the values obtained by means of laser fluorescence.

Generalisation of the results

The conducted experiment in vitro aimed at validating the results obtained with DIAGNOdent in the diagnosis of the process of caries shows that this method can give us real results, corresponding to the actual picture of the process. The sensitivity of the method is considerably bigger compared to the method of visual observation, which was conducted separately. It creates possibilities both for an early diagnosis and for the specification of a diagnosis at any stage of the caries process. This method which uses laser fluorescence is not the best of all possible. Much bigger is the potential of QLF. Nevertheless, its easy use, portability, small size and low price make it very competitive and practical.

The possibility for using the method in epidemiological researches makes it an invaluable aide in the early diagnostics of the caries process.

The comparative research conducted comparing the visual method and the method of laser fluo-

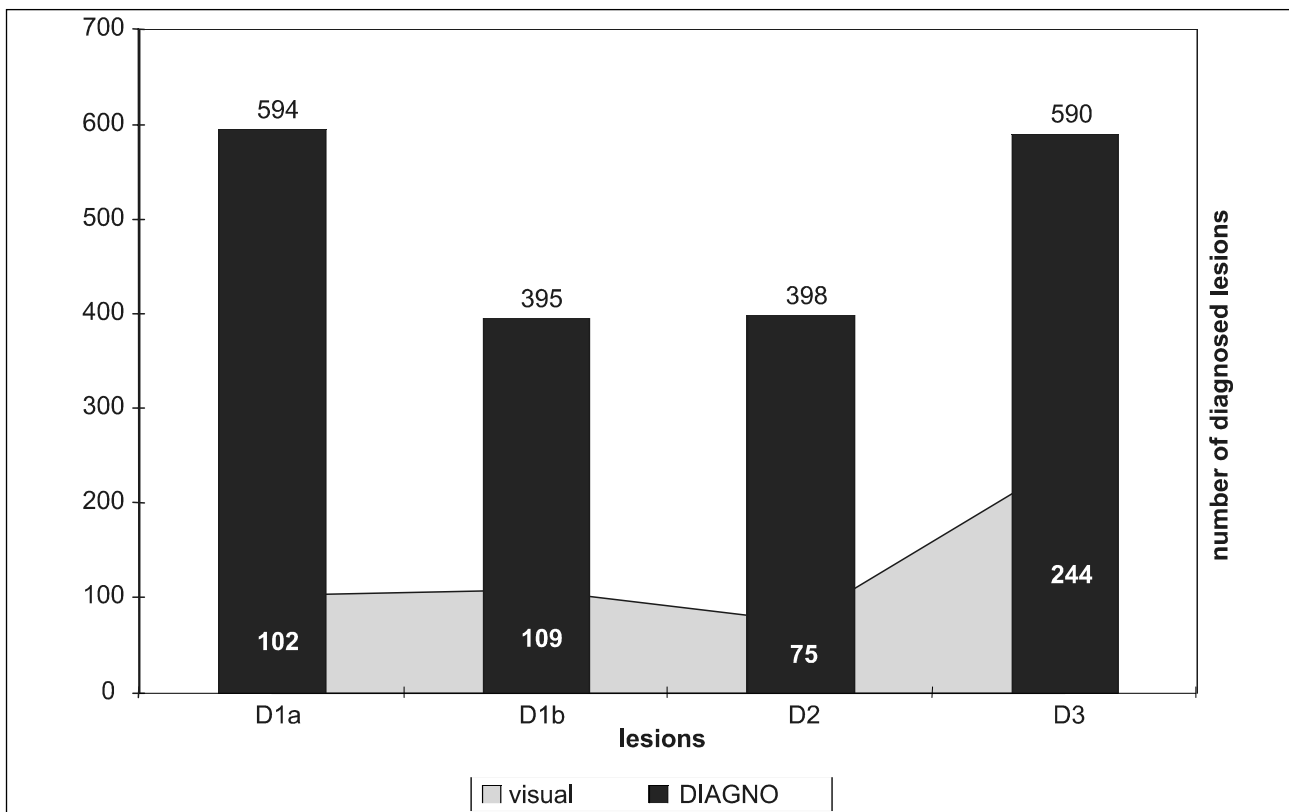


Diagram 1. Comparison of the number of diagnosed lesions of each kind in the case of visual diagnostics and DIAGNOdent

rescence employing DIAGNOdent showed that laser fluorescence is much more sensitive.

It is clearly seen from the above diagram that the visually diagnosed lesions are considerably smaller than the ones detected with the help of DIAGNOdent. Laser fluorescence make it possible for very small and invisible differences between a normal and healthy enamel surface, on the one hand, and an enamel surface undergoing initial slight changes, on the other hand, to be detected. This is extremely important in the case of the earliest changes, termed here D1a. The difference between the two methods is considerable. The possibilities of the visual method as far as the very early changes are concerned are very limited. The changes observed when examination with DIAGNOdent was applied were not accidental. All possible measures aimed at removing the plaque and other deposits – that could alter the results from the research – were taken. The values arrived at were obtained by means of a preliminary individual calibrating and repeated measurements, comparisons being done with healthy surfaces unaffected by a caries process. Changes in the value ranging from 0 or 1 to 6 showed a small yet real change. These results must be trusted because the surfaces observed were situated under a solid plaque biofilm accumulated. The children who have such lesions had a very poor oral hygiene, active caries lesions and intermediate carbohydrate nutrition. The very occurrence of these factors made the children members of the risk group. Bearing in mind the age, which is a risk factor too, the picture shows the presence of conditions for the development of an active caries process. That is why the results obtained, confirming the occurrence of an initial process, are so important with regard to our capacity to manage the caries process. If there is any suspicion of hyperdiagnostics, we must remember that the results from the laser diagnostics correspond to the strong risk factors occurring, which is indicative of there being a caries process.

That is why we can make the conclusion that laser fluorescence can be used in detecting the beginning of a caries process.

Another moment showing the imperfection of visual diagnostics is the differential diagnostic between D1b and D2. Both stages represent enamel caries. Both manifest a white lesion. While we found out that we have reliable criteria for determining the activity of the lesion, which allows a preventive therapeutic intervention, the determin-

ing of the actual size of the affected part of the enamel proved to be impossible. A visual distinction can only be made with regard to the present enamel cavitation. Any other visual conclusion would be highly subjective.

The results obtained with the help of DIAGNOdent pointed at two facts. The first fact is that the cavitation of the enamel may not exist and that the enamel may only be affected to the enamel-dentine border. This means that a white lesion with preserved enamel surface (extra-porous, though), which we often classify as D1b, is very often D2 actually. This cannot be determined visually. Indirect symptoms could be found, but they would not be reliable. DIAGNOdent provides us with the possibility to specify – by means of detecting the different fluorescence of the differently demineralised enamel surface - these two phases in the enamel caries. The distinction is very important because of allowing us to make a choice within the therapeutic process. The early detection of an advanced stage will allow us to apply a non-operative approach, which can also be enhanced by a modelling of the risk factors, thus making possible the stopping and even the regression of the present caries process.

In the diagnosis of every third lesion, a possibility was found for laser fluorescence to specify the results from the visual diagnostic and to create a much clearer picture concerning the stage and the risk situation. Specified are the border between D1a and D1b, between D1b and D2, between D2 and D3, as well as between D3 and D4.

As a matter of fact, DIAGNOdent is not the most perfect early diagnosis instrument based on laser fluorescence. QLF is much better, but DIAGNOdent's low price, small size and portability as well as its being very easy to work with makes it very handy both for clinical diagnostic and for application in epidemiological researches.

The above diagram shows that that the visual method of diagnostics creates a real possibility for underestimating the actual condition of the affected enamel surface. The big imprecision of the visual method is the result of the lack of sensitivity due to the impossibility to distinguish between the different degrees of change. The visually detected lesions are usually in a more advanced stage of development of the process. The specification of the stage is important if the correct therapeutic method is to be chosen, though. The risk of underestimating a lesion at any stage in its development is real and it limits the possibility for a non-operative preventive

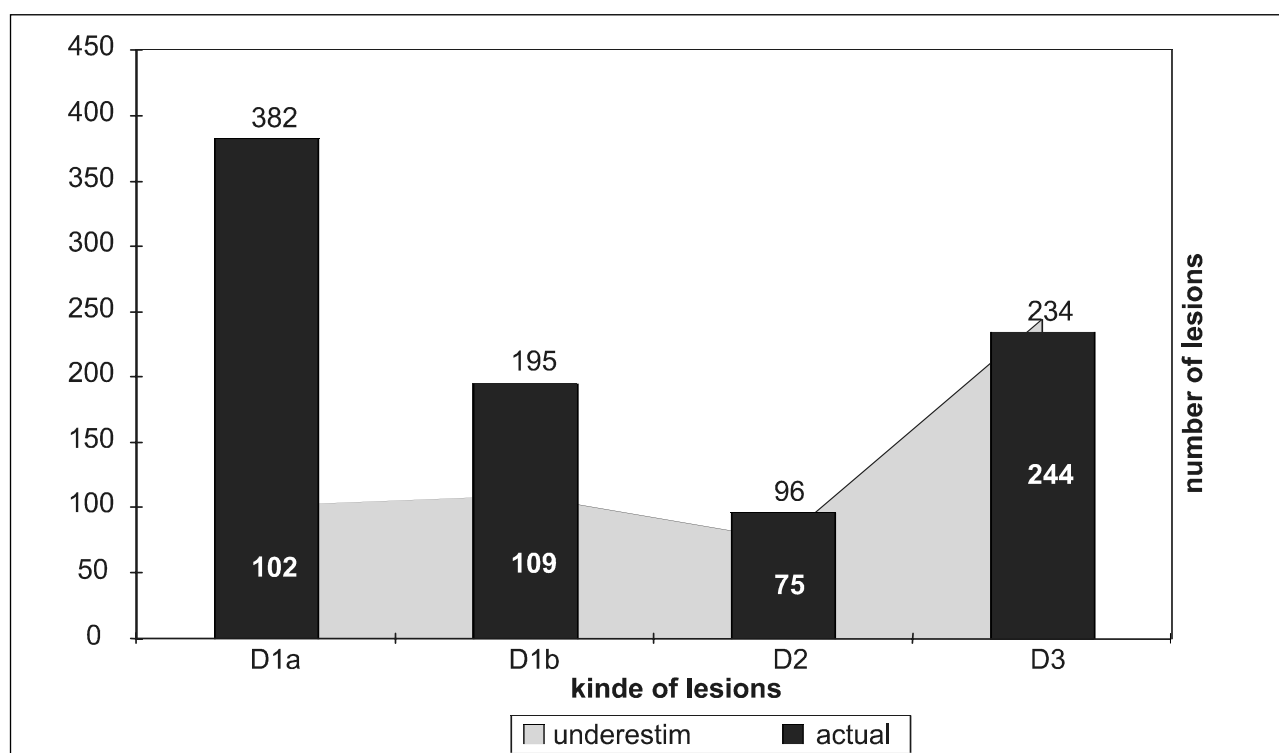


Diagram 2 Comparison between the actual and underestimated cases

treatment. When the problem is neglected, no treatment is undertaken and the risk environment is not modelled. The caries process is left to develop and at the next the lesion already requires operative treatment. Hence the importance of every new diagnostic method enabling the early detection of the changes and distinguishing between the different stage – it makes possible very the application of the non-operative therapeutic approach.

Conclusions

1. The visual methods of diagnostics is unable to detect the earliest changes in a caries process underway;

2. The visual method is not precise enough to make possible the differential diagnostics of the different changes in the development of the caries lesions;

3. The instrument DIAGNOdent enables precise diagnosing, the results obtained with it being validated by means of a histological finding;

4. Laser fluorescence through DIAGNOdent is of real in the early diagnosing of reversible lesions;

5. Laser fluorescence is very helpful in the differential specification of the stage of structural change undergone within the caries process.

References

1. Aljehani A, S Tranaecus, CM Torsberg, Angmar-Mansson X, Q Shi. In vitro quantification of white spot enamel lesions adjacent to fixed orthodontic appliances using quantitative light-induced fluorescence and DIAGNOdent. *Acta Odontol Scand*, 2004; **62**(6): 313-8.
2. Bader JD, Shugars DA, Bonito AJ: A systematic review of the performance of methods for identifying carious lesions. *J Public Health Dent* 2002; **62**(5):201-213.
3. Bader JD, Shugars DA: A systematic review of the performance of a laser fluorescence device for detecting caries. *JADA*, 2004; **135**(10): 1413 – 1426.
4. Baelum V, Fejerskov O: Caries diagnosis: A mental resting place on the way to intervention?; in Fejerskov O, Kidd EAM (eds): *Dental Caries - The Disease and Its Clinical Management*. London, Blackwell Munksgaard, 2003; pp. 101-110.
5. Baelum V, Machiulskiene V, Nyvad B, Richards A, Væth M: Application of survival analysis to carious lesion transition in intervention trials. *Community Dent Oral Epidemiol* 2003; **31**(3): 252-260.
6. Bamzahir M, X Shi, B Angmar-Mansson. Occlusal caries detection and Iuantification by DIAGNOdent and Electronic Caries Monitor: in vitro comparison, *Acta Odontol Scand*, 2002; **60**(4): 360-364.
7. Boston DW. Initial in vitro evaluation of DIAGNOdent for detecting secondary carious lesions associated with resin composite restorations, *Quintessence Int*, 2003; **34**(2): 109-16.
8. Beseren N, S Gokalp. Validity of a laser fluorescence system (DIAGNIdent) for detection of occlusal caries in third molars: an in vitro study. *J Oral Rehabil*, 2003; **30**(12): 1190-1194.
9. Chong MY, Seow WK, Purdie DM, Cheng E, Wau V. Visual-tactile examination compared with conventional radi-

ography, digital radiography, and DIAGNOdent in the diagnosis of occlusal occult caries in extracted premolars. *Pediatr Dent*, 2003; **25**(4): 341-9.

10. Costa AM, Yamaguti BM, Da Paila LM, Bazerra AC. In vitro study of laser diode 655 nm diagnosis of occlusal caries. *ASDC, J Dent Child*, 2002, Sep-Dec, **69**(3): 249-53, 233.

11. Francescut P, Lussi A. Correlation between fissure discoloration. Diagnodent measurement, and caries depth: an in vitro study. *Pediatr Dent*, 2003; **25**(6): 559-64.

12. Hall A, E Deschepper, M Ando, G Stookey. In vitro studies of Laser Fluorescence for Detection and Quantification of Mineral Loss from Dental Caries. *Adv Dent Res*, 1997; **11**(4): 507-514.

13. Iwami Y, Shimizu A, H Yamamoto et al. In vitro study of caries detection through sound dentin using a laser fluorescence device, DIAGNOdent. *Eur J Oral Sci*, 2003; **111**(1): 7-11.

14. Krause F, Braun A, Frentzen M. The possibility of detecting subgingival calculus by laser fluorescence in vitro. *Laser Med Sci*, 2003; **18**(1): 32-5.

15. Kühnisch J, K Bücher, V Henschel, R Hickel. Reproducibility of DIAGNOdent 2095 and DIAGNOdent Pen measurements: results from an in vitro study on occlusal sites. *European Journal of Oral Sciences*, 2007; **115**(3): 206-211.

16. Lussi A, P Francescut. Performance of conventional and new methods for the detection of occlusal caries in deciduous teeth. *Caries Res*, 2003; **37**(1): 2-7.

17. Mendes FM, Hissadomi M, Imporato JC. Effects of drying time and the presence of plaque on the in vitro performance of laser fluorescence in occlusal caries of primary teeth. *Caries Res*, 2004; **38**(2): 104-108

18. Morgan M. Dental laser identifies early stage of caries. *Dent Today*, 2000; **19**(2): 30-33.

19. Moore D, N Wilson A review of modern non-invasive systems for caries detection, *CPD Dentistry*, 2001; **2**(3): 86-90

20. Reis A, VL Zach, de Lima AC et al. Occlusal caries detection a comparison of DIAGNOdent and two conventional diagnostic methods. *J Clin Dent*, 2004; **15**(3): 76-82.

21. Ross, G., Caries diagnosis with the DIAGNOdent laser : a users product evaluation, *Ontario Dentist*, 1999; **76**(2): 21-24.

22. Ten Cate JM, M Lagerweij, J Wefel et al. In vitro validation studies of quantitative light-induced fluorescence. In: Early detection of dental caries II. Stookey GK, editor. *Indianapolis*, pp. 231-250.

23. Tonioli M, M Bouschlicher, S Hillis. Laser fluorescence detection of occlusal caries, *Am J Dent*, 2002; **15**(4): 268-73.

Correspondence to: Dr. Mila Peneva, DMD, PhD, Head of the Department of Children's dental medicine, Faculty of Dental medicine-Sofia