

An Encysted Gossypiboma: A Laparotomy Surprise

Dr. Bharat Sangal*, Dr. Naveen Kumar, Dr. Julie and Dr. Jaydeep

Department of General Surgery, All India Institute of Medical Sciences, Rishikesh, India

ABSTRACT

A review case of a 49 year old female presenting with an abdominal lump with a provisional diagnosis of mesenteric hydatid cyst which on exploratory laparotomy was found to be a large purulent cystic mass with an old surgical mop.

Keywords: Gossypiboma; Laparotomy; Hydatid cyst

INTRODUCTION

Retained foreign bodies, such as sponges, gauze or instruments, after any surgical procedures are considered a serious blunder and has several medico-legal implications. The term "gossypiboma" refers to a mass of cotton/cloth retained in the body after any intervention [1]. Although having a rare incidence, it does come with significant morbidity and mortality. Most cases of retained foreign bodies are picked up after few days of surgery but some have been diagnosed even many years later [2]. Less reporting of such cases due to fear of legal aspects make the actual incidence estimation a tough job [3]. Estimation puts the risk of gossypiboma in 1 out of 300-1000 of all surgical interventions and 1 out of 1000-1500 of intraabdominal operations [4]. The manifestations and complications of gossypibomas are so variable that diagnosis is difficult. Routine imaging techniques like X ray, Ultrasound, CT and MRI may prove helpful in clinching the diagnosis [5].

This case is an important pearl for all surgeons, so as to keep in mind a high suspicion in similar cases especially due to their life threatening and medico-legal implications.

CASE REPORT

A 49 year old female presented with complaints of non-colicky, mild pain in the lower abdomen for 3 months not associated with any altered bowel habits or any difficulty in micturition. She noticed a lump in her lower abdomen around 3 months which progressed to its current size of around 10 × 15cm. the patient had no complaints of fever, loss of appetite or loss of weight.

She had undergone an abdominal hysterectomy with bilateral hysterectomy 4 years back in view of a uterine fibroid. Her

postoperative period was uneventful but the patient had similar lower abdominal pain intermittently for the last 4 years which was managed by over the counter medications. She did not report of any hospital admission for the same in the past 4 years.

The patient was well built with no pallor and stable vitals. Abdominal examination showed a large lump in the lower abdomen involving the hypogastrium, inferior paraumbilical region and bilateral iliac fossa. The lump was cystic, non-tender, with restricted mobility and dull on percussion with no overlying band of resonance. A healthy pfannenstiel incision was noted over the lower edge of the lump. Rest of abdomen was normal (Figure 1).

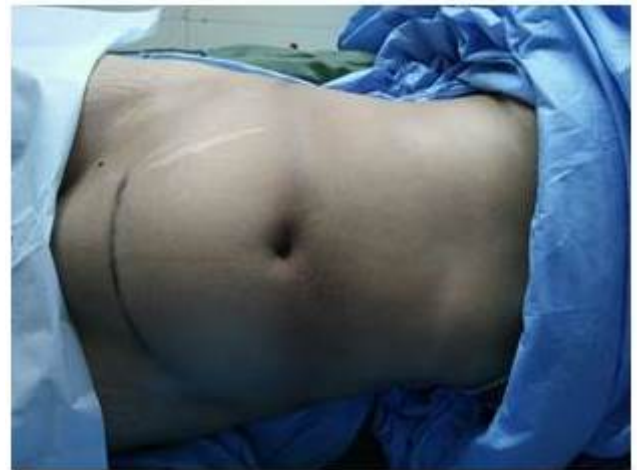

Figure 1: Prop View with previous pfannenstiel incision.

The CECT abdomen was suggestive of a well-defined rounded predominantly cystic lesion with floating internal membranes,

*Correspondence to: Bharat Sangal, Department of General Surgery, All India Institute of Medical Sciences, Rishikesh, India, Tel: 919871944907; E-mail: bharatsangal@hotmail.com

Received: November 02, 2018; **Accepted:** December 07, 2018; **Published:** January 16, 2019

Citation: Sangal B, Kumar N, Julie, Jaydeep (2019) An Encysted Gossypiboma: A Laparotomy Surprise. Trop Med Surg 7:222. doi: 10.35248/2329-9088.7.1.222.

Copyright: © 2019 Sangal B, et al. This is an open-access article distributed under the terms of the Creative Commons Attribution License, which permits unrestricted use, distribution, and reproduction in any medium, provided the original author and source are credited.

measuring 15.8 × 15.1 × 11.3 cm with linear calcifications displacing the surrounding bowel loops; consistent with a large mesenteric hydatid cyst (Figure 2a and b).

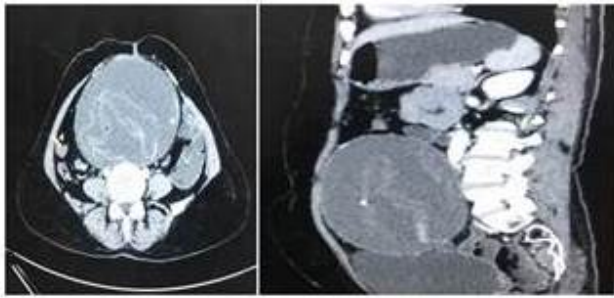


Figure 2: CECT abdomen (Transverse view)-large cystic mass with internal floating membranes (a) CECT abdomen (sagittal view) large cystic mass with internal floating membranes (b).

The intra operative findings showed a large cystic mass adhered to the mesentery and the distal ileum around 2 feet proximal to the IC junction (Figure 3). The cyst was carefully dissected and excised without any evidence of spillage (Figure 4). The cyst was opened on the dissection table which drained around 400 ml of purulent fluid and an old surgical mop (Figure 5). The patient had an uneventful postoperative period and was discharged after 5 days in a good healthy general condition.

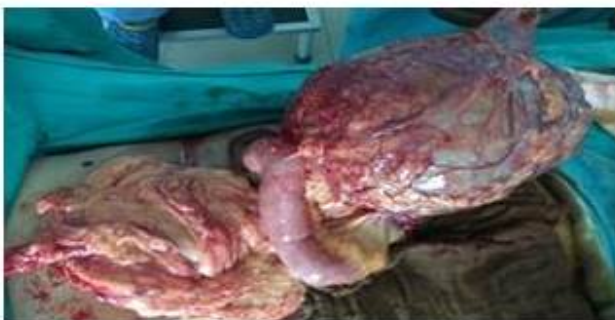

Figure 3: A large cystic mass adhered to mesentery and distal bowel.

DISCUSSION

Gossypiboma or retained sponge is an important topic of discussion as it leads to significant embarrassment and can lead to a lawsuit as well.

Factors leading to an increased risk of a retained foreign body include emergency surgery, long surgeries, unexpected change in procedure, poor communication, change of staff intraoperatively, inexperienced staff and obese patients [6].

They do not cause any specific reaction except adhesions and granuloma formation and hence may stay asymptomatic for a long time. An exudative reaction leads to the formation of an abscess and a fibrotic aseptic reaction forms a granuloma and hence a development of a mass [7]. Our case was a mixture of the two leading to an encysted collection around the surgical mop.

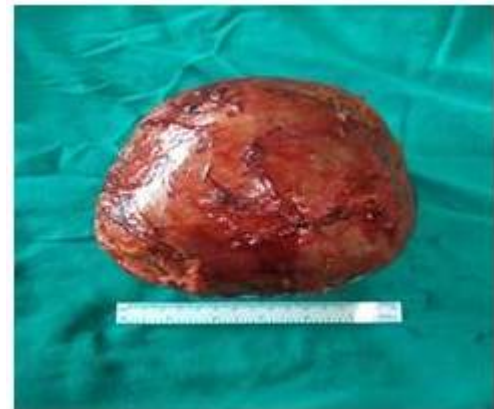

Figure 4: The cyst was carefully dissected and excised without any evidence of spillage.

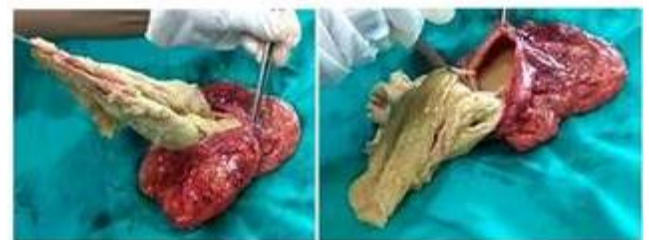

Figure 5: Old surgical mop with pus encased within the cystic mass.

Patients can present with nonspecific abdominal pain and intestinal obstruction, a palpable mass, nausea, vomiting, abdominal distension, and pain [5]. The symptoms depend upon the location, size of swab, and the type of reaction that occurs. Patients may rarely also present with fistula, perforation, or even extrusion per anus. Various imaging findings can help us to diagnose gossypiboma.

Radiographs are the most commonly used method to detect retained sponges due to the presence of a radio opaque marker seen as a characteristic whorl like pattern. They can reveal a fine opacity and some superimposed mottled small air densities [8].

CT is the imaging of choice for detecting retained gauze with a characteristic spongiform pattern with gas bubbles often containing wavy striped high density areas [8].

On an MRI, a retained sponge is typically seen as a soft-tissuedensity mass with a thick well-defined capsule; and as a whorled internal configuration on T2-weighted imaging[8]. Surgical removal is the mainstay of treatment of any retained foreign body which is usually done through the previous surgical site but an endoscopic or laparoscopic approach may be attempted.

Such cases are best prevented by being vigilant during surgery and to follow a thorough mop count before, during and after the surgery. New technologies are being developed such as sponges with a radiofrequency chip which can be identified by a bar code scanner [9].

A gossypiboma is a serious and life threatening condition and has severe medicolegal implication, and hence should be prevented at all costs.

This case is an important revisit for any clinician to keep a high suspicion for this diagnosis especially in patients with abdominal pain, lump, fever in the setting of a past surgery.

REFERENCES

1. Sharma D, Pratap A, Tandon A, Shukla RC, Shukla VK. Unconsidered cause of bowel obstruction-gossypiboma. *Can J Surg.* 2008;51:34-35.
2. Colak T, Olmez T, Turkmenoglu O, Dag A. Small bowel perforation due to gossypiboma caused acute abdomen. *Case Reports in Surgery.* 2013.
3. Tarik U, Gokhan DM, Sunay YM, Mahmut A. The Medico-legal importance of Gossypiboma. 2009;82-83.
4. Dakubo J, Clegg-Lampsey J, Hodasi W, Obaka H, Toboh H. n intra-abdominal gossypiboma. *Ghana Med.*2009; 3:43-45.
5. *American Journal of Roentgenology* 2009;193.
6. Srivastava KN, Agarwal A. Gossypiboma posing as a diagnostic dilemma: a case report and review of the literature. *Case Rep Surg* 2014;713428.
7. Kataria SP, Garg M, Marwah S, Sethi D. Acute abdomen by gossypiboma. *Ann Trop Med Public Health.*2012; 5:511-513.
8. O'Connor A, Coakley F, Meng M, Eberhardt S. Imaging of retained surgical sponges in the abdomen and pelvis. 2003;180: 481-489.
9. Macario A, Morris D, Morris S. Initial clinical evaluation of a handheld device for detecting retained surgical gauze sponges using radiofrequency identification technology. *Arch Surg.* 2006'; 141: 659-662.