

# A Controlled Randomized Trial Assessing Regenerative Therapy in Healing of Chronic Pressure Ulcers

Mahmoud F. Sakr<sup>1\*</sup>, Hossam M. Hamed<sup>2</sup>, Chen Y. Chong<sup>3</sup>

<sup>1</sup>Department of Surgery, Faculty of Medicine, Alexandria University, Alexandria, Egypt; <sup>2</sup>Department of Surgery, Ahmadi Hospital, Kuwait Oil Company (KOC), Ahmadi, Kuwait; <sup>3</sup>Department of Burns, Wounds and Ulcers of Beijing Nanyuan Hospital, Beijing, China

## ABSTRACT

**Aim:** To assess the efficacy and safety of regenerative therapy as compared to wet-to-moist saline dressings in healing of chronic pressure ulcers (CPUs).

**Method:** Consecutive patients (n=105) with CPUs (n=218) treated at three different hospitals were randomized to receive Moist Exposed Burn Ointment (MEBO) dressings (Regenerative group, n=55 with 115 ulcers) or wet-to-moist saline dressings (Control group, n=50 with 103 ulcers). Data collected prospectively included demographics, clinical, biochemical and ulcer features. Ulcer surface area (SA) and healing index (HI) were calculated and compared at two-week intervals for 12 weeks.

**Results:** Sixty-one patients (58.1%) were male and 44 (41.9%) were female. Their mean age was 69.5 years. There was an increase in HI and reduction in SA starting at two and four weeks, respectively in the regenerative group. At 12 weeks, 61.7% (71/115) of ulcers treated with MEBO had complete healing (HI=1) versus 28.2% (29/103) of controls (p=0.000). None of the patients receiving MEBO had a HI of <0.5 at 12 weeks as compared to 25.2% of controls (p=0.000). Significantly (p<0.01) more grade 2-4 ulcers healed completely with MEBO by 12 weeks. No adverse effects or allergic reactions were noted by 12 weeks.

**Conclusion:** In addition to its safety, MEBO significantly promotes the healing of CPUs with significant increase in HI of any given ulcer as early as two weeks of treatment, and significant reduction of ulcer SA starting at four weeks with complete healing of more than 60% of ulcers by 12 weeks.

**Keywords:** MEBO; Moist exposed burn ointment; Regenerative therapy; Pressure ulcers; Chronic wounds; Healing index

## KEY MESSAGE

Regenerative therapy using MEBO dressings three times daily significantly promotes healing of chronic pressure ulcers irrespective of their size, site, grade or underlying predisposing factor, with significant increase in healing index as early as 2 weeks of initiation of therapy reflected by a significant reduction of ulcer size.

## INTRODUCTION

Pressure ulcers constitute a clinical challenge for both clinician and patient [1-3]. The clinical evidence that a moist environment is the single most important external factor responsible for optimal wound healing is overwhelming [4-7]. Moist Exposed Burn Ointment (MEBO) (ShanTou MEBO Pharmaceutical CO, LTD, China), popularized by Xu Rong-xiang has shown evidence over the past 30 years of promoting wound healing both in the experimental and clinical setting, albeit without many properly conducted randomized controlled trials (RCTs) [8-17]. This RCT was conducted to assess the safety and efficacy of regenerative

\*Corresponding author: Mahmoud F. Sakr, Department of Surgery, Faculty of Medicine, Alexandria University, Alexandria, Egypt, Tel: 002 0100 7834993; E-mail: mah\_sakr@yahoo.com

Received date: September 16, 2019; Accepted date: September 25, 2019; Published date: September 30, 2019

Citation: Sakr MF, Hamed MH, Chong YC (2019) A Controlled Randomized Trial Assessing Regenerative Therapy in Healing of Chronic Pressure Ulcers. J Surg Anesth 3:1. doi: 10.35248/2684-1606.19.3.124

Copyright: © 2019 Sakr MF, et al. This is an open-access article distributed under the terms of the Creative Commons Attribution License, which permits unrestricted use, distribution, and reproduction in any medium, provided the original author and source are credited.

Sakr MF, et al.

therapy in local wound care and healing of chronic pressure ulcers (CPUs).

## SUBJECTS AND METHODS

### Study design

The present study was designed as a single-blind, prospective, clinical RCT in Egypt, Kuwait and China using the same protocol, which was approved by the Ethics Committee of the corresponding hospitals. Patients were randomly assigned to receive local treatment with MEBO dressing or saline solution (wet-to-moist dressing), and were blinded as to the type of dressing to be used. Randomization was performed in the outpatient department according to a computer-generated schedule with individual assignments concealed in sequentially numbered closed envelopes that were opened in order when assignments were made.

### Study population

As shown in Figure 1, all consecutive patients with pressure ulcers (n=143) were assessed for eligibility. Sixteen patients were excluded (ulcers <3 months, n=9; refusal of participating in the study, n=7). The remaining 127 patients with CPUs (of 3-month duration or more) were enrolled in the study after obtaining an informed written consent from the patient or a first-degree relative. However, 13 patients were lost during follow-up and 9 completed treatment elsewhere.

The remaining 105 patients (with 218 ulcers) who completed the study and were analyzed represent the study population of this RCT. They were randomized for treatment with MEBO dressing (Group 1, n=55 with 115 ulcers) or saline solution dressing (Group 2 controls, n=50 with 103 ulcers). There were 61 males (58.1%) and 44 females (41.9%). Their ages ranged between 14-102 years with a mean of  $59 \pm 14.7$  years. Patients had their ulcers prior to study entry for a mean of 9.67 months (range 3-21 months).

### Data collection

All data was collected prospectively and included demographics (age and gender), nutritional status, underlying predisposing disease and/or co-morbidities such as diabetes mellitus, peripheral vascular disease, renal insufficiency, malignancy, central nervous system, spinal cord or peripheral nerve injuries, endocrinopathy, and chronic osteomyelitis. Previous irradiation, and concomitant corticosteroids or chemotherapy administration were noted.

Laboratory investigations for all patients included complete blood count, liver function tests, renal function tests (blood urea and creatinine), and serum electrolytes. Plain X-ray and other appropriate imaging studies were conducted as indicated. Ulcer characteristics included number, type, duration, size, site, sepsis, and CPU stage as adopted by the panel developing the pressure ulcer treatment guideline for the AHCPR in 1994 [18]. Clinical outcome was documented and adverse effects or hypersensitivity reactions to the local dressing used, if any, were recorded.

### Management protocol

**Clinical evaluation:** At presentation, the site of the wound was noted, and a photograph with a digital camera was taken. After adequate debridement of all necrotic tissues if any, the surface area (SA) of each ulcer was measured using a wound-mapping chart (3M Health Care, Loughborough, UK). The floor of the ulcer regarding its depth, granulation tissue and sepsis; as well as the margin status with respect to edema, erythema, cellulitis and hyper-pigmentation were all recorded. The wound was considered infected if a purulent discharge was present with two the presence of infection and suggestive radiological features indicated the presence of osteomyelitis [20].

**Systemic treatment:** Whenever indicated, anti-infective treatment and nutritional support were started simultaneously with local wound care. Amino acids, lipids, plasma, and albumin were infused to improve the nutritional status of the patient. Effective antibiotics were chosen according to the wound status and the results of drug sensitivity tests. In patients with diabetes mellitus, blood glucose level was controlled within the normal range (fasting blood glucose below 7.1 mmol/L or HbA1c below 7%).

**Local wound management:** Surgical debridement was performed when indicated to remove all necrotic tissue as possible. The wound and the circumjacent skin were cleansed with sterile saline solution.

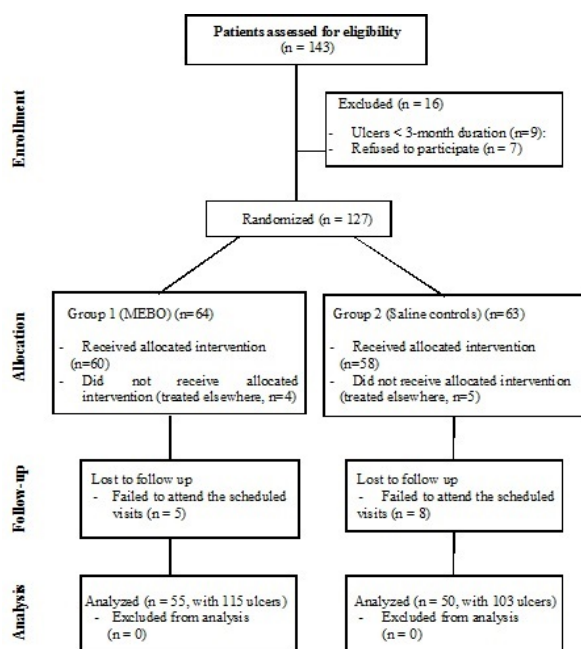


Figure 1: Patient flow diagram.

Sakr MF, et al.

A 2-mm-thick layer of MEBO and MEBO dressing, at 8 hourly intervals, was applied after the residual saline was absorbed out with sterile gauze and after gently removing the previously applied layer. Swabs for culture were taken only whenever it was clinically indicated. Wound dressing change was carried out in a standardized procedure following the “three timely principles” i.e. timely removal of liquefied products, timely removal of necrotic tissue and timely application of MEBO, as well as the “three NO principles” i.e. no pain, no bleeding and no further injury to viable tissue [21]. Patients in the control groups received saline dressings applying the “wet-to-moist” technique.

### Follow-up and assessment of clinical outcome

Patients were followed-up at two-week intervals for 12 weeks or earlier if the wound had healed completely. Upon each visit, the wound was evaluated, photographs were taken, SA measured, healing index (HI) calculated, and time needed for complete healing (cure) recorded. The HI was calculated by dividing the difference in wound size between “day 0” (initial day of assessment) and any given “day x” by wound size at “day 0” i.e.  $HI = (\text{wound size day 0} - \text{wound size day x}) / \text{wound size day 0}$ . Accordingly, HI ranges between 0-1, where 0 means no healing and 1 means complete healing, irrespective of wound size. The outcome of treatment was evaluated by the HI at 12 weeks after initiation of therapy as follows:

Healing (cure): Wounds healed completely and covered with epidermis i.e.  $HI = 1$

Effective: Reduction of SA by 50% or more i.e.  $HI > 0.5$  and new grown granulation tissue with less local effusion, and actively growing epidermis at the edges of the wound.

Cure rate and effectiveness add up to “total effective rate”.

Ineffective:  $HI < 0.5$  and slowly growing granulation tissue and epidermis on the wound edge, or no new grown granulation tissue.

**Table 1:** Clinical and biochemical features of patients in both studied groups.

### Statistical analysis

The target sample size was a minimum of 50 patients, which an initial power calculation suggested would be required to detect a 20% change in HI with a power of 80%, at the 5% significance level. Data were analyzed using the Statistical Package for Social Sciences Version 20 software (SPSS Inc, Prentice-Hall, Chicago, IL, USA). Continuous variables were expressed as mean values  $\pm$  standard of deviation ( $X \pm SD$ ) and were compared using the student's t test.

Variables of HI and SA over time were expressed as mean values  $\pm$  standard error of the mean ( $X \pm SEM$ ). Differences in ulcer SA between the 2 groups were compared using a non-parametric test (Mann-Whitney's) due to wide range, while proportions were compared using the Chi-square test ( $X^2$ ) or the Fisher Exact Probability Test when the expected cell frequencies were smaller than 5. Probability value of  $< 0.05$  was considered to be statistically significant. A linear regression analysis calculating  $r^2$  values was performed to indicate that the change in SA and HI can be attributed to dressing application. Values of  $r^2 > 0.4$  indicate that the 2 parameters are in correlation with each other whereas values  $< 0.4$  indicate that other variables may have contributed to the observed changes in ulcer size.

### RESULTS

Patients in both groups had similar demographic (age and gender), clinical (underlying predisposing factor and associated medical conditions) and biochemical (anemia and hypo-albuminemia) features. Cerebro-Vascular Accident (CVA) was the most common predisposing factor, and diabetes mellitus and hypertension were the most common co-morbidities, in both groups (Table 1). Ulcer characteristics were also similar with respect to their number, duration, site, size, depth and presence or absence of sepsis (Table 2). In both groups, the number of ulcers per patient ranged between one and four; the trochanteric region was the most common ulcer site, and stage 2 ulcers were the most common at the time of presentation. Four patients died in each group after 7-16 months of their enrollment in the study, which did not affect the data gathered regarding healing of their pressure ulcers.

Clinical features	Group 1 (MEBO), n=55	Group 2 (Saline), n=50
Age (years)	67 $\pm$ 8.5	73 $\pm$ 9.2
Mean $\pm$ SD	14-102	25-95
Range		

Gender	32(58.2 %)	29(58.0 %)
Male	23(41.8 %)	21(42.0 %)
Female		
Predisposing factor	42(76.4 %)	35(70.0 %)
Old CVA	7(12.7 %)	11(22.0 %)
Paraplegia	6(10.9 %)	4(8.0 %)
Cerebral palsy		
Co-morbidities	22(40.0 %)	23(46.0 %)
DM	11(20.0%)	8(16.0 %)
Hypertension	7(12.7 %)	7(14.0 %)
DM+Hypertension	6(10.9 %)	7(14.0 %)
Renal failure	6(10.9 %)	3(6.0 %)
Cardiac Disease (LVF)	3(5.5 %)	2(4.0 %)
Malignancy		
Laboratory results	10.3 ± 1.1	10.3 ± 1.1
Hemoglobin (g/dl)	31 ± 4.3	31 ± 4.3
Albumin (g/dl)		
Vital status	51(92.7 %)	46(92.0 %)
Survival	4(7.3 %)	4(8.0 %)
Death		

All differences were not statistically significant (p>0.05).

**Abbreviations:** CVA: Cerebro-Vascular Accident; DM: Diabetes Mellitus; LVF: Left Ventricular Failure

**Table 2:** Ulcer characteristics of patients in both studied groups.

Ulcer characteristics	Group 1 Ulcers (MEBO) (n=115)	Group 2 Ulcers (Saline) (n=103)
No. of ulcers/patient	20 (36.4 %)	22 (44.0 %)
One ulcer	35 (63.6 %)	28 (56.0 %)
>one ulcer		
Duration prior to entry (months)	8.86 ± 6.9	11.57 ± 7.57
Mean ± SD	3-20	3-21
Range		
Ulcer site	59 (51.3 %)	60 (58.2 %)
Trochanteric	43 (37.4 %)	29 (28.2 %)
Sacral	7 (6.1 %)	10 (9.7 %)
Heel	6 (5.2 %)	4 (3.9%)
Shoulder		
Ulcer size (cm <sup>2</sup> ) *	19.5 ± 12.5	21.5 ± 13.4

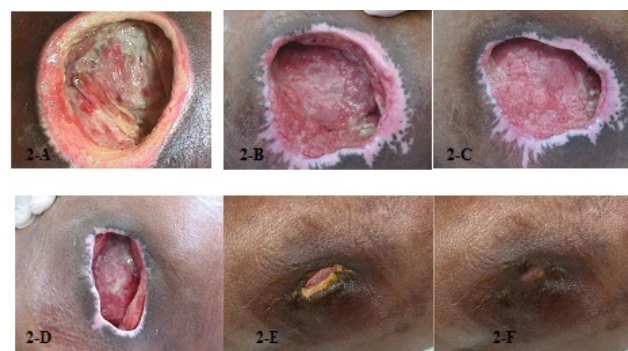Mean ± SE	0.5 – 99.1	7.26 – 61.65
Range		
Stage of the ulcer	26 (22.6 %)	18 (17.5 %)
Stage 1	50 (43.5 %)	44 (42.7 %)
Stage 2	28 (24.3 %)	26 (25.2 %)
Stage 3	11 (9.6 %)	15 (14.6 %)
Stage 4		
Sepsis upon entry	39 (44.9.0 %)	20 (20.1 %)
Positive	76 (55.1 %)	83 (79.9 %)
Negative		

\*Due to wide range; a non-parametric test (Mann-Whitney's) was used ( $p=0.06$ )

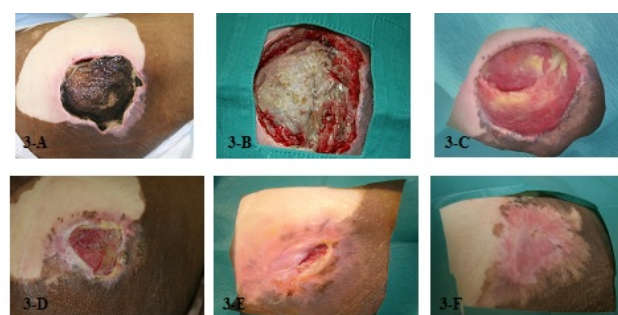All differences were not statistically significant ( $p>0.05$ )

Figures 2-5 show the progressive healing of deep (stage 4) trochanteric and sacral CPUs treated with MEBO. There was a significant ( $p<0.05$ ) increase in healing index (HI) (Figure 6) and reduction in ulcer surface area (SA) (Figure 7) on weeks two and four respectively, that was maintained through 12 weeks in patients receiving MEBO as compared to those receiving saline solution. Cumulative patient sample percentage showed that 61.7% (71/115) of ulcers treated with MEBO had complete healing ( $HI=1$ ) by 12 weeks, as opposed to only 28.2% (29/103) of those treated with saline ( $X^2=24.68$ ,  $p=0.000$ ).

Moreover, none of the patients receiving MEBO had a HI of  $<50\%$  by 12 weeks as compared to 28.2% (29/103) of those receiving saline ( $X^2=34.09$ ,  $p=0.000$ ) (Figure 8). As seen in Figure 9, the higher the CPU grade (stage) at presentation, the less likely it was for that ulcer to heal within the study period irrespective of treatment received. All grade-1 ulcers in patients belonging to both groups healed completely by 12 weeks. More than one-fourth (27.3%, 3/11) of grade 4 ulcers in the MEBO group healed completely by 12 weeks as opposed to none (0/15) in the saline group. Moreover, significantly more grade 2 and 3 ulcers healed completely with MEBO by 12 weeks ( $X^2=18.05$ ,  $p=0.000$ , and  $X^2=6.12$ ,  $p=0.0133$ ), respectively). Linear regression analysis showed that the change in ulcer size and healing index can be attributed to local dressing application ( $r^2>0.4$ ). No adverse effects or hypersensitivity reactions were encountered in either group.

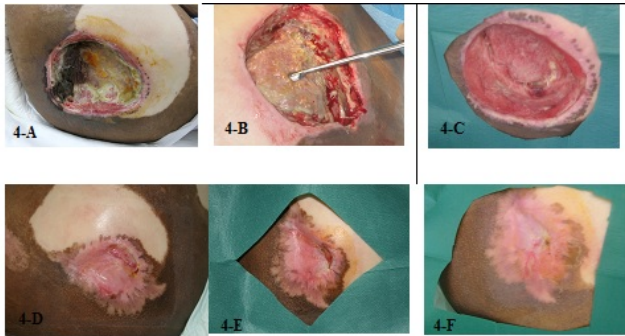


**Figure 2 (A-F):** A stage-4 right trochanteric pressure ulcer in treated with MEBO showing progressive healing; A: On admission, B: 4 weeks post-treatment, C: At 6 weeks, D: At 8 weeks, E: At 10 weeks, and F: At 12 weeks.

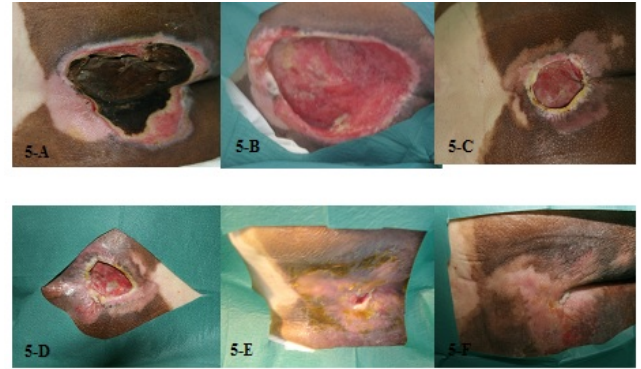


**Figure 3 (A-F):** A stage-4 right trochanteric pressure ulcer treated with MEBO and showing progressive healing; A: On admission, B: 4 weeks post-treatment, C: At 6 weeks, D: At 8 weeks, E: At 10 weeks, and F: At 12 weeks (complete ulcer healing).

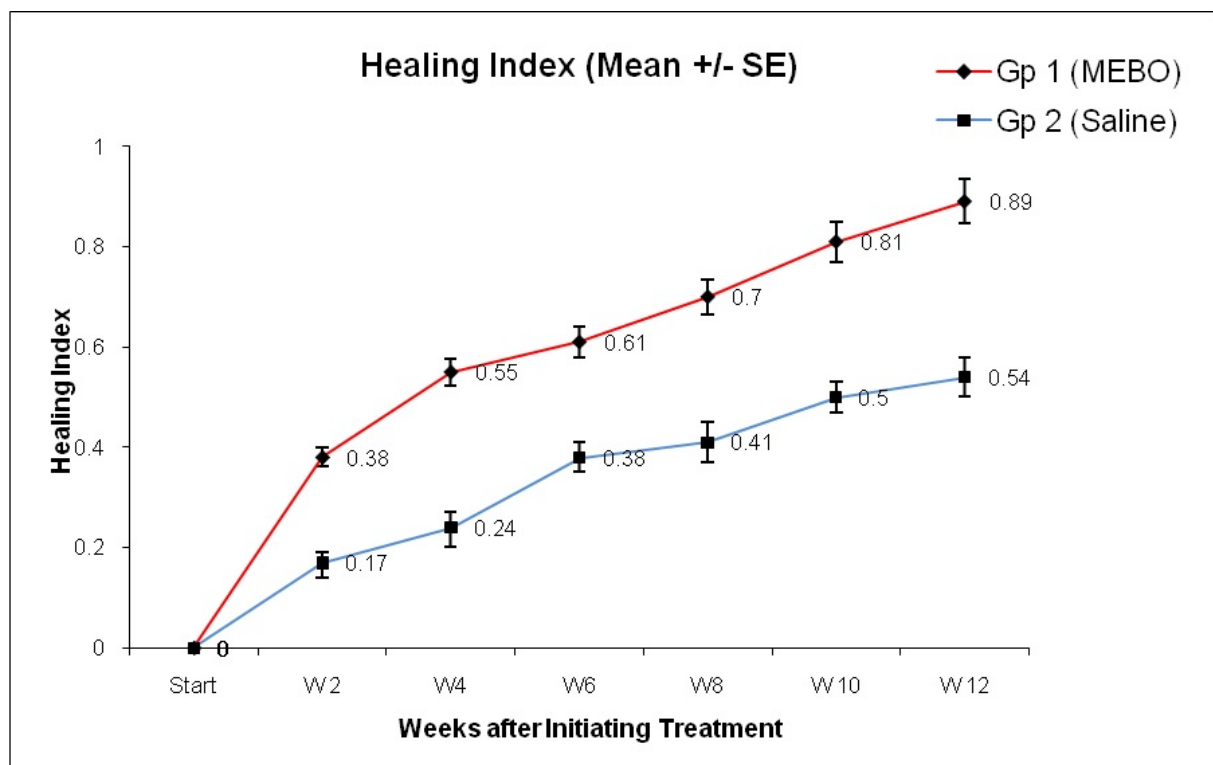




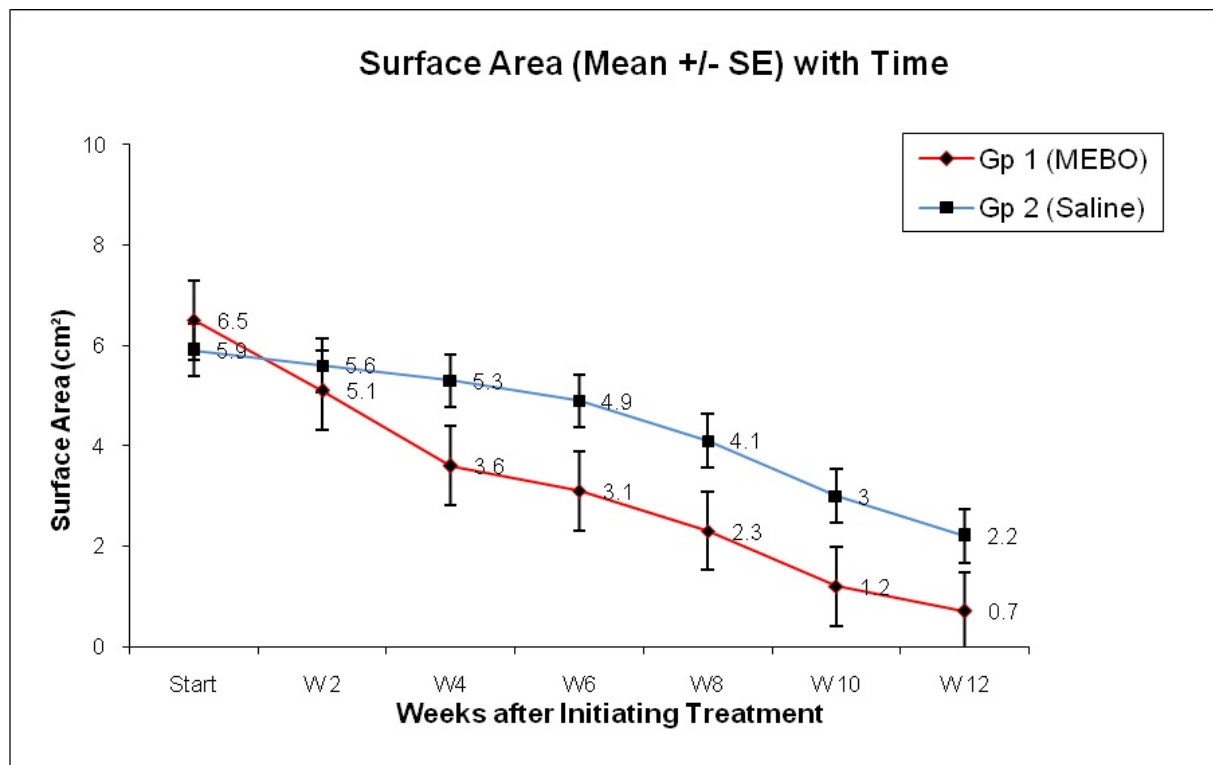
**Figure 4 (A-F):** A stage-4 left trochanteric pressure ulcer treated with MEBO and showing progressive healing; A: On admission, B: 4 weeks post-treatment, C: At 6 weeks, D: At 8 weeks, E: At 10 weeks, and F: At 12 weeks (complete ulcer healing).



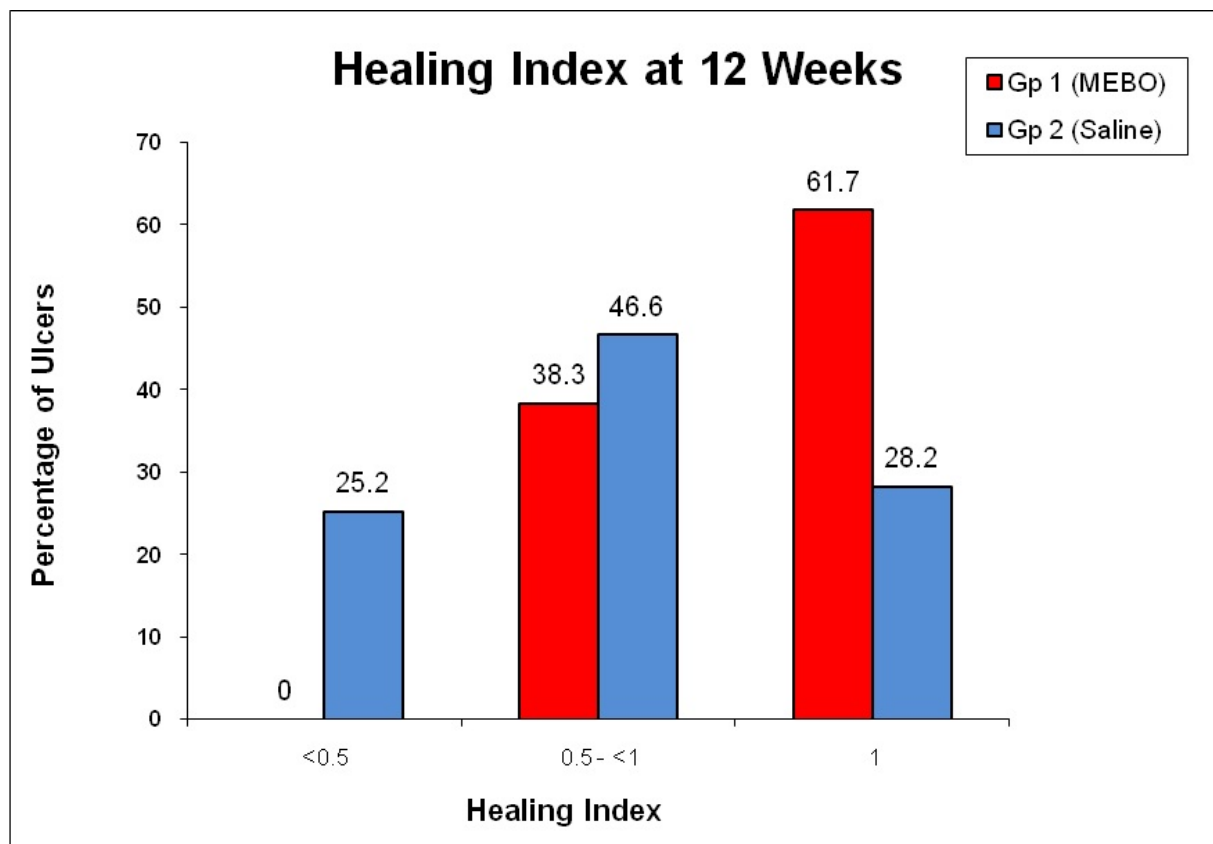
**Figure 5(A-F):** A stage-4 sacral pressure ulcer treated with MEBO and showing progressive healing; A: On admission, B: 4 weeks post-treatment, C: At 6 weeks, D: At 8 weeks, E: At 10 weeks, and F: At 12 weeks (complete ulcer healing).



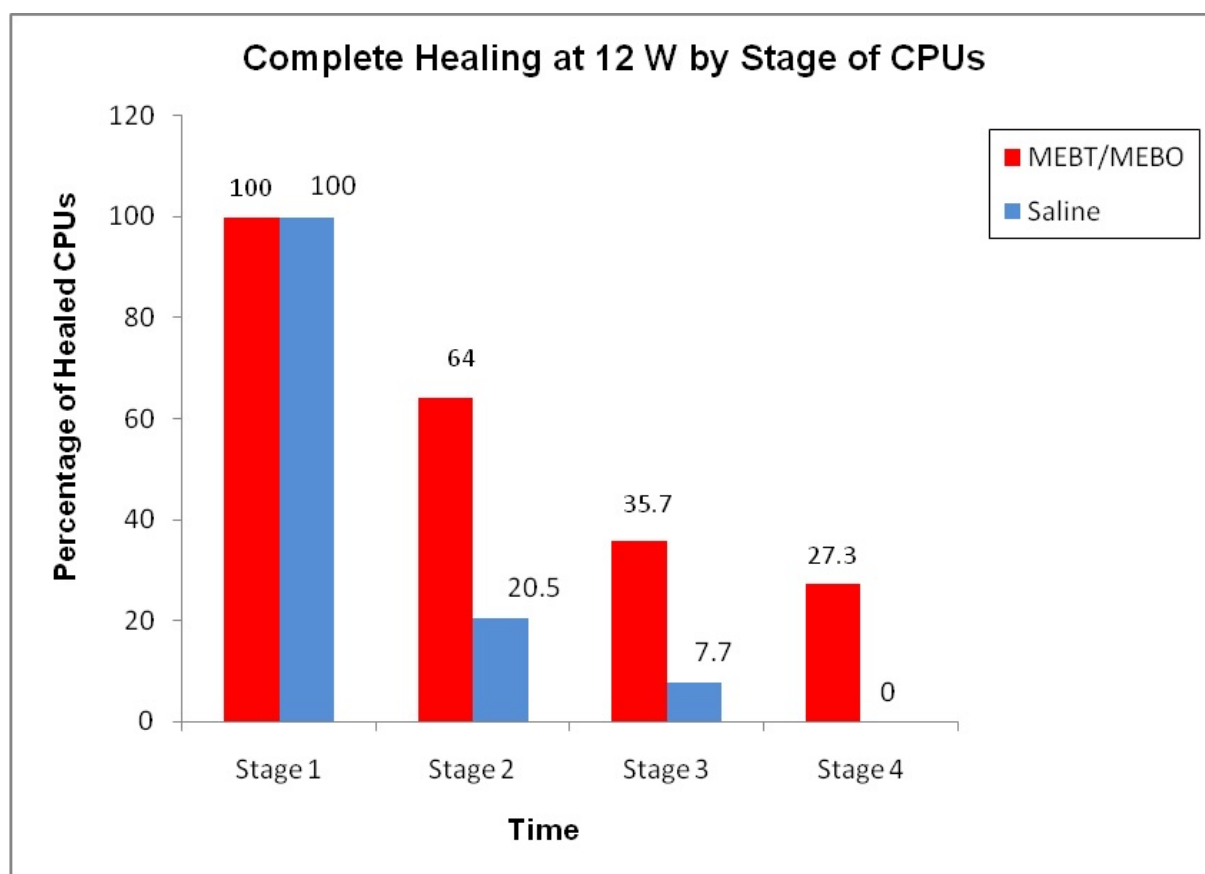
**Figure 6:** Healing Index (HI) of pressure ulcers in both groups with time showing significant increase of HI in patients receiving MEBO starting at 2 weeks after initiation of therapy.



**Figure 7:** Surface area (SA) of pressure ulcers in both groups with time showing significant reduction of ulcer size in patients receiving MEBO starting at 4 week after initiation of therapy.



**Figure 8:** Healing Index (HI) of pressure ulcers in both groups at 12 week after initiation of treatment; note complete healing of >60% of pressure ulcers in patients receiving MEBO/MEBT.



**Figure 9:** Complete healing (HI=1) of pressure ulcers, according to stage (grade), in both groups at 12 week after initiation of treatment. Note complete healing of >25% of stage-4 pressure ulcers in patients receiving MEBO/MEBT.

## DISCUSSION

Chronic Pressure Ulcers (CPUs) greatly affect the lives of patients and their family caregivers regarding their physical, emotional, social and financial status; change of body image; and loss of independence and control [22]. They are caused by unrelieved pressure that results in damage of underlying tissues, most commonly in old, bed-ridden and paralyzed patients. Necrotic tissues provide a favorable environment for bacterial invasion and infection, which aggravates the ischemia and tissue hypoxia, finally leading to the development of “hard-to-heal” ulcers. If left untreated for a long time, CPUs would result in septicemia or other organ failure. Therefore, treating such ulcers means not only improving the patient’s quality of life, but also saving life itself.

Pharmaceutical preparations used in wound management include wound cleansing solutions, anti-microbial and wound debriding agents as well as dressing materials and products. The rapid development of topical wound dressings during the last 3 decades has left the physician with a confusing number of choices ranging from exotic products such as egg membranes and banana leaves to hi-tech engineered biomaterials [23]. There is strong evidence in the literature that a moist environment is the single most important external factor responsible for optimal wound healing as it facilitates keratinocyte migration, angiogenesis and interaction with growth factors [3,5,23,24]. Therefore, any dressing that does not provide the necessary moisture for wound healing should be disregarded except

probably when dealing with infected wounds in which the moist environment would exacerbate the infection [24]. Currently, more than 70 different brands of moisture retentive occlusive and semi-occlusive dressings are marketed [25]. Such dressings prevent surface desiccation, enhance re-epithelization and wound contraction, and also reduce pain during the healing phase [26]. However, early occlusive dressings were quickly abandoned because of the potential of bacterial proliferation and their difficulty of application in areas other than the extremities [27,28]. Further, when occlusive dressings are used on large surface areas, the amount of dressing exudate becomes unmanageable and it becomes cost ineffective and labor intensive [29].

MEBO is the basis of MEBT (moist environment burn therapy) popularized 3 decades ago by Xu Rongxiang of the Beijing Burn Center in China, and supposedly represents a revolution in the management of burns by encouraging the burn wound to heal and regenerate spontaneously without surgical intervention [8]. Many clinical studies over the last 30 years proved that the standard application of MEBO in the treatment of all kinds of open wounds, including CPUs, in combination with comprehensive systemic treatment can achieve regenerative healing *in situ* [14,30-32]. The exact mechanism of action of MEBT/MEBO has not been fully elucidated, but it is conceivable that this oil-based ointment provides a moist environment for epithelial regeneration to occur with the added anti-inflammatory effects of beta-sitosterol and anti-microbial



effects of berberine[24]. MEBO has been shown to have the ability to isolate necrotic tissue from viable and vital tissues [33,34], liquefy and discharge the necrotic tissues completely through a series of biochemical reactions such as hydrolysis, enzymolysis, rancidity, saponification, and estrification, and consequently show the healthy pink granulation tissue within 7-10 days of treatment [35]. Meanwhile, MEBO activates Potential Regenerative Cells (PRCs) at the deep wound to transform into K-19 stem cells, so as to promote regenerative repair of new skin tissue *in situ*. It also provides the appropriate moist environment and nutritional substances necessary for neocapillary formation and nerve fiber regeneration. Moreover, MEBO ingredients allow it to be effective through the three stages of wound healing by providing rapid autolytic debridement (first stage), facilitating the development of healthy granulation tissue (second stage) and facilitating re-epithelization with no hypo- or hyper-pigmentation (third stage), thus effectively preventing the formation of pathological scars [36,37].

In the present randomized clinical study, patients in the two groups differed only in the type of local wound dressing applied in order to assess the role of MEBO in promoting healing as compared to controls using the saline wet-to-moist technique. Results showed the simplicity, safety and efficacy of MEBO in local management of CPUs irrespective of their size or underlying etiology. Significant increase in HI of any given ulcer, as compared to saline controls, is to be expected as early as two week following initiation of therapy [24]. By 12 week post-treatment, more than 60% of ulcers treated with MEBO were cured (HI=1), and the remaining ulcers showed "effective" healing" (HI=0.5-1), thus yielding a "total effective rate" of 100%. In accordance with our results, Jin-li and Wen-le reported a curative rate of 100% of their series of 58 patients with 79 bed sores (pressure ulcers) under standard treatment with MEBO [38]. Guang-shun et al randomized 120 patients with 163 deep pressure ulcers (stage 3) and reported a cure rate of 80% and total effective rate of 93.3% in the MEBO group as compared to 46.6% and 63.3% respectively in controls [39]. More recently (2017), Li Wei et al who randomized 72 patients with grades 3 and 4 CPUs reported that ulcers in 50.0% of patients in the MEBO group as compared to only 16.7% of those in the placebo group, completely healed after 2 months of treatment ( $p<0.05$ ). Similar superior results of MEBO were previously reported by several authors in the management of various open wounds including CPUs, diabetic foot ulcers, burns, skin graft donor sites, wounds caused by laser surgery, skin traumatic wounds, and lower limb varicose ulcers [13,14,31,40-51].

A relatively new concept in local wound management applicable to CPUs is the negative-pressure wound therapy (NPWT), which has been claimed to increase oxygen tension in the wound, decrease bacterial count and enhance granulation formation. Additional advantages include diminished need for daily dressing changes and probably reduced cost [52]. Though the principle is basically simple, applying this type of dressing does require certain expertise and may not be applicable to all types of wounds, such as those with inadequate circulation, fibrotic, desiccated and devitalized wounds with eschar, in addition to wounds that are too small to allow the NPWT foam dressing to come into contact with the wound bed [53].

## CONCLUSION

Based on the data presented, it may be concluded that MEBO dressing can be applied with simplicity and safety, MEBO/MEBT significantly promotes healing of any given wound irrespective of its size, site, cause, or stage, with significant increase in the HI starting two week after initiation of treatment, reflected by significant reduction of SA at four week, and with the use of MEBO, complete healing (cure) of over 60% of CPUs is achieved by 12 week with a total effectiveness of 100%. Other comparative studies between this topical treatment modality (MEBT/MEBO) of CPUs and other existing practices merit further investigation.

## REFERENCES

1. Cuddigan J, Ayello EA, Sussman C. Pressure Ulcers in America: Prevalence, Incidence and Implications for the Future. An executive summary of the National Pressure Ulcer Advisory Panel monograph. *Adv Skin Wound Care*. 2001; 14 (4): 208-15.
2. Robson MC. Wound infection: A failure of wound healing caused by an imbalance of bacteria. *Surg Clin North Am*. 1997; 77: 637-50.
3. Atiyeh BS, Ioannovich J, Al-Amm CA, Al-Musa KA. Management of acute and chronic wounds: The importance of moist environment in optimal wound healing. *Current Pharmaceutical Biotechnology*. 2002; 3: 179-96.
4. Svensjo T, Pomahac B, Yao F, Slama J, Erikson E. Accelerated healing of full thickness skin wounds in a wet environment. *Plast Reconstr Surg*. 2000; 106: 602-12.
5. Al-Musa KA, Sawwaf A, Dham R. Scar quality and physiologic barrier function restoration following moist and moist exposed dressings of partial thickness wounds. *Dermatologic Surg*. 2003; 29: 14-20.
6. Atiyeh BS, Al-Amm CA, Nasser AA. Improved healing of split thickness skin graft donor sites. *J Applied Research*. 2002; 2: 114-21.
7. Atiyeh BS, Al-Amm CA, Al-Musa KA, Sawwaf A, Dham R. The effect of moist and moist exposed dressings on healing and barrier function restoration of partial thickness wounds. *Dermatologic Surg*. 2003; 29: 14-20.
8. Xu R. The medicine of burns and ulcers: A general introduction. *Chinese J Burns Wounds Surf Ulcers*. 1989; 1: 68.
9. Geng XL, Bu XC, Gao FQ, Liu YL. Study on the bacterial count of variable tissue of burn wound. *Chinese J Burns Wounds Surf Ulcers*. 1989; 1: 49-50.
10. Huang QS, Zhou G, Su BP, Huang EX. A comparative study of fibronectin and MEBO in the treatment of experimental rabbit corneal alkaline burn. *Chinese J Burns Wounds Surf Ulcers*. 1995; 7: 18-27.
11. Erikson E, Perez N, Slama J, Page CP, Andree C, Maguire JH. Treatment of chronic, non-healing abdominal wound in a liquid environment. *Ann Plast Surg*. 1996; 36: 80-3.
12. Wang GS, Jian WG, Xu XS, Lang QX, Zhang XS, Wang KQ, et al. The exploration of pathological changes and their mechanism of experimentally burned rabbits after treatment. *Chinese J Burns Wounds Surf Ulcers*. 1992; 4: 7-11.
13. Atiyeh BS, Ghanimeh G, Kaddoura IL, Al Amm CA, Ioannovich J. Letter-to-the-editor, Split thickness skin graft donor site dressing: Preliminary results of controlled clinical comparative study of MEBO and Sofra-tulle. *Ann Plast Surg*. 2001; 46: 88-9.
14. Sakr MF, Hamed HM, Yong-chong C, Gui-ru LI, Yong Z. The multi-centers comparative study of Moist Exposed Burn Ointment

- (MEBO) in healing of chronic diabetic foot ulcers. *Chinese J Burns Wounds Surf Ulcers*. 2012; 24(2): 102-18.
15. Vickers A. Regulating complementary medicine. *BJM* 1996; 313: 881-2.
  16. Angell M, Kassirer JP. Alternative medicine: The risks of untested and unregulated remedies (editorial). *N Engl J Med*. 1998; 339: 839-41.
  17. Fontanarosa PB, Lundberg GD. Alternative medicine meets science. *JAMA*. 1998; 280: 1618-9.
  18. Bergstrom N, Bennett MA, Carlson CE. Treatment of pressure ulcers. Clinical Practice Guideline, No. 15. AHCPR Publication No. 95-0652, Rockville, MD: Agency for Health Care Policy and Research, Dec 1994.
  19. Oyibo SO, Nguyen HC, Jude EB, Harkless LB, Tarawneh I, Boulton AJM. A comparison of two diabetic foot ulcer classification systems: The Wagner and the University of Texas wound classification systems. *Diabetes Care*. 2001; 24(1): 84-8.
  20. Grayson MI, Gibbons GW, Balogh K, Levin E, Karchmer AW. Probing to bone in infected pedal ulcers: A clinical sign of underlying osteomyelitis in diabetic patients. *J Am Med Assoc*. 1995; 273: 721-3.
  21. Langemo DK, Melland H, Hanson D, Olson D, Hunter S. The lived experience of having a pressure ulcer: A qualitative analysis. *Adv Skin Wound Care*. 2000; 13: 225-35.
  22. Lavery LA, Ashry HR, Van Houtum W, Pugh JA, Harkless LB, Basu S. Variation in the incidence and proportion of diabetes-related amputation in minorities. *Diabetes Care*. 1996; 19: 48-52.
  23. Atiyeh BS, Hayek SN. An update on management of acute and chronic open wounds: The importance of moist environment in optimal wound healing. *Med Chem Rev* 2004; 1: 1-11.
  24. Gupta MB, Nath R, Srivastava N, Shanker K, Kishor K, Bhargava KP. Anti-inflammatory and antipyretic activities of beta-sitosterol. *Planta Med*. 1980; 39: 157-63.
  25. Thomas DR, Kamel HK. Wound management in postacute care. *Clin Geriatr Med*. 2000; 16: 783-804.
  26. Vogt PM, Andree C, Breuing K, Liu PY, Slama J, Helo G, et al. Dry, moist, and wet skin wound repair. *Ann Plast Surg*. 1995; 34: 493-9.
  27. Reuterving CO, Agren MS, Soderberg TA, Tengrup I, Hallmans G. The effects of occlusive dressings on inflammation and granulation tissue formation in excised wounds in rats. *Scand J Plast Reconstr Surg*. 1989; 23: 89-96.
  28. Feldman D, Rogers A, Karpinski R. A prospective trial comparing Biobrane, Duoderm, and Seroform for skin graft donor sites. *Surg Gyn Obstet*. 1991; 173: 1-5.
  29. Robson MC. Discussion: Dry, moist, and wet skin wound repair. *Ann Plast Surg*. 1995; 34: 499-500.
  30. Mo X, Xiang-dong Z, Jing W, Chi-yong W, Yong Z, Lei W, et al. Mechanism analysis of MEBO in treating diabetic skin ulcer. *Chinese J Burns Wounds Surf Ulcers*. 2012; 24(2): 81-96.
  31. Atiyeh BS, Ioannovich J, Magliacani G, Masellis M, Costagliola M, Dham R. The efficacy of moisture retentive ointment in the management of cutaneous wounds and ulcers: A multicenter clinical trial. *Indian J Plast Surg*. 2003; 36: 89-98.
  32. Mostow EN. Wound healing: A multidisciplinary approach for dermatologists. *Dermatol Clin*. 2003; 21: 371-6.
  33. Yu HH, Kim KJ, Cha JD, Kim HK, Lee YE, Choi NY, et al. Antimicrobial activity of berberine alone and in combination with ampicillin or oxacillin against methicillin-resistant staphylococcus aureus. *J Med Food*. 2005; 40: 454-61.
  34. Xu Rong-xiang. *The Secret of Skin Regeneration*. Beijing: Jiuzhou Pressing House, 2011: 37.
  35. XU Rong-xiang. *Clinical Handbook of Burns Regenerative Medicine and Therapy*. Beijing, Chinese Medical Science and Technology Press, 2000: 64.
  36. Mo X. Histological observation of MEBO in promoting the regenerative restoration of deep burn wounds. *Chinese J Burns Wounds Surf Ulcers*. 1999; 11(3): 8-13.
  37. Atiyeh BS, Ioannovich J, Al-Amm CA, Al-Musa KA, Dham R. Improving scar quality: A prospective clinical study. *Aesth Plast Surg*. 2002; 26: 470-6.
  38. Jin-li S, Wen-le Y. Clinical efficacy and nursing care of MEBO in the treatment of elderly patient with diabetic bedsore. *Chinese J Burns Wounds Surf Ulcers*. 2009; 21(3): 27.
  39. Guang-shun W, Yong-chong C, Cheng-chun LI. Discussion on effects of potential regenerative cells combined with regenerative therapy in treating phase III bedsores. The 11th Chinese Burns Wounds and Ulcers Conference.
  40. Wei L, Yubo M, Qi Y, Yu P, Qinggang M. Moist exposed burn ointment for treating pressure ulcers: A multicenter randomized controlled trial *Medicine*. 2017; 96: 29.
  41. Sakr M, Xiang-ning W, Zi-jun F, Hamed H, El-Torky H. Assessment of regenerative therapy (MEBO) in healing of various open wounds: A multicentre controlled randomized trial. *Chinese J Burns, wounds and Surf Ulcers*. 2013; 25(3): 211-29.
  42. Xiang W, Min S, De-huai W. An analysis of 54 cases of diabetic lower limb ulcers. *Chinese J Burns, Wounds Surf Ulcers*. 2003; 15(3): 216-19.
  43. Qing-hua LI, Xia L, Pei-xin G. Clinical effect of MEBO in the treatment of skin ulcers in elderly diabetic patients. *Chinese J Burns Wounds Surf Ulcers*. 2008; 20 (4): 305-7.
  44. Shi-tao C, Bing XU, Kui GE. Clinical effect of MEBO in treating diabetic ulcers on lower extremities. *Chinese J Burns Wounds Surf Ulcers*. 2008; 20 (3): 217-21.
  45. Min-xin G, Li-ming M, Zuo-hua Z, Hong-xia L. Clinical analysis of using MEBO in treating 13 cases of diabetic foot ulcers. *Chinese J Burns Wounds. Surf Ulcers* 2000; 12 (4): 114-9
  46. Sakr M, Hamed H. Lower limb salvage using regenerative therapy in patients with diabetic foot ulcers: A controlled randomized study. *Ann Surg Int*. 2016; 2(5): 1-14.
  47. Sabry H, Saber H, Gomaa R, Labib I, Farid S, Kholousy H, et al. Assessment of MEBO in healing of burns in children up to 5 years. *Chinese J Burns Wounds Surf Ulcers*. 2017; 29(4): 229-41.
  48. Yong-heng D, Bin H, Li-ping X. Clinical effect observation of MEBO wound and ulcer dressing combined with MEBO in treating donate site wound. *Chinese J Burns Wounds Surf Ulcers*. 2009; 21 (1): 9-15.
  49. Sheng H, Hao Z, Xiao W. Effect of MEBO wound and ulcer dressing on the wound caused by laser surgery on naevus flammeus site. *Chinese J Burns Wounds Surf Ulcers* 2008; 20 (3): 206-9.
  50. Shou-wan C. Effect of MEBO wound and ulcer dressing on skin injury wounds. *Chinese J Burns Wounds Surf Ulcers*. 2008; 20 (4): 328-9.
  51. Hui J. MEBO wound and ulcer dressing combining with minimally invasive point-like vein stripping technique to treat lower limb varicose ulcer. *Chinese J Burns Wounds Surf Ulcers*. 2010; 22 (3): 33-6.
  52. Argenta LC, Morkwas MJ. Vacuum-assisted closure: A new method for wound control and treatment: Clinical experience. *Ann Plast Surg*. 1997; 38: 563-76.
  53. Subhas G. Guidelines for managing pressure ulcers with negative pressure wound therapy. *Adv Skin Wound Care*. 2004; 17 (Suppl 2): 1-16.