

# A Comparative Study between Pre-Natal and Post-Natal Screening Ultrasound in Detection of Renal Anomalies in Neonates with Isolated Minor Ear Anomalies

Khalil Mohamad Salameh\*, Shaimaa Abdelhassib Abdelrafeh Fadl, Sanaa Sayed Hussein Ahmed Badr, Hussein A Kamel and Lina H Habboub

Hamad Medical Corporation, Doha, Qatar

## Abstract

**Aim:** To assess the usefulness of postnatal renal ultrasound in newborns with isolated external ear anomalies in the presence of a normal renal ultrasound on the routine surveillance prenatal ultrasound.

**Study design:** 80 consecutive patients with isolated minor ear anomalies were collected retrospectively starting from December 2008 till February 2011; the prevalence of renal anomalies detected in postnatal ultrasound in those patients was compared with that detected in prenatal ultrasound.

**Results:** Our study included only 64 patients with isolated minor ear anomalies who have prenatal and postnatal ultrasound while 16 patients were excluded (14 patients with no recorded data regarding the prenatal ultrasound, one patient with associated imperforate anus and another patient with unilateral undescended testes). Out of the 64 patients, only one patient was reported to have unilateral pyelactasis in prenatal ultrasound but was reported to be normal on postnatal ultrasound. Otherwise all prenatal renal ultrasound findings were normal on both the prenatal and postnatal renal ultrasound findings.

**Conclusion:** There is no difference in the detection of renal anomalies between postnatal renal ultrasound in infants with isolated minor ear anomalies compared with that found on routine prenatal ultrasound.

**Keywords:** Renal ultrasound; Neonates; Minor ear anomalies

## Introduction

Isolated minor external ear malformation is relatively common congenital anomaly ranging from 5-10 per 1000 live birth [1-4]. The association between isolated minor ear anomalies and renal anomalies are not thoroughly investigated; moreover there is a general consensus that isolated minor ear anomalies are associated with higher incidence of renal anomalies [4].

In our institution all patients with isolated minor ear anomalies are screened for renal anomalies by postnatal renal ultrasound within the first 3 months in life. Since most of these infants had been examined prenatally by ultrasound scan during second and third trimesters and no renal anomalies were documented, the purpose of our study is to see if there is any difference in detection of renal anomalies in postnatal renal ultrasound in those patients compared with that found in the routine prenatal renal ultrasound.

## Materials and Methods

80 consecutive patients with isolated minor ear anomalies who presented to our Radiology Department for postnatal renal ultrasound were collected retrospectively starting from December 2008 till February 2011; Waived informed consent was used and approval of the medical research center at our institution was obtained.

Demographic data analysis and birth register details of the included neonates is demonstrated in Table 1. Any infant with no available prenatal renal ultrasound was excluded. Any infant with any other congenital anomalies was also excluded.

The isolated minor ear anomalies considered in our study was Pre-auricular skin tag, pit, accessory auricular, appendage, ear pinna deformity and dysplasia of the ear lobule. The renal anomalies considered in the study was renal agenesis or hypoplasia, crossed fused

ectopia, horse shoe, pelvic or cystic kidney, hydronephrosis as well as abnormalities that involve the renal cortex.

Comparison of the postnatal renal ultrasound findings with the routine prenatal ultrasound findings was performed. The main target was to find any difference in the detection of renal anomalies between postnatal renal ultrasound in those infants compared with that found on routine prenatal ultrasound, at the same time to find association between isolated minor ear anomalies and congenital renal abnormalities.

Characteristics	Frequency (%) Mean $\pm$ SD	Median (Range)
Baby birth weight (kg)	3.16 $\pm$ 0.58	3.2 (1.8-4.4)
Baby length (cm)	50.7 $\pm$ 2.47	51.0 (43-56)
Post natal ultrasound timing (weeks)	3.58 $\pm$ 1.80	3.0 (0.15-10)
Mother age (years)	30.07 $\pm$ 5.4	30 (17-40)
Baby gender		
Male	49 (61.3)	
Female	31 (38.7)	
Nationality		
Qatari	23 (28.8)	
Non-Qatari	57 (71.2)	

**Table 1:** Baseline demographic and clinical characteristics (N=80).

**\*Corresponding author:** Khalil Mohamad Salameh, Hamad Medical Corporation, Doha, Qatar, Tel: 0097440114258; E-mail: [ksalameh@hamad.qa](mailto:ksalameh@hamad.qa)

**Received** December 07, 2016; **Accepted** December 27, 2016; **Published** December 31, 2016

**Citation:** Salameh KM, Fadl SAA, Badr SSHA, Kamel HA, Habboub LH (2016) A Comparative Study between Pre-Natal and Post-Natal Screening Ultrasound in Detection of Renal Anomalies in Neonates with Isolated Minor Ear Anomalies. J Neonatal Biol 5: 242. doi:10.4172/2167-0897.1000242

**Copyright:** © 2016 Salameh KM, et al. This is an open-access article distributed under the terms of the Creative Commons Attribution License, which permits unrestricted use, distribution, and reproduction in any medium, provided the original author and source are credited.

**Data management and analysis plan**

An appropriate chi-square test was used to assess and examine an association between two or more qualitative variables. Pictorial presentation of key results was done using appropriate statistical graphs. P-value smaller than 0.05 was considered as statistically significant. All Statistical analyses were done using statistical packages SPSS 19.0. Data was presented as mean ± SD.

**Results**

Total number of infants collected retrospectively was 80, all infants are subjected to newborn metabolic errors screening, blood group test, G6PD test, vitamin K administration, as well as, polio, hepatitis B and BCG vaccinations. Only one patient was found having inborn error of metabolism (propionic aciduria). Our study included only 64 patients with isolated minor ear anomalies who have prenatal and postnatal ultrasound and 16 patients were excluded (14 patients with no recorded data regarding the prenatal ultrasound, one patient with associated imperforate anus and syndactyl and another patient with unilateral undescended testes) (Figure 1). Out of the 64 patients, only one patient had unilateral pyelactasis in prenatal ultrasound and in

postnatal ultrasound Follow-up it was normal, otherwise all prenatal renal ultrasound findings were the same in postnatal renal ultrasound findings.

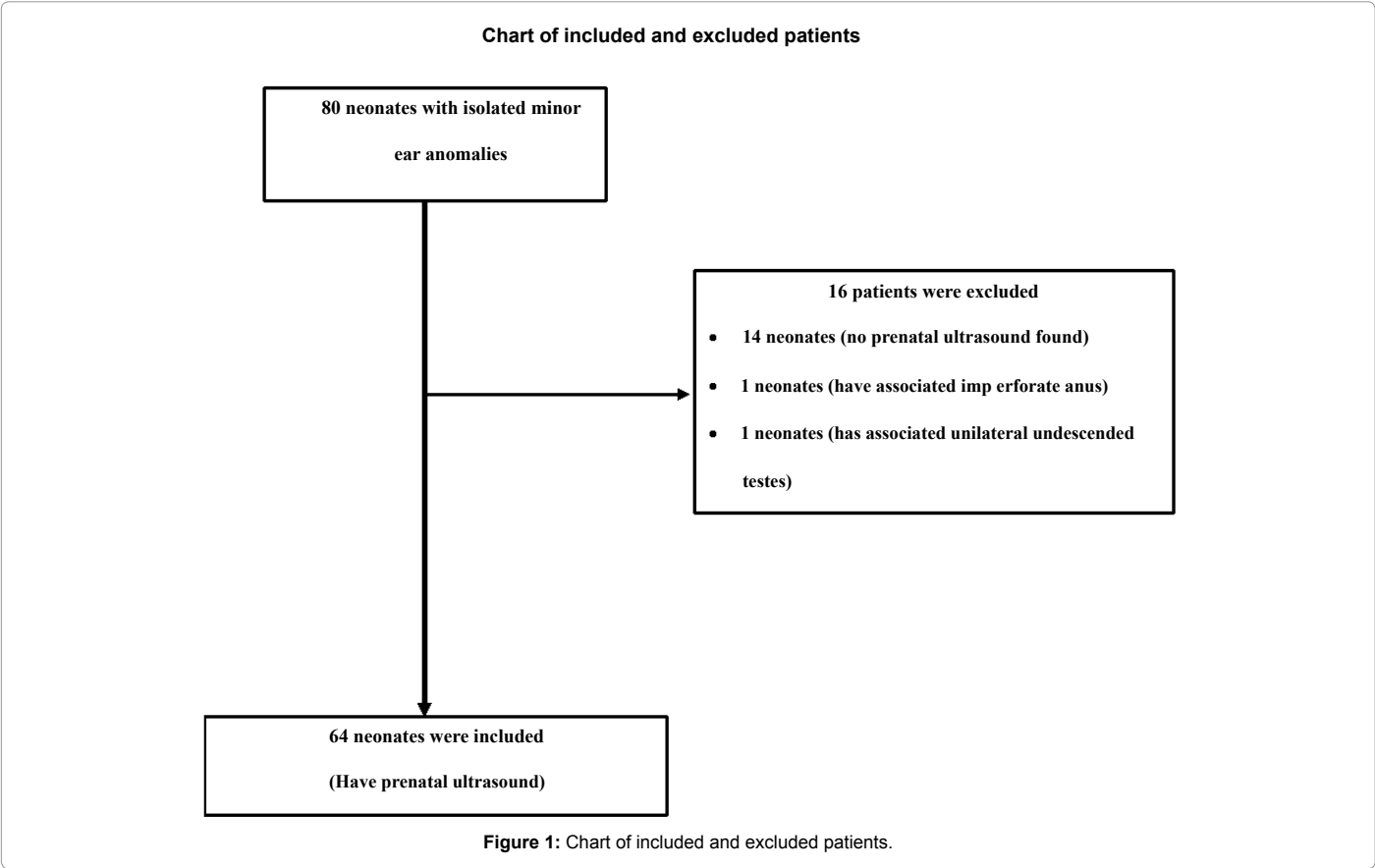
The prevalence of renal anomalies among infants with isolated minor ear anomalies was not different from that found on routine prenatal screening. Table of results is included in Tables 1 and 2.

**Discussion**

In our study, we compared the detection of renal anomalies among infants with isolated minor ear anomalies with that found on routine prenatal screening. And our results demonstrated that only one patient out of 64 (1.5%) had pyelactasis which resolved on postnatal ultrasound.

These results revealed that there is no difference in the detection of renal anomalies between postnatal renal ultrasound in neonates with isolated minor ear anomalies compared with that found on routine prenatal ultrasound. Moreover, there was no renal anomalies found associated with those infants.

In reviewing the literature we found that, the association between



Renal Abnormalities	Neonates with minor ear anomalies	
	Pre-natal Renal US (63)	Post-natal Renal US (63)
Unilateral or bilateral renal agenesis, hypoplasia	0	0
Crossed ectopia, horseshoe, pelvic or cystic kidney	0	0
Abnormalities involving Renal cortex thickness and echogenicity	0	0
Dilatation of pelvicalceal system	Pyelactasis: 1 Hydronephrosis: 0	0

**Table 2:** Table of results.

isolated minor external ear malformations and renal anomalies was not sufficiently investigated. Also the prevalence of renal anomalies reported in different studies was controversial, causing confusion over which specific ear anomalies do or do not require imaging [3]. A recent metanalysis study done supported that infants with isolated pre-auricular tags or sinuses don't require routine renal tract ultrasonography [3].

The embryonic development of the ears and kidneys occurs at different ages and at different rates. Any association between the abnormalities of these two organs is therefore unlikely due to a single insult but rather represents the effects of a common gene or a prolonged toxic insult hence there is increased frequency of clinically significant renal anomalies in association with ear malformations when that latter are a constituent of multiple congenital anomalies syndromes such as CHARGE association, Branchio-oto-renal (BOR) syndrome, Townes-Brocks syndrome, or in diabetic embryopathy [1,5].

## Conclusion

The results of our study concluded that routine postnatal ultrasound surveillance for neonates with isolated minor ear abnormalities is not warranted if those infants have a normal prenatal ultrasound, and in collaboration with the pediatric clinicians, the presence of a pre-auricular tag or pit should lead to a careful search for other malformations or dysmorphic features, the presence of which will tilt the balance in favor of doing a renal ultrasound [6-13].

Our study has clinical implication on enhancing the need for optimum utilization of the resources and helps avoid unnecessary repetition of ultrasound scans. Prenatal ultrasound is very helpful in detecting renal anomalies of the fetus; therefore further repetition of postnatal renal ultrasound is not needed in infants with isolated minor ear anomalies once they have a normal prenatal renal ultrasound [14-18].

We recommend a prospective study with larger sample size to clearly identify the association of isolated minor ear anomalies and renal anomalies.

## References

- Deshpande SA, Watson H (2006) Renal ultrasonography not required in babies with isolated minor ear anomalies. *Arch Dis Child Fetal Neonatal Ed* 91: F29-30.
- Kugelman A, Tubi A, Bader D, Chemo M, Dabbah H (2002) Pre-auricular tags and pits in the newborn: the role of renal ultrasonography. *J Pediatr* 141: 388-391.
- Cuestas E, Bur C, Bongiovanni V (2006) Mild external ear malformations and renal tract abnormalities: a meta-analysis. *Rev Fac Cien Med Univ Nac Cordoba* 63: 46-52.
- Kohelet D, Arbel E (2000) A prospective search for urinary tract abnormalities in infants with isolated preauricular tags. *Pediatrics* 105: E61.
- Wang RY, Earl DL, Ruder RO, Graham JM Jr (2001) Syndromic ear anomalies and renal ultrasounds. *Pediatrics* 108: E32.
- Torban E, Goodyer P (2009) The kidney and ear: emerging parallel functions. *Annu Rev Med* 60: 339-353.
- Yılmaz AE, Sarıfakıoğlu E, Aydemir S, Taş T, Orün E, et al. (2011) Preauricular sinus, nephrolithiasis, infantine eczema and natal tooth: A new association. *Eur J Dermatol* 21: 234-237.
- Arora RS, Pryce R (2004) Is ultrasonography required to rule out renal malformations in babies with isolated preauricular tags? *Arch Dis Child* 89: 492-493.
- Grapin C, Auber F, de Vries P, Audry G, Helardot P (2003) Postnatal management of urinary tract anomalies after antenatal diagnosis. *J Gynecol Obstet Biol Reprod (Paris)* 32: 300-313.
- Hilson D (1957) Malformation of ears as sign of malformation of genito-urinary tract. *Br Med J* 2: 785-789.
- Taylor WC (1965) Deformity of ears and kidneys. *Can Med Assoc J* 93: 107-110.
- Wiesel A, Queisser-Luft A, Clementi M, Bianca S, Stoll C (2005) Prenatal detection of congenital renal malformations by fetal ultrasonographic examination: an analysis of 709,030 births in 12 European countries. *Eur J Med Genet* 48: 131-144.
- Leung AK, Robson WL (1992) Association of preauricular sinuses and renal anomalies. *Urology* 40: 259-261.
- Tan T, Constantinides H, Mitchell TE (2005) The preauricular sinus: A review of its aetiology, clinical presentation and management. *Int J Pediatr Otorhinolaryngol* 69: 1469-1474.
- Markov D, Chernev T, Dimitrova V, Mazneikova V, Leroy Y, et al. (2004) Ultrasound screening and diagnosis of fetal structural abnormalities between 11-14 gestational weeks. *Akush Ginekol (Sofia)* 43: 3-10.
- Mishra D, Archana, Gupta VK (2003) Are isolated preauricular tags a marker of urinary tract anomalies. *Indian Pediatr* 40: 796-797.
- Lizama M, Cavagnaro F, Arau R, Navarrete O, Fontanaz AM, et al. (2007) Association of isolated preauricular tags and nephrourological anomalies: case-control study. *Pediatr Nephrol* 22: 658-660.
- Firat Y, Sireci S, Yakinci C, Akarçay M, Karakaş HM, et al. (2008) Isolated preauricular pits and tags: is it necessary to investigate renal abnormalities and hearing impairment? *Eur Arch Otorhinolaryngol* 265: 1057-1060.