

A Case Report of a Chinese Familial Partial Lipodystrophic Patient with *Lamin A/C* Gene R482Q Mutation and Polycystic Ovary Syndrome

Benli Su^{1*}, Nan Liu¹, Jia Liu², Wei Sun¹, Xia Zhang¹ and Ping Zhang¹

¹Department of Endocrinology and Metabolism, The Second Hospital of Dalian Medical University, Dalian 116027, China

²Department of Endocrinology and Metabolism, Dalian Fifth Hospital, Dalian 116023, China

Abstract

Individuals with Familial partial lipodystrophy (FPLD), Dunnigan variety is a rare autosomal dominant disorder caused by missense mutations in Lamin gene are predisposed to insulin resistance and its complications including features of polycystic ovarian syndrome. We present a single case report about a 26-year-old Chinese woman consulted for infertility. On physical examination acanthosis nigricans and central distribution of fat were found. Her masculine type morphology, muscular appearance of the limbs and excess fat deposits in the face and neck promote us to suspect the existence of partial lipodystrophy. Biochemistry testing confirmed glucose intolerance associated with a severe insulin resistance, hypertriglyceridemia, and polycystic ovary syndrome. The detection of a heterozygous missense mutation in *LAMIN A/C* gene at position 482 confirmed the diagnosis of FPLD2. In conclusion, characteristic features of FPLD and mutation screening allow early diagnosis of this disorder, and facilitate appropriate clinical treatment.

Keywords: Familial partial lipodystrophy; Lamin; Polycystic ovary syndrome; Metabolism

Introduction

Familial partial lipodystrophy (FPLD) is characterized by adipose tissue repartitioning with multiple metabolic disturbances, including insulin resistance and dyslipidemia [1]. Classical FPLD results from mutations in *LMNA* encoding nuclear lamin A/C (FPLD2), and recently some families with partial lipodystrophy and normal *LMNA* sequence are found to have germline mutations in *PPARG* (FPLD3) [2]. FPLD2 also known as Dunnigan-Kobberling syndrome, about 1 in 200 000, is a rare autosomal dominant disorder, characterized by partial or generalized loss of adipose tissue deposits. The hallmark is a regressive loss of subcutaneous fat from the trunk and extremities, and accumulation of subcutaneous fat in the face and neck. Because of the gradual loss of subcutaneous adipose tissue within arms and legs, these limbs appear to be unusually muscular, and the redistribution of adipose tissue is most apparent following puberty. The disease is also characterized by a constellation of metabolic complications, including insulin resistance, glucose intolerance, type 2 diabetes, dyslipidemia, and hepatic steatosis [3-5]. Clinical phenotypes are more pronounced in women, who exhibit higher frequencies of diabetes and atherosclerotic heart disease, and they may also develop hirsutism, acanthosis nigricans and menstrual abnormalities [6].

The most frequent FPLD2-linked *LMNA* mutation, present in about 90% of patients, substitutes a basic aminoacid at position 482 (arginine) for a neutral one (tryptophane, glutamine, leucine), R482Q mutation [7]. It is caused by heterozygous missense mutations in the lamin A/C (*LMNA*) gene, but the molecular basis of fat loss due to *LMNA* mutations is not clear.

We describe a case of a 26-year-old Chinese woman with severe hyperandrogenemia who had clinical, hormonal, and morphological ovarian features of Polycystic ovary syndrome (PCOS), acanthosis nigricans, infertility and profound insulin resistance, and was subsequently diagnosed to have FPLD.

Case Report

A 26-year-old Chinese woman was referred to our department with oligomenorrhea, hyperandrogenemia and infertility. Since the ages of 18, she had irregular spotting every 2 or 3 months on average,

but not spontaneous regular menses, and she received combined cyproterone acetate treatment that induced cyclical withdrawal bleeding, but oligomenorrhea recurred after interruption of the treatment. The hormone test showed high level of the testosterone and ultrasonographic findings included an ovarian cyst on the right side. The patient also described a 3-year history of progressively worsening acanthosis nigricans on the neck and axilla. The irregular, anovulatory cycles, together with acanthosis nigricans had resulted in the patient previously receiving a diagnosis of PCOS. In addition to these complaints, the patient was also concerned about her insulin

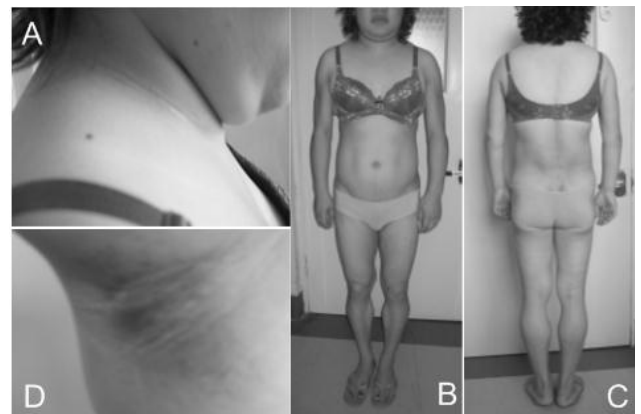


Figure 1: Phenotypic features of the patient. Note the prominent lower limbs musculature as well as the preservation of abdominal and cervical fat with loss of lower limbs and gluteal fat deposits (A-C) and acanthosis nigricans (D).

***Corresponding author:** Benli Su, Department of Endocrinology and metabolism, The Second Hospital of Dalian Medical University, Dalian 116027, China, Tel: 86-411-84671291-122; E-mail: benlisu_dalian@163.com

Received: February 04, 2017; **Accepted:** February 15, 2017; **Published:** February 21, 2017

Citation: Su B, Liu N, Liu J, Sun W, Zhang X, et al. (2017) A Case Report of a Chinese Familial Partial Lipodystrophic Patient with *Lamin A/C* Gene R482Q Mutation and Polycystic Ovary Syndrome. *Diabetes Case Rep* 1: 117.

Copyright: © 2017 Su B, et al. This is an open-access article distributed under the terms of the Creative Commons Attribution License, which permits unrestricted use, distribution, and reproduction in any medium, provided the original author and source are credited.

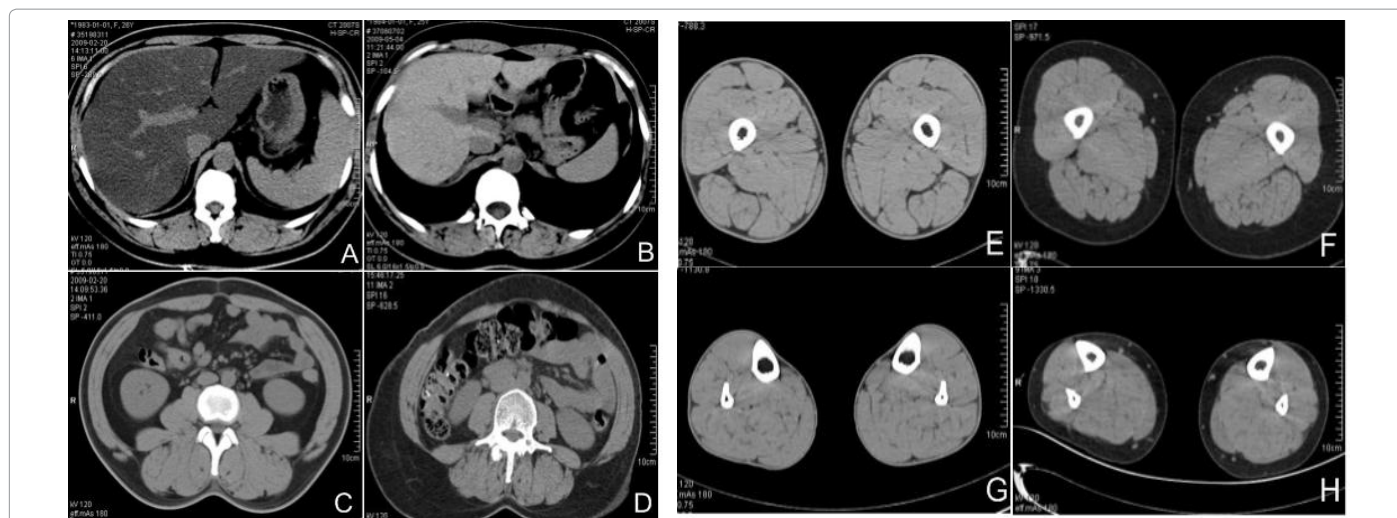


Figure 2: Cross-sectional computed tomography at the level of the Abdominal, L4 vertebra, the thigh and calf in the patient (A, C, E, G), and a woman with similar BMI (B, D, F, H). In the patient, the hepatic steatosis, nearly complete absence of subcutaneous fat, and the preservation of subcutaneous fat in the abdomen region were noted.

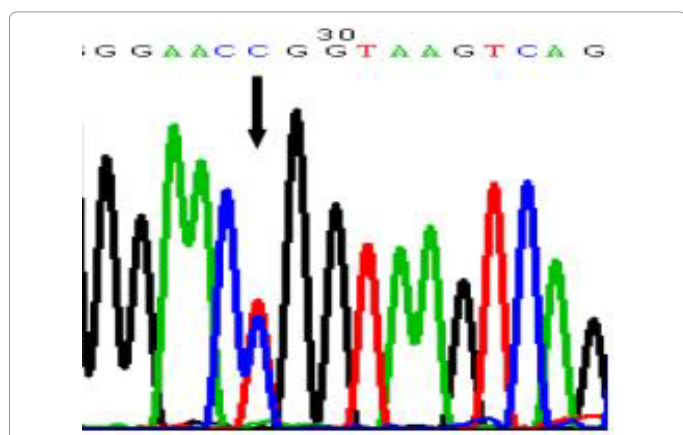


Figure 3: DNA sequence analysis of *LMNA*, showing a heterozygous G to A transition at position 1445 (exon 8) in the patient, predicting a R482Q substitution.

thigh and calf revealed nearly complete absence of subcutaneous fat and the abdominal CT revealed preservation of subcutaneous fat in the abdominal regions. Evidence of extensive acanthosis nigricans was observed in the axilla (Figure 3), neck, and back. Pubertal development had been normal with spontaneous menstruations at age 18, but she complained of menstrual irregularities since puberty associated with central obesity. Ultrasonographic findings included a normal-appearing uterus and enlarged the right ovary (5.8 cm × 3.9 cm), with an ovarian cyst about 3.7 cm × 2.7 cm.

Biochemical data were showed in Table 1 with 3-6-fold elevation of serum alanine aminotransferase and aspartate aminotransferase (290 and 133 U/L, respectively), the abdominal ultrasonography and CT scanning were performed and showed hepatic steatosis. She also had hypertriglyceridemia (2.91 mmol/L), hypercholesterolemia (6.93 mmol/l) and high level of low density lipoprotein cholesterol (5.11 mmol/L), but low levels of high density lipoprotein cholesterol (0.99 mmol/L).

A 75g oral glucose tolerance test (OGTT) was performed after a 12-h overnight fast to determine plasma glucose and insulin (measured with immunoradiometric assay) levels (Table 2). At baseline, blood glucose (BG) was 4.43 mmol/L and insulin (Ins) 31.78 uIU/mL; at 120 min, BG was 9.8 mmol/L and Ins 181.4 uIU/mL. The patient was therefore markedly insulin resistant and had altered glucose tolerance. Tests for circulating insulin receptor autoantibodies were negative.

Hormone tests (Table 3) showed increased total serum testosterone of 3.85 nmol/L (reference 0.22~2.9 nmol/L), but normal levels of circadian rhythms of serum cortisol, prolactin, progesterin and estradiol. Follicle stimulating hormone levels were normal, luteinizing hormone basal levels were slightly elevated, but the ratio of luteinizing hormone

Metabolic variables	Patient	Reference range
Alanine aminotransferase (U/L)	290	0.0~40.0
Aspartate aminotransferase (U/L)	133	0.0~40.0
GGT(U/L)	174	8.0~58.0
LDH(U/L)	228	135.0~226.0
Serum cholesterol (mmol/L)	6.93	2.8~5.2
Serum triglycerides (mmol/L)	2.91	0.22~2.29
Serum HDL cholesterol (mmol/L)	0.99	0.8~3.26
Serum LDL cholesterol (mmol/L)	5.11	~3.12

All samples were obtained after a 12-overnight fast.

Table 1: Biochemical data of the patient.

resistance. Treatment with pioglitazone 15 mg per day was added resulted in progressive amelioration of insulin resistance. She was infertility without any contraception after married one year ago.

Her height was 166 cm, weight 73 kg (BMI 26.49 kg/m²), Physical examination revealed a round face with double chin, neck bump, and the loss of subcutaneous fat from the extremities leading to prominence of muscular contours and veins, giving her a Cushing appearance (Figures 1A and B). As shown in Figures 2A-2H, the CT scan of the

	Time(min)				
	0	30	60	120	180
Plasma glucose (mmol/L)	4.43	6.87	7.49	7.08	6.8
Plasma insulin (uIU/mL)	31.8	162.7	160	181.4	150
Plasma C-peptide (ng/ml)	4.02	10.32	11.2	12.2	11.06

Table 2: Plasma glucose, insulin levels and C-peptide before and 30, 60, 120 and 180 minutes after an oral 75-g glucose load.

	Patient	Reference range
Cortisol (8:00) nmol/ml	412.8	165~441
Cortisol (16:00) nmol/ml	216.3	55~248
Cortisol (0:00) nmol/ml	32.39	55~138
prolactin uIU/ml	248.6	127~637
Estradiol(ng/L)	66.28	12.5~166
progesterin nmol/L	1.94	0.6~4.7
Luteinizing hormone mIU/ml	11.2	2.4~12.6
FSH mIU/ml	5.22	3.5~12.5
testosterone (nmol/L)	3.85	0.22~2.9

Table 3: Hormone tests from the patient.

to follicle stimulating hormone was elevated (LH/FSH>1). Magnetic resonance imaging (MRI) of the pituitary and CT scanning of the adrenal glands showed no abnormalities.

Sequencing of the *LMNA* gene revealed a heterozygous missense mutation (c. 1444C>T) leading to substitution of arginine by glutamine at position 482 (R482Q) located in exon 8, confirming the diagnosis of FPLD2 (Figure 3).

Results and Discussion

In this article, the patient we have described was about a Chinese woman with the PCOS, a selective loss of adipose tissue and insulin resistance occurred in the context of familial partial lipodystrophy due to a heterozygous R482Q missense mutation in *LMNA* gene. Her clinical history, hormonal test results, and ovarian morphology established the diagnosis of PCOS. She had normal fat distribution during childhood, but following puberty, demonstrate progressive loss of adipose tissue from the extremities, and often, excess fat deposition in the face, neck, and intra-abdominal regions. Combination of the fat loss and skeletal muscle hypertrophy gave the patient a rather athletic appearance. Subsequently, she was to be found anovulatory infertility, severely insulin resistant, hyperlipidemia and hepatic steatosis.

Recent data suggest that PCOS is indeed common among FPLD-affected women. Vantyghem [8] demonstrated that *LMNA*-mutated lipodystrophic women: prevalence of PCOS was more than 50%, infertility close to 30%, miscarriages reached 50%, gestational diabetes at least 30%, and preeclampsia and fetal death above 10%. These were all higher than those found in the general population. Tisha et al. [9] found that women with genetically confirmed FPLD have an increased risk for PCOS and ovarian cysts, as well as early hysterectomies, in comparison with the normal women. It has been reported that both PCOS-affected and FPLD-affected patients demonstrate increased visceral adipose tissue, which is strongly related to insulin resistance such as diabetes mellitus, hyperlipidemia and hepatic steatosis. Therefore, for the gynecologist and the endocrinologist, more detailed studies on the risk factors for PCOS in FPLD cohorts are likely to shed much information on the relationship between fat deposition, hyperandrogenemia, and insulin resistance. It is important to consider the diagnosis of FPLD in lean, muscular women who have polycystic ovarian syndrome and metabolic complications.

FPLD2 is an autosomal-dominant disease caused by mutations in the *LMNA* gene encoding the nuclear proteins lamin A and C [10]. The precise pathophysiology of FPLD2 is currently still unknown, but it could involve an altered interaction between mutated type A lamins and the adipogenic transcription factor sterol-regulatory element-binding protein 1 (SREBP-1). The defect, consisting in the intranuclear accumulation of mutant unprocessed precursors of lamin A, reduces the amount of the SREBP-1 and lowers the peroxisome proliferator-

activated receptor (PPAR γ) expression [11]. So logically, insulin sensitizers would be appropriate treatment and the thiazolidinediones, as agonists of PPAR γ , which stimulate pre-adipocytes, increase subcutaneous fat and reduce insulin resistance. But treatment with thiazolidinediones has only been indistinct. Addition of pioglitazone to metformin lead to specific positive effects on glucose control and normalized triglyceride levels after 3 months of treatment [12]. Treatment with pioglitazone resulted in progressive amelioration of insulin resistance, menses also improved, with restoration of a eumenorrhoeic pattern, and the framework of ultrasound PCOS was in complete remission [13]. Owen KR et al. [14] also reported no clear advantages in treating patients with FPLD caused by a mutation in the *LMNA* gene (R482Q) with rosiglitazone despite increases in subcutaneous adipose tissue. The effects of TZDs on glycemic control, body weight, and adiponectin thus appear to vary in patients with various forms of FPLD stimulate differentiation of pre-adipocytes and increase body fat. This is also supported by our case, in which insulin resistance and hyperinsulinaemia improved when therapy with pioglitazone was added, but discontinued due to deterioration of hepatic enzymes.

Several pathological alterations have been documented alteration of the prelamins A maturation pathway has been found in diseases such as Dunnigan-type familial partial lipodystrophy (FPLD) [15]. At the epigenetic level, patients with FPLD displayed less chromatin loading of heterochromatin protein 1 (HP1) as long as aberrant levels of heterochromatin associated histone modifications at lysine 9 and 27 on histone H3 [16]. As histone methyltransferases G9a and GLP function as the main writers for the establishment of H3K9/27me and HP1 is able to recognize and binds to H3K9me [17], abnormal expression of G9a and GLP might directly cause these alternations in patients. Interestingly, as G9a/GLP complex also plays a role in the maintenance of DNA methylation and this epigenetic modification per se is also able to suppress the gene expression [18,19], it is also worth investigate the levels of DNA methylation in patients with FPLD. Taken together, although genetic mutation of 1444C>T has been identified in patients with FPLD, alterations of epigenetic modifications might also play an essential role in the initiation and deterioration of this human disorder.

Conclusion

In conclusion, we have described the phenotype of a case with typical features of PCOS who was subsequently diagnosed to have FPLD. Our results indicated that careful assessment of the clinical features of FPLD should be considered in non-obese patients with PCOS and marked insulin resistance. Subjects with FPLD require individualized treatment in view of their adverse metabolic profile and increased cardiovascular risk. To the author's knowledge this is the first report of FPLD case caused by *LMNA* (R482Q) mutation found in mainland China.

Acknowledgements

This study would not have been possible without the participation of the patients and healthy volunteers. The study was partly supported by the National Natural Science Foundation of China (No. 81300643).

Competing Interests

Nothing to declare.

References

- Garg A (2004) Acquired and inherited lipodystrophies. *N Engl J Med*. 350: 1220-1234.
- Herbst KL, Tannock LR, Deeb SS, Purnell JQ, Brunzell JD, et al. (2003) Type

- of familial partial lipodystrophy: An underrecognized syndrome. *Diabetes Care* 26: 1819-1824.
3. Garg A, Vinaitheerthan M, Weatherall PT, Bowcock AM (2001) Phenotypic heterogeneity in patients with familial partial lipodystrophy (Dunnigan variety) related to the site of missense mutations in lamin a/c gene. *J Clin Endocrinol Metab* 86: 59-65.
 4. Hegele RA (2005) Lessons from human mutations in PPAR gamma. *Int J Obes (Lond)*. 29: 31-35.
 5. Lüdtke A, Genschel J, Brabant G, Bauditz J, Taupitz M, et al. (2005) Hepatic steatosis in Dunnigan-type familial partial lipodystrophy. *Am J Gastroenterol*. 100: 2218-2224.
 6. Garg A (2000) Gender differences in the prevalence of metabolic complications in familial partial lipodystrophy (Dunnigan variety). *J Clin Endocrinol Metab*. 85: 1776-1782.
 7. Jacob KN, Garg A (2006) Laminopathies: Multisystem dystrophy syndromes. *Mol Genet Metab* 87: 289-302.
 8. Vantyghem MC, Vincent-Desplanques D, Defrance-Faivre F, Capeau J, Fermon C, et al. (2008) Fertility and obstetrical complications in women with *LMNA*-related familial partial lipodystrophy. *J Clin Endocrinol Metab* 93: 2223-2229.
 9. Joy TR, Hegele RA (2008) Prevalence of reproductive abnormalities among women with familial partial lipodystrophy. *Endocr Pract* 14: 1126-1132.
 10. Novelli G, Muchir A, Sangiuolo F, Helbling-Leclerc A, D'Apice MR, et al. (2002) Mandibuloacral dysplasia is caused by a mutation in *LMNA*-encoding lamin A/C. *Am J Hum Genet* 71: 426-431.
 11. Larsen TM, Toubro S, Astrup A (2003) PPARgamma agonists in the treatment of type II diabetes: is increased fatness commensurate with long-term efficacy? *Int J Obes Relat Metab Disord* 27: 147-161.
 12. Moreau F, Boullu-Sanchis S, Vigouroux C, Lucescu C, Lascols O, et al. (2007) Efficacy of pioglitazone in familial partial lipodystrophy of the Dunnigan type: a case report. *Diabetes Metab* 33: 385-389.
 13. Gambineri A, Semple RK, Forlani G, Genghini S, Grassi I, et al. (2008) Monogenic polycystic ovary syndrome due to a mutation in the lamin A/C gene is sensitive to thiazolidinediones but not to metformin. *Eur J Endocrinol*. 159: 347-353.
 14. Owen KR, Donohoe M, Ellard S, Hattersley AT (2003) Response to treatment with rosiglitazone in familial partial lipodystrophy due to a mutation in the *LMNA* gene. *Diabet Med* 20: 823-827.
 15. Capanni C, Mattioli E, Columbaro M, Lucarelli E, Parnaik VK, et al. (2005) Altered pre-lamin A processing is a common mechanism leading to lipodystrophy. *Hum Mol Genet* 14: 1489-1502.
 16. Maraldi NM, Lattanzi G (2007) Involvement of prelamin A in laminopathies. *Crit Rev Eukaryot Gene Expr* 17: 317-334.
 17. Shinkai Y, Tachibana M (2011) H3K9 methyltransferase G9a and the related molecule GLP. *Genes Dev* 25: 781-788.
 18. Zhang T, Termanis A, Özkan B, Bao XX, Culley J, et al. (2016) G9a/GLP complex maintains imprinted DNA methylation in embryonic stem cells. *Cell Rep*. 15: 77-85.
 19. Bird A (2002) DNA methylation patterns and epigenetic memory. *Genes Dev* 16: 6-21.