

A Case of Gout from Imperial Rome (1st-2nd Century AD)

Simona Minozzi^{1*}, Federica Bianchi¹, Walter Pantano², Paola Catalano², Davide Caramella³ and Gino Fornaciari¹

¹Division of Paleopathology, Department of Translational Research on New Technologies in Medicine and Surgery, University of Pisa, Pisa, Italy

²Service of Anthropology, Special Superintendence to Archaeological Heritage of Rome, Rome, Italy

³Division of Diagnostic and Interventional Radiology, Department of Translational Research on New Technologies in Medicine and Surgery, University of Pisa, Pisa, Italy

Abstract

The study of pathological alterations in ancient skeletal remains may contribute to the reconstruction of the history of diseases and health conditions of ancient populations. Therefore, in recent research palaeopathology provides an important point of view in bioarchaeology and medicine.

This work describes the bone alterations observed in the skeleton of an adult woman found during archaeological excavations in the greatest necropolis of the Imperial Age in Rome.

The skeletal remains showed some pathological anomalies and the most evident alterations consisted of multiple osteolytic lesions involving mainly the small bones of the feet, which presented round cavitations and scarce signs of bone repair. Differential diagnosis suggests that this individual was affected by gout, probably associated with hypothyroidism that determined her short stature.

Keywords: Palaeopathology; Gout; Hypothyroidism; Roman Imperial Age; Italy

Introduction

Skeletal remains showing pathological alterations were found during the archaeological excavations directed by the Archaeological Superintendence of Rome, in the Collatina necropolis, in the Eastern part of modern Rome. The necropolis is located along the Roman Collatina road, which was an important commercial route during the Roman Age. Over 2500 burials were recovered, alongside great monumental tombs, common graves and cinerary urns. The archaeological context of the necropolis was dated to Ist-IInd century AD, on the basis of the grave goods recovered [1] and the architectonic structures.

Description

The skeleton, which was complete, well preserved and in supine position, was found in a simple grave with no funerary equipment (Figure 1). It belonged to an adult woman (35-45 years old) characterized by small dimensions of the bones that appeared to be proportionately shortened. The measured stature (bregma-talus) in situ was 132 cm, whereas the stature calculated by regression formulae [2] from the length of the long bones was 145 cm. Therefore, her stature in life is likely to have had intermediary values of about 135-140 cm, because

the regression formulae tend to overestimate short statures [3], whereas the measurement obtained in situ might underestimate the real stature.

Many dento-alveolar diseases involved the upper and lower jaws: caries, alveolar resorption and an abscess with perforation of the maxillary sinus; agenesis of the upper lateral incisors was also observed.

The skeleton showed some degenerative alterations presumably due to biomechanical stress and age, such as spondyloarthritis, signs of vertebral compression, osteophytosis and osteoarthritic alterations. The first right costal bone shows small erosion penetrating in the subchondral bone. At X-ray the erosion appeared to be deep and with no sclerotic edges (Figure 2).

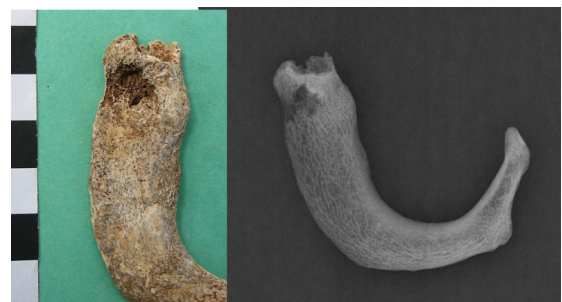

Figure 2: The first right costal bone showing small erosion penetrating in the subchondral bone (on the right) and X-ray (on the left)



Figure 1: Archaeological excavations: excavation site of the skeletal remains.

***Corresponding author:** Simona Minozzi, Divisione di Paleopatologia, Dipartimento di Ricerca Traslationale e delle Nuove Tecnologie in Medicina, Università di Pisa, Via Roma 57, 56126 Pisa, Italy, Tel: 0039-050-992894; Fax: 0039-050-992894; E-mail: simo.min@tiscali.it

Received August 19, 2013; **Accepted** October 21, 2013; **Published** October 27, 2013

Citation: Minozzi S, Bianchi F, Pantano W, Catalano P, Caramella D, et al. (2013) A Case of Gout from Imperial Rome (1st-2nd Century AD). J Clin Res Bioeth 4: 162. doi:10.4172/2155-9627.1000162

Copyright: © 2013 Minozzi S, et al. This is an open-access article distributed under the terms of the Creative Commons Attribution License, which permits unrestricted use, distribution, and reproduction in any medium, provided the original author and source are credited.

In the lower limbs, the knee joints were affected by degenerative alterations: the articular surface of the right femoral condyles was affected by a lytic lesion with erosion of the subchondral bone, diagnosed as osteochondritis dissecans, an osteochondral microfracture- caused by direct trauma or repetitive microtraumas- which is commonly the consequence of vigorous physical activities [4].

The articular surface of both tibiae showed signs of osteoarthritis. In both patellae, a proliferative subperiosteal new bone formation and erosive defects involved the anterior face. Radiographic examination showed that the erosions were deep and well-defined without sclerotic edges (Figure 3).

The feet were involved by the most evident alterations affecting with non-symmetrical features the small bones. The proximal epiphysis of both metatarsal bones showed many erosive lesions in the articular and periarticular surfaces, with well defined round cavitations and scarce signs of bone repair; the tarsal bones presented the same osteolytic lesions that partially destroyed the navicular, the cuboid and the three cuneiforms, in both feet (Figure 4 and 5). In the left big toe, the distal




Figure 3: Anterior face of patellae: proliferative subperiosteal new bone formation (on the top) and their radiological examination (on the bottom).

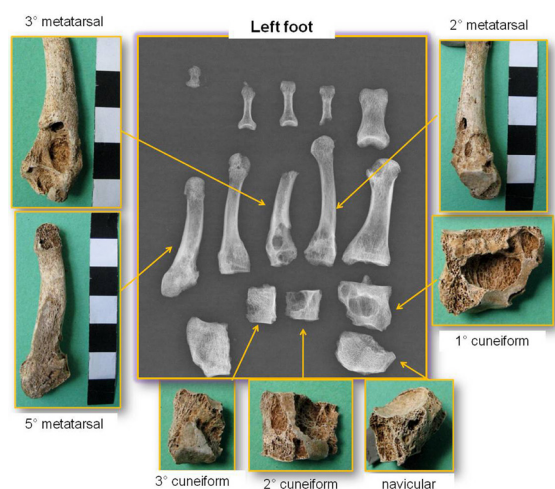


Figure 4: The left foot: erosive lesions in tarsal and metatarsal bones and radiological examination.

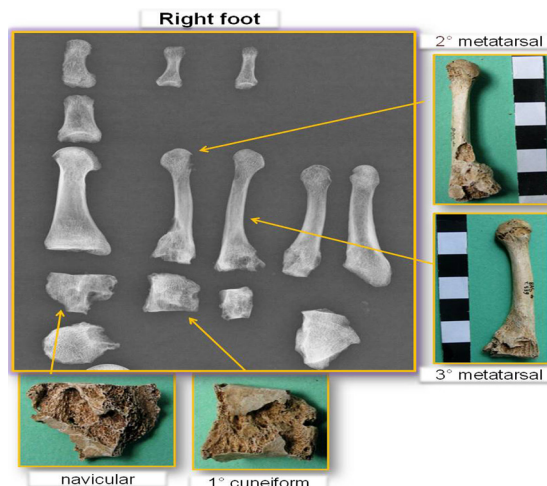


Figure 5: The right foot: erosive lesions in tarsal and metatarsal bones and radiological examination.

epiphysis of the first phalanges and the proximal epiphysis of the second phalanges were affected by similar erosions. The diaphyseal surface of the left fifth metatarsal also presented periosteal new bone apposition (28x7 mm). X-ray examination showed evident and widespread erosions, deeply penetrating and destroying the subchondral bone, sometimes with sclerotic edges (Figure 4 and 5).

Smaller and fewer erosive lesions were observed in both hands: in the 2nd interphalangeal joint of the 2nd and 4th right toes and in the distal epiphysis of the 1st and 2nd phalanges of the 3rd left toe.

Differential Diagnosis and Discussion

Differential diagnosis was performed taking into account the diseases that produce erosive lesions of bone. The osteolytic erosion observed in the bones is similar to the alterations caused by tumors, for example by multiple myeloma, a cancer of the plasma cells originating from hematopoietic marrow and also involving the skeletal apparatus [5]. Myeloma causes multiple rounded lesions of small size (inferior to 1 cm) which can be overlapped. As in this case, the lesions of multiple myelomas are purely erosive with clear edges having no sclerotic reaction, since the osteoblastic production is inhibited by malignant cells. Unlike this case, myeloma mainly affects the skull, coasts, spine and iliac bones which then spread to other skeletal districts, but it rarely involves the hands and feet [6,7].

Osteolytic lesions may also be due to metastatic cancer: bone metastases of soft tissue tumors, representing the most common cause of malignant neoplastic lesions of the skeletal apparatus. As in this case, cancer cells destroy the spongy and cortical bone with osteolytic lesions, but differently from the examined subject, erosions preferably affect the large bones that are richer in hematopoietic marrow: the axial skeleton, femur, and skull [4,6].

Enchondroma, a benign tumor of the hyaline cartilage, may cause osteolytic alterations: it partially destroys the spongy bone and can expand to the compact bone, often looking like a calcified or ossified nodule. It generally affects the metaphyses of the long bones, mostly in the phalanges of the hands (86%), then in the metacarpals, humeral diaphysis, phalanges of the feet, metatarsal bones, tibial, fibula, and ulnar [8,9]. Unlike this case, enchondromas are generally solitary lesions and the small bones of the hands and feet are almost always

misshapen, distorted and expanded and the articular surface is never affected. Moreover, it may occur at any age, but most commonly between 10 and 20 years of age [9-11].

Rheumatoid Arthritis (RA) is a chronic inflammatory disease of the synovial joints and connective tissue which can produce osteolytic lesions. Inflammation commences in the synovial membrane, then spreads and destroys the articular cartilage, resulting in erosion of the cortical bone, deformation of joints and, finally, joint ankylosis. Bone lesions consist of periarticular osteopenia, subchondral cysts and deformation of the articular surface. RA involves many joints and the earliest lesions occur symmetrically in the hands causing deformities, in particular in the metacarpal-phalangeal and interphalangeal joints. Other commonly affected districts are the feet, knees, elbows, wrists and shoulders [4,6].

Compatible alterations with the examined subject may also be due to gout, a metabolic disease characterized by hyperuricemia: the abnormal accumulation of uric acid in the blood that causes the precipitation of uric acid crystals either within or around a joint, inducing erosion of bone and cartilage and resulting in a destructive, chronic and disabling arthritis [4,12]. Gout often involves many joints and the most commonly affected sites are the foot, in particular the tarso-metatarsal and metatarso-phalangeal joints, ankle, knee, hand and wrist. The shoulder and sacroiliac joints are less commonly involved, and rarely the spine and hip [13]. Erosions mostly affect the articular surface, close to the margins of the joints, preserving the articular space, but extra-articular erosions, intraosseous calcifications, and subchondral collapse may be also present. Osteolytic lesions are usually multiple, but not symmetrical, and the inflammatory process may be associated with periosteal new bone formation at the edges of the lesion. X-ray examination shows well-defined erosions with sclerotic or overhanging margins [14,15].

Gout mainly affects men over forty years of age, more often than women, and may be associated with other diseases, such as hypothyroidism, renal disorders and obesity [16,17].

Gout is a metabolic disease characterized by the abnormal accumulation of uric acid in the body, which may be caused by increased production or decreased renal excretion. Uric acid accumulation in the blood causes the precipitation of sodium urate crystals that constitute nodules deposited into the soft tissue, known as tophi. These collections, penetrating in the deep bone tissue, cause erosion of bone and cartilage, mostly on the articular surface and close to the margins of the joints, resulting in a destructive, chronic and disabling arthritis, often involving many joints [18,19]. Erosive damage is a late feature of chronic gout, typically occurring 15 years after onset of the disease [20]. The etiology of gout is still unknown but seems to be associated with genetic and dietary factors (especially a diet rich in meat).

Conclusions

In our evaluation, the pathological and radiological evidence indicates gouty arthritis was the probable cause of the relevant skeletal signs. Rheumatoid arthritis is the erosive joint disease with more similar effects, but it can be discarded due to lesion asymmetry, periarticular osteopenia and ankylosis. Moreover the periarticular localization of erosions, or their situation some distance away from the joint, as observed in this case, is not present in rheumatoid arthritis. The erosive lesions observed suggest exclusion of the emergence of a metastatic carcinoma, which generally affects the bones rich in hematopoietic marrow and these signs were not observed in this case. For the same

reason multiple myeloma can be excluded, as this rarely affects hands and feet.

It is more difficult to assess and distinguish the bony alterations from gout and enchondromas, because they produce similar signs and have analogous localization. However, enchondromas produce deformation and distortion of the hand and feet bones. The articular surface is never affected, which is not the case for the individual in question, in whom the subchondral bone is destroyed, in the same way as in gout.

Some mycoses causing similar destructive frameworks, such as blastomycosis and histoplasmosis [9], can be excluded because they are typical of tropical environments and totally absent in Europe [21].

We presume that the studied remains are consistent with that of a woman who suffered from chronic gout. Moreover, this individual had a shorter than average stature (135-140 cm) for women in the same necropolis, which was 155 cm (n=48), and the difference of 15-20 cm could be due to a pathological condition. Gout may be associated with hypothyroidism (15-20% of gout patients also have hypothyroidism), an endocrine disorder due to a reduction of thyroid gland functioning [16,17]. The most common manifestation of hypothyroidism in children is reduced growth rate, often resulting in short stature. Therefore, concomitant hypothyroidism in this woman may have caused retarded growth and short stature.

We know little about the antiquity of gout and few cases are known from the past: three cases of Roman Age (150 AD) from Gloucester in England [22], an Egyptian mummy of Christian Age with gouty arthritis [23] and two skeletons from Greece (6th -7th century AD) described by Bourbou [19]. In more recent times, gout has afflicted many historical figures, like Ferdinando I of the Italian Renaissance family of the Medici [24] or the Roman Emperor Charles V of Spain [25]. Descriptions of pathological cases in ancient skeletal remains are useful to understand the origin and history of diseases and their development or changes in the time, and this is useful to better understand current illness and can help to predict future diseases.

References

1. Buccellato A, Catalano P, Arrighetti B, Caldarini C, Colonnelli G, et al. (2003) Il comprensorio della necropoli di Via Basiliano (Roma): un'indagine multidisciplinare. *Mélanges de l'Ecole Française de Rome* 115(1): 311-376.
2. Trotter M, Gleser GC (1958) A re-evaluation of estimation of stature based on measurements of stature taken during life and of long bones after death. *Am J Phys Anthropol* 16: 79-123.
3. Formicola V (1993) Stature reconstruction from long bones in ancient population samples: an approach to the problem of its reliability. *Am J Phys Anthropol* 90: 351-358.
4. Waldron T (2009) *Human Palaeopathology*. Cambridge University Press, Cambridge.
5. Roberts C, Manchester K (2005) *The Archaeology of Disease*. Cornell University Press Ithaca, New York.
6. Aufderheide A, Rodríguez-Martin C (1998) *The Cambridge Encyclopedia of Human Paleopathology*. Cambridge University Press.
7. Cotran RS, Kumar V, Robbins SL (1994) *Robbins Pathological Basis of disease*. 5th edition Saunders, Philadelphia.
8. Steinbock RT (1976) *Paleopathological diagnosis and interpretation*. Charles C. Thomas, Springfield.
9. Ortner DJ (2003) *Identification of Pathological condition in human skeletal remains*. Smithsonian Institution Press, New York.
10. Neal P, Simon MD, Michael W (2002) Multiple Enchondromatosis: Ollier's Disease. *International Pediatrics*.

11. Thillaud PL (1996) Paléopathologie Humaine (Human Paleopathology). Sceaux Cedex, Kronos.
12. Pascual E, Pedraz T (2004) Gout. *Curr Opin Rheumatol* 16: 282-286.
13. Perez-Ruiz F, Dalbeth N, Urrisola A, de Miguel E, Schlesinger N (2009) Imaging of gout: findings and utility. *Arthritis Res Ther* 11: 232.
14. Resnick D, Broderick TW (1981) Intraosseous calcifications in tophaceous gout. *AJR Am J Roentgenol* 137: 1157-1161.
15. Gentili A (2003) Advanced imaging of gout. *Semin Musculoskelet Radiol* 7: 165-174.
16. Erickson AR, Enzenauer RJ, Nordstrom DM, Merenich JA (1994) The prevalence of hypothyroidism in gout. *Am J Med* 97: 231-234.
17. Narasimha Pai D, Desai Rajeev, Dharmanand BG (2001). Rheumatological Manifestations in Hypothyroidism. *JK Science*, 3: 113-115.
18. Swinson D, Snaith J, Buckberry J, Brickley M (2010) High Performance Liquid Chromatography (HPLC) in the Investigation of Gout in Palaeopathology. *Int J Osteoarch* 20: 135-143.
19. Bourbon C (2003). Health Patterns of Proto-Byzantine Populations (6th-7th centuries AD) in South Greece: the Cases of Eleutherna (Crete) and Messene (Peloponnese). *Int J Osteoarch* 13: 303-313.
20. Nakayama DA, Barthelemy C, Carrera G, Lightfoot RW Jr, Wortmann RL (1984) Tophaceous gout: a clinical and radiographic assessment. *Arthritis Rheum* 27: 468-471.
21. Binford CH, Dooley JR (1976) Deep Mycoses. In: *Pathology of Tropical and Extraordinary Diseases*. Armed Forces Institute of Pathology, Washington DC.
22. Wells C (1982) The human burials. In: McWhirr A, Viner L, Wells C (Eds) *Romano-British cemeteries at Cirencester*. Alan Sutton Publishing, Gloucester; 135-207.
23. Eliot-Smith DG, Dawson WR (1924) Mummification in relation to medicine and pathology. In: *Egyptian Mummies*. Dial Press, New York; 157-158.
24. Fornaciari G, Giuffra V, Giusiani S, Fornaciari A, Villari N, et al. (2009) The 'gout' of the Medici, Grand Dukes of Florence: a palaeopathological study. *Rheumatology (Oxford)* 48: 375-377.
25. Ordi J, Alonso PL, de Zulueta J, Esteban J, Velasco M, et al. (2006) The severe gout of Holy Roman Emperor Charles V. *N Engl J Med* 355: 516-520.