

25th Global Dentists and Pediatric Dentistry Annual Meeting

April 25-26, 2019 | Rome, Italy

The root shield technique for buccal bone preservation at immediate implant placement in the esthetic zone

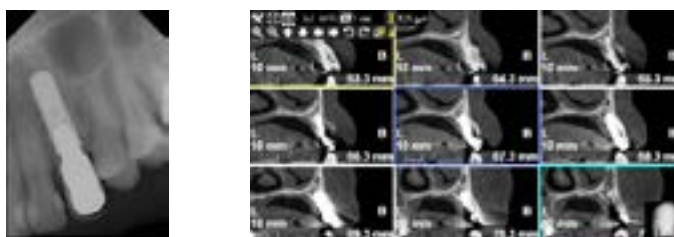
Arwa AlSayed

Riyadh Military Hospital, Saudi Arabia

After tooth extraction, the alveolar bone undergoes a remodeling process, which leads to horizontal and vertical bone loss. The resorption processes complicate dental rehabilitation, particularly in connection with implants placement. Various methods of guided bone regeneration (GBR) have been described to retain the original dimension of the bone after tooth extraction. Most procedures use filler materials and membranes to support the buccal plate and soft tissue, to stabilize the coagulum and to prevent epithelial ingrowth. It has been suggested that resorption of the buccal bone can be avoided by leaving a buccal root segment (Root-Shield Technique) in place, because the biological integrity of the buccal periodontium (bundle bone) remains untouched. This method has been described in connection with immediate implant placement in the treatment of missing teeth in the esthetic zone. This presentation describes clinical case in which the Root Shield technique was applied as part of immediate implant placement in the anterior upper canine area. It was demonstrated that the bone was clinically preserved with this technique for up to seven years follow up. Possibilities and limitations will be discussed and directions for future research will be disclosed.

Recent Publications

1. Gharpure A., et al. (2017): Current Evidence on the Socket-Shield Technique: A Systematic Review, Journal of Oral Implantology, XLIII (5): 395-403.
2. Pour RS., et al. (2017): Clinical Benefits of the Immediate Implant Socket Shield Technique, 29(2): 93-101.
3. Baumer D., et al. (2015): The Socket-Shield Technique: First histological, Clinical, and Volumetrical Observations after Separation of the Buccal Tooth Segment – A Pilot Study, 17(1): 71-82.
4. Mitsias ME., et al. (2015): A Step-by-Step Description of PDL-Mediated Ridge Preservation for Immediate Implant Rehabilitation in The Esthetic Region, 35(6):835-841.
5. Chu S., et al. (2014): A Novel Prosthetic Device and Method for Guided Tissue Preservation of Immediate Post-extraction Socket Implants, 34(9): s9-s17.



Figures: Radiographic images for the inserted implant and crown.

Biography

Arwa AlSayed is a consultant in Periodontics and implant dentistry. She was the chairman and the program director of the Saudi fellowship Program in Implant Dentistry for the last eight years. Also, she is the head of the assessment and exam committee for the Periodontology and the Implant postgraduate programs. She has experience with more than 50,000 implants placed with various procedures of bone and soft tissue augmentation.

difp_as@yahoo.com